

# A Rare Case of Adult Intussusception due to Inflammatory Fibroid Polyp of the Intestine

Dr. R. G. Naniwadekar<sup>1</sup>, Dr. Shruti C. Panicker<sup>2</sup>, Dr. Madhavedra Kabra<sup>3</sup>

<sup>1,2,3</sup>Krishna Institute of Medical Sciences, University Karad, Near Dhebewadi road, Pune Bangalore National Highway Malkapur, Karad  
Pin 415110, Maharashtra, India

**Abstract:** Introduction: There are several types of small bowel pathologies that can lead to small bowel obstruction or intussusception. The etiology causing small bowel obstruction varies by age. Benign disease is the typical cause in children and adolescents while malignant or adhesive disease is far more common in older patients. Although cases of adult intussusception caused by benign processes are rare, there are reports of inflammatory fibroid polyps causing adult intussusception of the terminal ileum published in the literature. Case history: We present a case of a 40 year old, male patient who came with the chief complaints of pain abdomen since 15-20 days, with 3-4 episodes of loose stools per day since 10 days. Patient also gives history of abdominal distension intermittently. Conclusion: Although inflammatory fibroid polyps are rare and benign, in a case of intestinal obstruction caused due to inflammatory fibroid polyp, the only solution is a surgical approach.

**Keywords:** intussusception, inflammatory fibroid polyp, intestinal obstruction, hemi-colectomy, claw sign.

## 1. Introduction

Intussusception is one of the rare and uncommon causes of intestinal obstruction in an adult<sup>[1]</sup>. Patients with intestinal obstruction due to intussusceptions present with chronic or acute signs of obstruction. Usually intermittent symptoms are present. Most of the patients with intussusception have a malignant etiology<sup>[2]</sup>. But the case we are presenting is an adult patient of intermittent intussusception with an inflammatory benign polyp. Hence the aim of our study is to emphasize that some rare etiologies may also be involved in cases of adult intestinal obstruction.

## 2. Case Presentation

A 40 year old male patient, came with the chief complaints of pain in abdomen since 15-20 day. Pain was associated with 3-4 episodes of loose stools per day since 10 days non-blood stained, non-mucoid. Pain is not associated with aggravating or relieving factors. Patient also gave history of intermittent abdominal distension. Patient gives history of irregular bowel movements. On admission patient was vitally stable with pulse rate 88bpm, Blood pressure 120/80 mm of Hg, respiratory rate of 16brpm. Abdomen was mildly distended with mild guarding. Barium enema was suggestive of 'claw sign' which is classical of intussusception. X-ray erect abdomen was suggestive of multiple air fluid levels. Ultrasonography was suggestive of a polyp arising from the terminal ileum measuring 5x4x3.5 cm with ileo-colo-colic intussusception, sub-acute obstruction with dilatation of proximal small bowel.

## 3. Management

An exploratory laparotomy was performed with the diagnosis of sub-acute intestinal obstruction. An intussusception with a mass lesion at its lead point approximately 10 cm proximal to the caecum was found. Intussusception was ileo-colo-colic reduced during exploration. Edema at the lead point of the bowel was present.(Figures 3 and 4). A right hemi-colectomy was

performed and the affected segments i.e. the ileum, caecum and the ascending colon were excised.

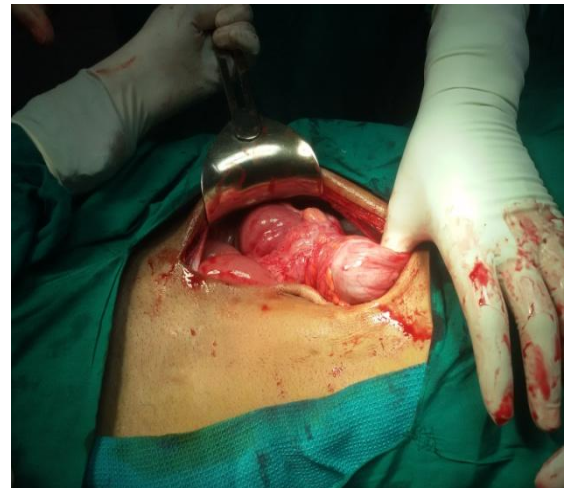

Figure 3

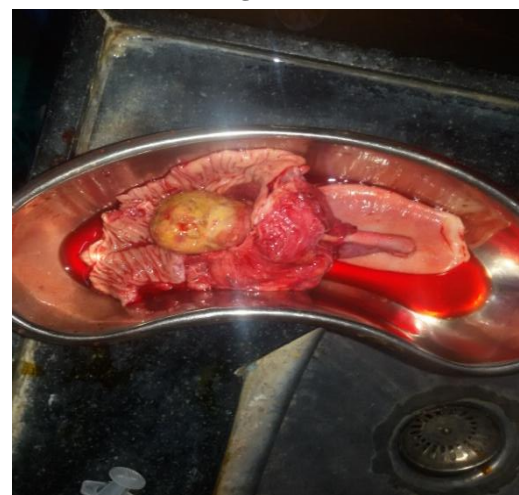

Figure 4

## 4. Histological Report

Inflammatory fibroid polyp arising from the mucosal surface measuring 5cmx4cmx3cm leading to intussusception.

Volume 4 Issue 10, October 2015

[www.ijsr.net](http://www.ijsr.net)

Licensed Under Creative Commons Attribution CC BY

Excised portion of terminal ileum, caecum and ascending colon.

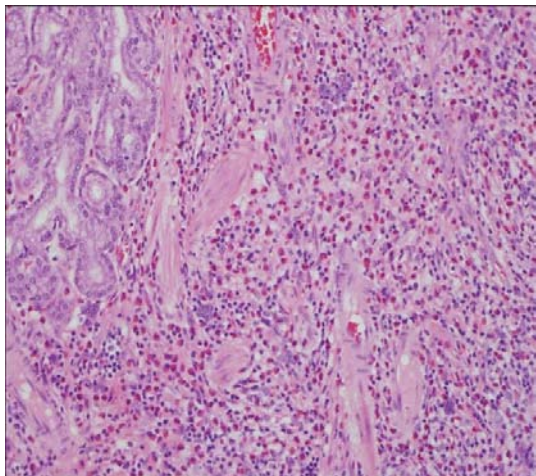


Figure 5

## 5. Discussion

Inflammatory fibroid polyps are rare benign tumors of the gastrointestinal tract with the most common site being the gastric antrum, followed by the ileum. Histogenesis is still unknown and considered controversial. Inflammatory fibroid polyps are one of the rare benign conditions leading to intestinal obstruction in adults. IFPs are among the least common benign lesions of the gastrointestinal tract. They originate from the submucosal layer as a solitary or sessile lesion with an inflammatory basis. They may occur throughout the intestinal tract but most commonly encountered in the gastric antrum and small bowel.<sup>[3]</sup> IFPs usually measure between 2 and 5 cm in diameter. However, there are also giant IFPs with a size of up to 12.5 cm in diameter having been reported.<sup>[4]</sup> IFP was first described by Vanek as a 'gastric submucosal granuloma with eosinophilic infiltration' in 1949.<sup>[5]</sup> Histologically, IFPs show the presence of vascular and fibroblast proliferation with an eosinophilic inflammatory response. The underlying cause of IFP remains unclear. Many factors have been suggested as a trigger such as intestinal trauma or eosinophilic gastroenteritis.

IFPs are usually asymptomatic, identified during endoscopy or laparotomy. When they are symptomatic the clinical presentation is determined by the anatomic location. Gastric IFPs may present with symptoms of pyloric obstruction or anemia with chronic bleeding<sup>[6]</sup> When they arise from the small bowel, intussusception is the most common clinical presentation.

Adult intussusception is a very rare cause of intestinal obstruction, accounting for 1% of all adult bowel obstruction and occurs in only 5% to 16% of all intussuscepted cases<sup>[7]</sup>. About 70% to 90% of intussusception cases are due to benign or malignant neoplasms as a lead point and IFPs, lipomas and adenomas are the benign causes of intussusception<sup>[7]</sup>. However, it has been documented that intussusception can occur without significant pathological cause<sup>[8]</sup>.

Unlike the more common idiopathic intussusception found in children, intussusception in adult patients still remains to be dealt with surgically. The type of surgical procedure depends on factors like the patient's medical history (previous operations, malignancy) and intra-operative findings<sup>[9]</sup>. The optimal surgical management of intussusception in adult patients is influenced by two major factors: the presence of distinct malignancy and the local factors such as the degree of associated edema, and relative ischemia of the involved bowel. A right hemi-colectomy was performed in our case as edema was extensive, observed at lead point of intussusception. However, attempts at local removal of polyps through a limited enterotomy, or by wedge resection through edematous bowel, may prove disastrous. Healthy bowel margins must be secure during segmental resection.

## 6. Conclusion

Intussusception is a very rare cause of adult intestinal obstruction and IFP is one of the least common causes of this rare condition. Although IFPs are benign lesions, surgical treatment is the only solution when they present with small bowel obstruction.

## 7. Consent

Written informed consent was obtained from the patient for publication of this case report and any accompanying images.

## References

- [1] Huang BY, Warshauer DM: Adult intussusception: diagnosis and clinical relevance. *Radiol Clin North Am* 2003, 41:1137–1151.
- [2] Eisen LK, Cunningham JD, Aufses AH Jr: Intussusception in adults: institutional review. *J Am Coll Surg* 1999, 188:390–395.
- [3] Wysocki AP, Taylor G, Windsor JA: Inflammatory fibroid polyps of the duodenum: a review of the literature. *Dig Surg* 2007, 24(3):162–168.
- [4] Harned RK, Buck JL, Shekitha KM: Inflammatory fibroid polyps of the gastrointestinal tract: Radiologic evaluation. *Radiology* 1992, 182:863–866.
- [5] Vanek J: Gastric submucosal granuloma with eosinophilic infiltration. *Am J Pathol* 1949, 25(3):397–411.
- [6] Gonul II, Erdem O, Ataoglu O: Inflammatory fibroid polyp of the ileum causing intussusception: a case report. *Turk J Gastroenterol* 2004, 15:59–62.
- [7] Karamercan A, Kurukahvecioglu O, Yilmaz TU, Aygencel G, Aytaç B, Sare M: Adult ileal intussusception: an unusual emergency condition. *Adv Ther* 2006, 23:163–168.
- [8] Lvoff N, Breiman RS, Coakley FV, Lu Y, Warren RS: Distinguishing features of self-limiting adult small-bowel intussusception identified at CT. *Radiology* 2003, 227:68–72.
- [9] Yalamarthi S, Smith RC: Adult intussusception: case reports and review of literature. *Postgrad Med J* 2005, 81(953):174–177.

## Author Profile



**Dr. R.G. Naniwadekar** has received MBBS degree from B.J Medical college pune in 1979. MS from B.J medical College pune in 1987. Currently he is working as Associate Professor in Gen. Surgery department at Krishna Hospital Karad. He has presented research paper in national journal.



**Dr. Shruti Panicker** has received MBBS degree from V.I.M.S and R.C college in 2010. Since May 2013 she is postgraduate student in Gen. Surgery department at Krishna Hospital Karad. She has presented research paper in national journal



**Dr. Madhavendra Kabra** has received MBBS degree from Topiwala National Medical college, Mumbai in 2011. Since May 2013 he is a postgraduate student in G. Surgery department at Krishna Hospital Karad. He has presented research paper in national journal.