

33-Year-Old Male with Intra Abdominal Lump

Dr. Akshay Agarwal¹, Dr. Shilpi Sahu², Dr. Reeta Dhar³

Department of Pathology, MGM Medical College, Navi Mumbai

Abstract: *Extraskeletal Ewing's sarcoma (EES) / Primitive neuroectodermal tumors (PNET) are an uncommon, highly aggressive small blue round cell tumor that primarily affects children and young adults. EES commonly affects the bones of the extremities although many have reported unusual primary sites such as intracranial[1], breast[2], larynx[3], pulmonary[4], retroperitoneum [5] and small bowel mesentery[5]. To our knowledge, after extensive search, only one case have been reported of EES in the mesocolon of an adult [6]. We report a 2nd case of EES affecting the mesocolon in an adult.*

Keywords: Extraskeletal Ewing's Sarcoma, PNET, Small Blue Round Cell Tumor, Mesocolon

1. Case Report

A 33 year old male presented to our Surgery outpatient clinic with complaints of sudden onset, mild to moderate abdominal pain and constipation since 2 months and loss of appetite since one month. He had no history of blood in stools, family history of any malignancy and any similar complaints in the family. On physical examination, the patient was afebrile and was mildly cachexic. Abdominal examination revealed a mass located near the umbilicus in the left lumbar and left iliac region. Ultrasound revealed a 10.5x8.3x7.4 cm mixed echoic mass. CT showed a well circumscribed, slightly lobulated heterogeneous solid mass lesion in the left iliac fossa with epicenter in mesentery. It measured 11.5x8.8x9.2 cm. the lesion was slightly hyper-

dense and revealed a heterogeneous post-contrast enhancement. Surgery was performed to excise the tumor. We received a specimen of large intestine measuring 15cm with attached well circumscribedcystic, grey-brown tumor in the mesentery measuring 9x5x3cm[figure 1]. Multiple sections studied for histopathology showed monotonous small blue round tumor cells with large confluent areas of hemorrhage [figure 2]. The tumor cells were negative for CD45[figure 3], Desmin[figure 4] and showed strong cytoplasmic membranous positivity for CD99[figure 5]. Thorough search for the primary in the bone did not reveal any lesion. Thus a diagnosis of Exterskeletal Ewing's Sarcoma was confirmed. The patient is asymptomatic after 6 months of follow-up.

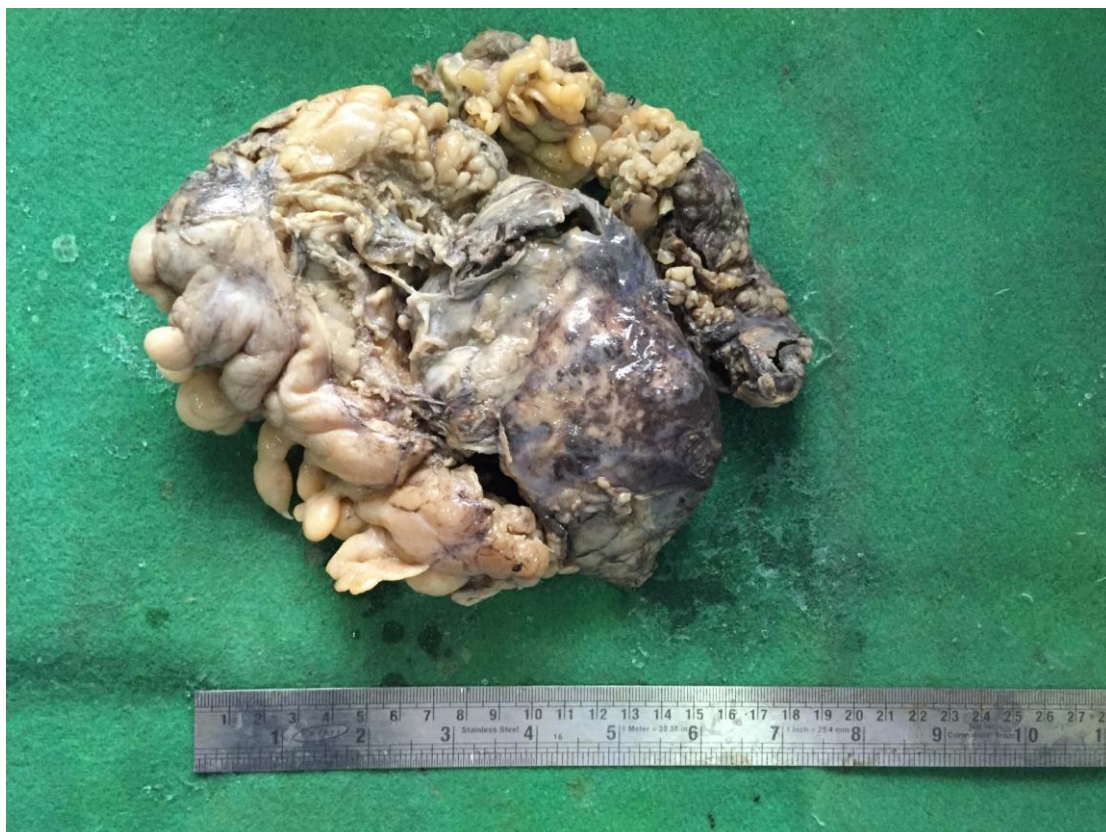

Figure 1: Gross photograph of tumor located in the mesentery

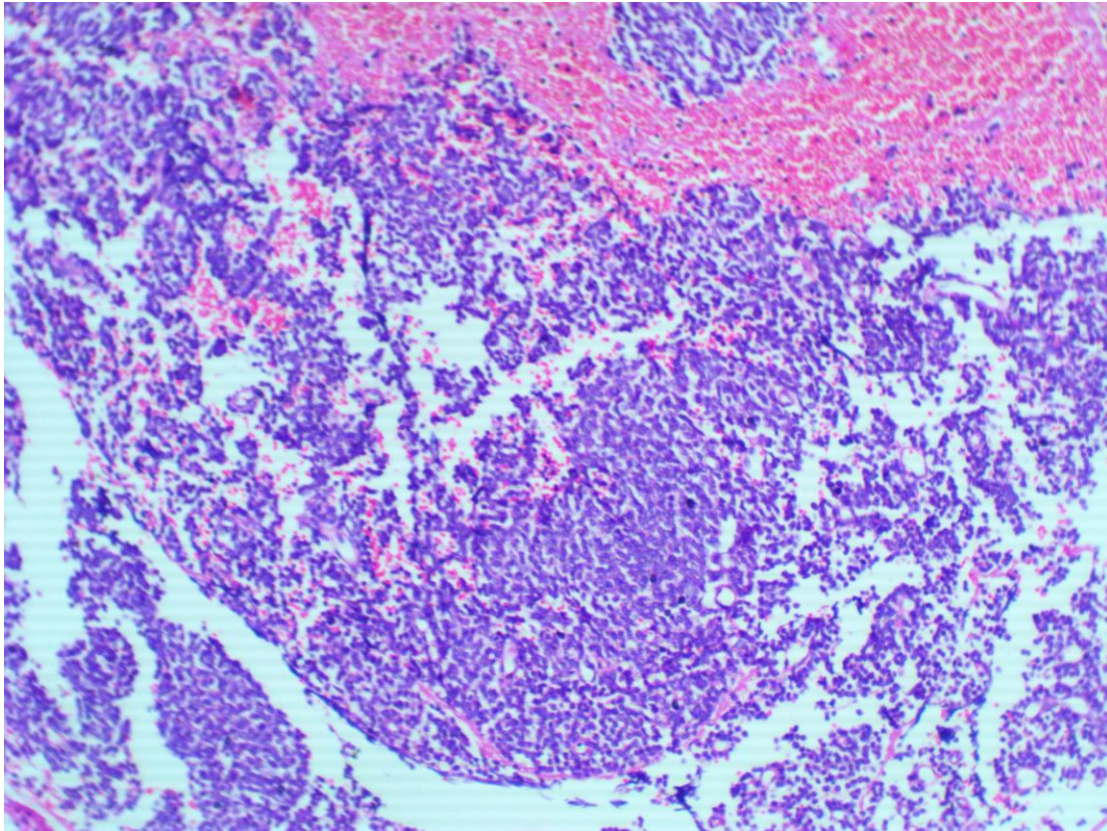


Figure 2: Small blue round cell tumor with areas of haemorrhage [H & E stain, 100x]

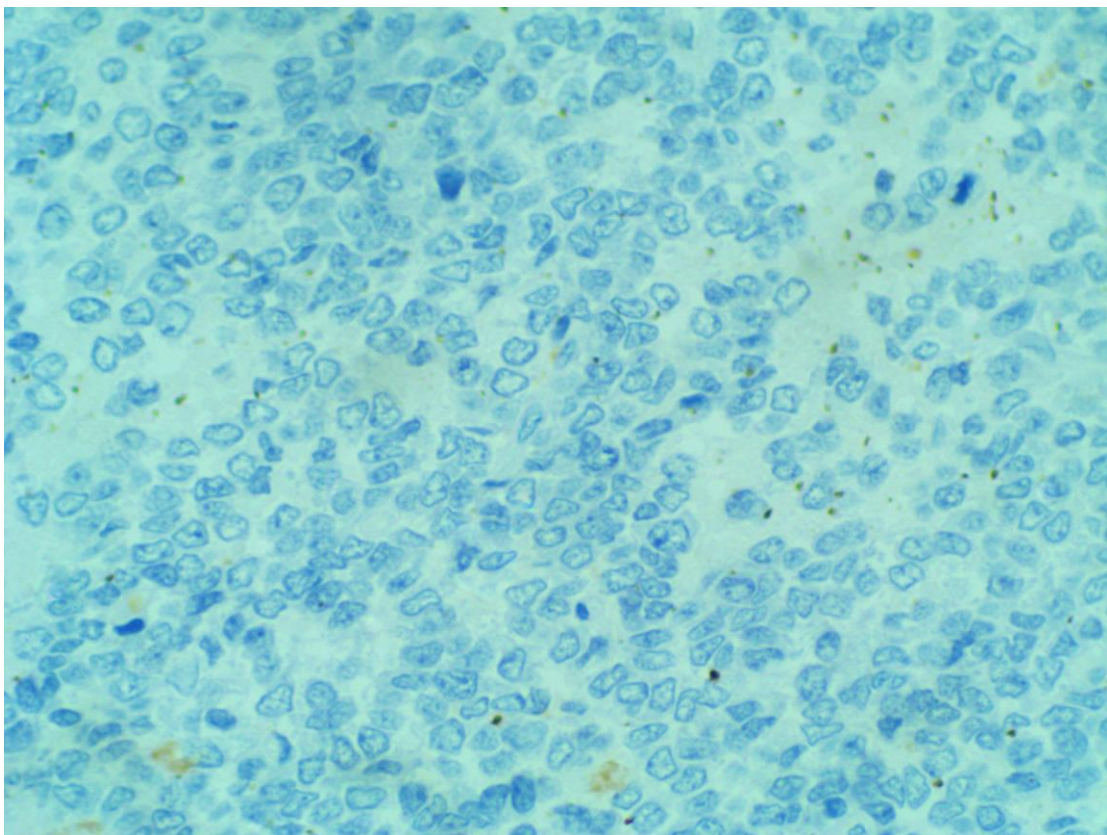


Figure 3: CD45 stain [400x]

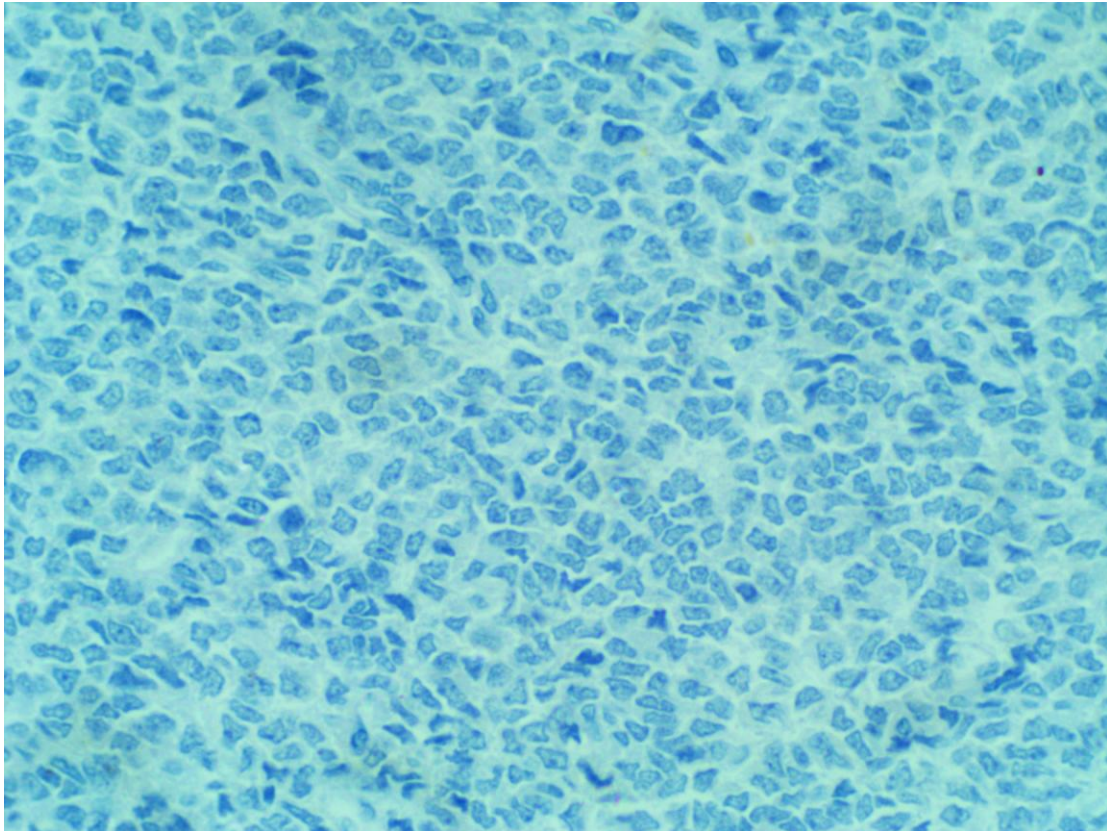


Figure 4: Desmin [400x]

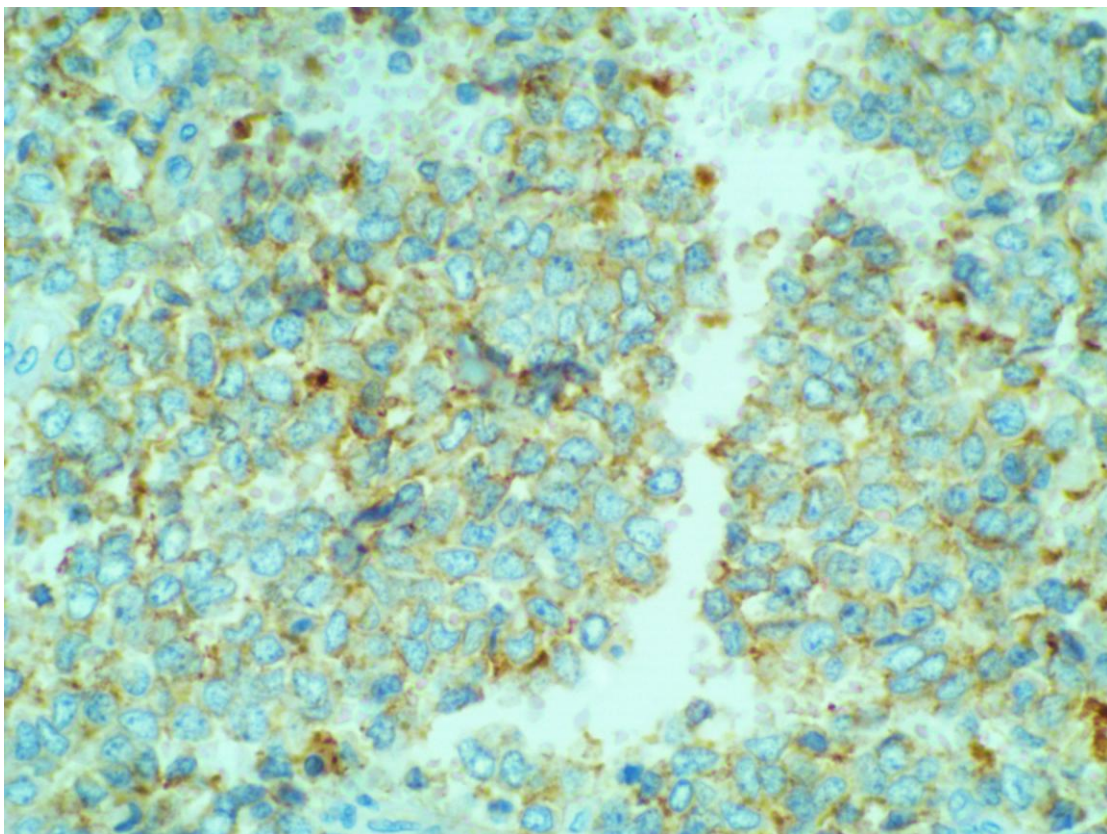


Figure 5: Membranous Positivity of CD99 [400x]

2. Discussion

First described by James Ewing in 1921, Ewing's Sarcoma comprises of 11% of all bone tumors. In 1975, Angervall and Enzinger first reported extraskeletal Ewing's sarcoma

occurring predominantly in adolescents and young adults between the age 10 and 30 years. It follows an aggressive course, with a high recurrence rate[2]. The peak incidence is between the age groups of 5 & 15 years with a slightly male preponderance [7]. The clinical diagnosis of EES is difficult

Volume 4 Issue 9, September 2015

www.ijsr.net

and many EES occur in young patients; therefore, those tumours can reach 10cm by the time of diagnosis[8]. Histologically, these tumours consist of small cells with round nuclei and little rim of cytoplasm. They belong to a heterogeneous group of malignant small round cell tumours that includes neuroblastoma, embryonalrhabdomyosarcoma and lymphoma[9]. The MIC2 gene product (CD99), although expressed in nearly all pPNET, is not specific and can also be detected in other small, blue round cell tumors like rhabdomyosarcoma, desmoplastic small round cell tumor, lymphoblastic lymphomas. However, the pattern of staining is often cytoplasmic, rather than the distinct membranous staining typical of pPNET. Central PNETs are reported to be negative for CD99 staining[1]. Confirmation of histologic findings can be achieved through molecular and cytogenetic studies. The characteristic chromosomal translocation t(11;22)(q24;q12) is found in about 90 % of ES, ESS and pNET. This translocation results in the fusion of the EWSR1 and FLI-1 genes, the end result being a hybrid EWSR1-FLI-1 protein that functions as an aberrant transcriptional regulator [10]. The second most common chromosomal translocation seen in ES is t(22;21)(q22;q12) resulting in EWS-ERG fusion protein in about 10 % of cases [11]. Other specific translocations for ES include EWS-ETV1 t(7;22), EWS-ETV4 t(17;22) and EWS-FEV t(2;22) [11]. FISH or real time-polymerase chain reaction (RT-PCR) can both be used in the molecular diagnosis of ES, ESS and pNET[11]. EES is a potentially curable disease. Nevertheless, in some cases surgery is required to resect the tumor with wide tumor-free margins together with chemotherapy based on multiple antineoplastic drugs and, in some cases, with radiotherapy in order to obtain favorable clinical outcomes. Therefore, the disease requires a multimodal, aggressive therapeutic strategy[12].

3. Conclusion

Our case highlights an usual case of EES arising in the mesocolon. Only 2 primary mesocolon ESS have been described previously in the literature of which only one in an adult[same]and one in a child[13]. We conclude that although rare and uncommon, EES should be included in the differential diagnosis of a mass in the abdomen. Speedy diagnosis should allow for optimal therapy to proceed and provide better patient care and management.

References

- [1] Velivela K, Rajesh A, Uppin MS, Purohit AK. Primary intracranial peripheral PNET" - A case report and review. *Neurol India* 2014;62:669-73.
- [2] Ikhwan SM, Kenneth VKT, Seoparjoo A, et al. *BMJ Case Rep* doi:10.1136/bcr-2013-009584.
- [3] Michael C. Lynch et al. Extraskelatal Ewing's Sarcoma Arising in the Larynx Head and Neck *Pathol* (2014) 8:225-228.
- [4] Juan SuárezAntelo et al. Pulmonary Ewing Sarcoma/Primitive Neuroectodermal Tumor: A Case Report and Review of the Literature. *Arch Bronconeumol*. 2010;46(1):44-46.
- [5] Somarouthu BS, Shinagare AB, Rosenthal MH, Tirumani H, Hornick JL, Ramaiya NH, et al. Multimodality imaging features, metastatic pattern and clinical outcome in adult extraskelatal Ewing sarcoma: experience in 26 patients. *Br J Radiol* 2014;87:20140123.
- [6] Maisonnette F et al. Ewing sarcoma of the mesocolon *Gastroenterol Clin Biol*. 2007 May;31(5):552-4.
- [7] Pritchard DJ, Dahlin DC, Dauphine RT, Taylor WF, Beabout JW. Ewing's sarcoma. A clinicopathological and statistical analysis of patients surviving five years or longer. *J Bone Joint Surg Am* 1975;57:10- 6.
- [8] Paoletti H, Colineau X, Acalet L, Tourrette JH, Civatte M, Fesselet J et al. Ewing's sarcoma of the soft tissues: apropos of 3 cases and review of the literature. *J Radiol* 1999;80:477-82.
- [9] Baldini EH, Demetri GD, Fletcher CDM, et al. Adults with Ewing's sarcoma/ primitive: neuroectodermal tumor adverse effect of older age and primary extraosseous disease on outcome. *Ann Surg* 1999;230:79-86.
- [10] Nagao K, Ito H, Yoshida H, et al. Chromosomal rearrangement t(11;22) in extraskelatal Ewing's sarcoma and primitive neuroectodermal tumour analysed by fluorescence in situ hybridization using paraffin-embedded tissue. *J Pathol*. 1997;181:62-6.
- [11] Lewis TB, Coffin CM, Bernard PS. Differentiating Ewing's sarcoma from other round blue cell tumors using a RT-PCR translocation panel on formalin-fixed paraffin-embedded tissues. *Mod Pathol*. 2007;20:397-404.
- [12] Ahmet Mesur Halefoglu. Extraskelatal Ewing's Sarcoma Presenting as a Posterior Mediastinal Mass. *Arch Bronconeumol*. 2013;49(2):82-8.
- [13] Turkyilmaz Z et al. Extraskelatal Ewing sarcoma of the mesocolon in a child. *J Pediatr Surg*. 2012 Sep;47(9):E1-3. doi: 10.1016/j.jpedsurg.2012.04.009.