

Epidemiological Trends in Brain Abscess: A Study at a Tertiary Care Centre

Kulwant Singh Bhaikhel¹, Neeraj Shende², Vikul Kumar³, Anshu Singh⁴

¹Associate Professor, Department of Neurosurgery, Institute of Medical Sciences Banaras Hindu University, Varanasi, Uttar Pradesh, India

²Senior Resident, Department of Neurosurgery, Institute of Medical Sciences Banaras Hindu University, Varanasi, Uttar Pradesh, India

³Senior Resident, Department of Neurosurgery, Institute of Medical Sciences Banaras Hindu University, Varanasi, Uttar Pradesh, India

⁴Senior Resident, Department of Pathology, Institute of Medical Sciences Banaras Hindu University, Varanasi, Uttar Pradesh, India

Abstract: Background: Despite the recent advances in diagnosis and management, brain abscess still remains a highly lethal lesion. It has been noted that there is little change in the incidence of brain abscess over the past 20 yrs. Aims: To determine the current epidemiological trends, clinical presentation and commonest organism of brain abscess in this part of the country. Material and Methods: 59 cases admitted during dec 2012 to june 2014 in the department of neurosurgery of SSH BHU, Varanasi were included in the study. Detailed clinical history was taken and detailed neurological examination was done including assessment by glasgow coma scale(GCS).Relevant laboratory investigations were done as needed along with CT scan and /or MRI. Patients were managed by aspiration or surgical excision and aspirated material sent for microbiological examination. Results were collected and analysed. Results: Chronic suppurative otitis media (CSOM) was the commonest cause of infection in 31 patients (52.5%).Trauma was encountered in 7 cases (11.8%) with one having traumatic rhinorrhoea. Other causes were haematogenous spread of infection from distant sites and meningitis. No source could be identified in 13 patients (22%). Conclusion: Chronic suppurative otitis media (CSOM) is still a major cause of brain abscess in developing country like India which is a benign curable disease and should not be neglected. Prompt diagnosis and treatment allows immediate decompression of mass reduces duration of antibiotic stay and minimizes treatment cost.

Keywords: brain abscess, intracranial abscess, epidemiology, csom, headache

1. Introduction

Intracranial abscess is a focal suppurative process within and around the brain parenchyma caused by a spectrum of microbes. They include brain abscess and subdural or extradural empyema. Although a benign condition, cases with extensive edema can lead to acute intracranial hypertension and death. Little change has been noted in the incidence of brain abscess over a 20 year period despite the widespread use of antibiotics and improved living condition¹Samson and clerk² suggested that the incidence may actually be rising due to rapidly increasing incidence of opportunistic infection in immune compromised hosts. This increase is more likely due to increased detection and diagnosis with modern imaging techniques. The incidence has remained relatively stable in the antibiotic era.³

2. Literature Survey

Intracranial abscess is caused by a spectrum of microbes. However the causes vary in developed and developing countries and also in different areas in a country. So studies are needed for evaluation of epidemiological trends.

3. Aims

The present study was done with following aims:

- 1) To determine the epidemiological trends of brain abscess in this part of the country.
- 2) To determine the various clinical presentation of patients with brain abscess and its different causes.

4. Material and Methods

59 cases admitted during dec 2012 to June 2014 in the department of neurosurgery of SSH BHU, Varanasi were included in the study. The institute caters to vast area of rural population Detailed clinical history pointing to any septic focus was taken. Detailed neurological examination was done including assessment by glasgow coma scale (GCS). Relevant laboratory investigations were done as needed along with CT scan and /or MRI for diagnosis confirmation and localization of abscess. Patients were appropriately managed by aspiration or surgical excision. Aspirated material was sent for microbiological examination to identify etiologic agent by smear examination, culture and sensitivity. Results were collected and analysed.

5. Results

The study included 59 patients with verified intraparenchymal brain abscesses treated between dec 2012 to jun 2014 in the department of neurosurgery. The observations are as follows:

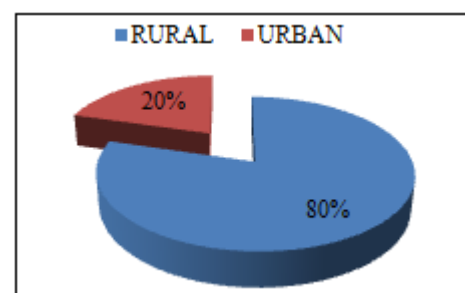


Chart 1: Rural and urban distribution of patients

In present study out of the total 59 patients 47 (79.6%) patients belonged to the rural areas and 12(20.4%) were from urban areas.[Chart 1]

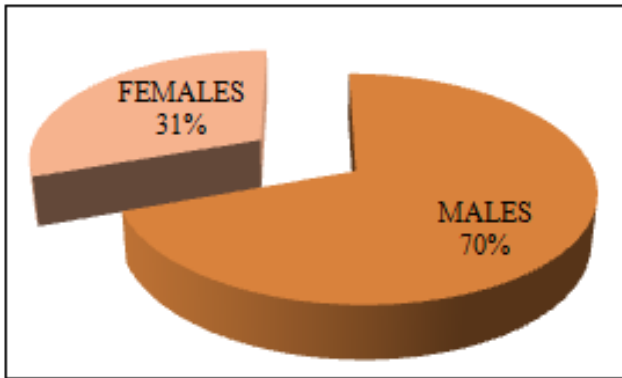


Chart 2: Sex wise distribution of patients.

The study included 41 male (69.5%) patients and 18 females (30.5%) The male:female ratio was 2.3:1. [Chart 2]

The age range of patients was from 3 years to 64 years. Most of the patients were young with age below 25 years.

Table 1: Aetiology

S.No	Aetiology	Total no of patients	Percentage
1.	CSOM	31	52.54
2.	Haematogenous	6	10.17
3.	trauma	7	11.86
4.	meningitis	2	3.39
5.	cryptic	13	22.04

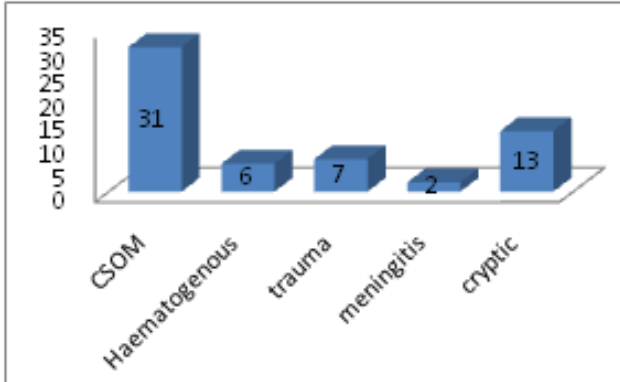


Chart 3: Aetiology.

Chronic suppurative otitis media (CSOM) was the commonest cause of infection. 31 patients (52.5%) developed brain abscess secondary to discharging ear(unilateral or bilateral).The duration of on and off ear discharge in these patients varied from 3 months to 10 years.6 cases showed haematogenous spread of infection from distant sites due to underlying heart disease, pulmonary disease and dental caries.1 patient had HIV infection. Trauma was encountered in 7 cases (11.8%) with one having traumatic rhinorrhea, where abscess was located in frontal lobe. Meningitis was present in 2 patients belonging to pediatric age group. No source could be identified in 13 patients (22%).[Table1][Chart 3]

Table 2: Clinical Features

No.	Clinical features	Total no of patients	Percentage
1.	Headache	47	79.67
2.	Nausea/ vomiting	34	57.63
3.	Fever	31	52.54
4.	Seizure	13	22.03
5.	Altered sensorium	18	30.50
6.	Focal neurological deficit	17	28.81
7.	Pupillary abnormality	8	13.56

In present study the most common presenting symptom was headache seen in 47 patients(79.7%) which was followed by nausea/vomiting in 34 patients (57.6%).Other presenting symptoms included fever, altered sensorium, focal neurological deficit, seizure and pupillary abnormality.

Table 3: Glasgow Coma Scale.

GCS	Cases	
	No of pts.	Percentage
3-8	8	13.55
9-12	13	22.03
13-15	38	64.42

All the patients were grouped according to GCS.13.5% of patients had GCS less than 9, while 22.03% had GCS between 9 to 12 and 64.42% of patients had GCS between 13 to 15.[Table 3]

Table 4: Causative organism

Nature of isolate	Organism isolated	No of cases
Pyogenic		29
Aerobe	Streptococcus	11
	Staphylococcus	6
	Pseudomonas	2
	Proteus	2
	Ecoli	1
	Citrobacter	1
	Kleibseilla	1
	Mixed	2
Anaerobe	Bacteroides	2
	Peptostreptococcus	1
Mycobacteria		2
Fungi	Aspergillus/candida	1
No organism isolated		23

On microbiological examination the culture was positive in 32 cases while no organism was detected in 23 cases.

6. Discussion

The difficulty in identification and localization of brain abscess before irreversible damage to the cerebral tissue has taken place is the limiting factor in the prognosis of the patient with intracranial brain abscess. With technological advancement in surgical techniques and advent of CT and MRI, more effective antibiotic regimes, the prognosis of brain abscess has greatly improved. In present study the incidence of brain abscess among intracranial space occupying lesions was higher 12.57% compared to 8% in study by Bhatia⁴ et al and 1-2 % by Loftus⁵ et al..This may be due to low socioeconomic status and poor living condition of the population catered by the institute who are more prone to infectious diseases. In present study there

were 69.5 % males and 30.5% females with a male female ratio of 2.23. In studies by Berlitz⁶ et al and Sinha⁷ et al also the incidence of brain abscess is more common in males compared to females where male female ratio was 2.5:1 and 2.72: 1 respectively. The present study encountered large number of intracranial abscess secondary to middle ear infection 58.9%. This was higher than observed in studies by Yang⁸ et al (37%) and Malik⁹ et al (34%) but correlate with the findings of Lakshmi¹⁰ et al and Bhardwaj¹¹ et al. This probably reflects the gravity of ear infection about which the people of this particular area are not aware. The most common clinical symptoms in patients were features of raised intracranial pressure- headache, nausea/vomiting in 82.25% and 62.65% patients respectively. Other symptoms were seizure, altered sensorium and focal neurological deficit. Studies by Morgan¹² et al and Nielsen¹³ et al showed similar presentation. Most of the abscesses were located supratentorially followed by temporal region. Literature shows change in microbiological profile of brain abscess in the past 50 yrs. Earlier staphylococcus aureus was the most common etiological agent but now streptococcus is most common followed by staphylococcus and pseudomonas are common causes of intracranial brain abscess as also seen in present study.^{9, 14} The incidence of anaerobic organisms is also increasing.¹⁵

7. Conclusion

CSOM is still a major cause of brain abscess in developing country like India which is a benign curable disease and should not be neglected. Prompt diagnosis and treatment allows immediate decompression of mass reduces duration of antibiotic stay and minimizes treatment cost.

8. Future Scope

Further study is required in different part of country to determine the true epidemiology of brain abscess in India.

References

- [1] Garfield J. Management of supratentorial intracranial abscess: A review of 200 cases. *Br Med J* 1969;2:7-11
- [2] Samson DS and Clark K. A current review of brain abscess. *Am J Med* 1973;54:201-210
- [3] Wispelway B, Scheld W. Brain abscess. In Mandell CL, Douglas RG, Bennett JE eds. *Principles and practice of infectious diseases*. New York: Churchill Livingstone 1990; p 777-788.
- [4] Bhatia R, Tandon PN, Banerjee AK. Brain abscess: an analysis of 55 cases. *Int Surg*. 1973;58:565
- [5] Loftus CM, Biller J. Brain Abscess. In Rengachary SS, Wilkins RH. *Principle of neurosurgery* McGraw Hill, London, 1996:3285-3296
- [6] Berlitz P, Fedel C, Tornow K, Schmiedeck P. Bacterial abscess-experiences with 67 patients. *Fortschr. Neurol. Psychiatr.* 1996;64(8):297-306
- [7] Sinha A.K, Mohanty S, Sharma V, Choudhary A, Huda MF Singh VP, Tiwari YA. A study of 268 consecutive cases of intracranial suppuration. *Neurosciences Today* 7, 165-165

- [8] Yang SY, Zhao CS. Review of 140 patients with brain abscess. *Surg Neurol* 1993;39(4):290-6
- [9] Malik S, Joshi SM, Kandoth PW, Vengsarkar US. Experience with brain abscesses. *Indian Pediatr* 1994;31:661-666.
- [10] Lakshmi V, Rao RR, Divakar I. Bacteriology of brain abscess. Observation in 50 cases. *J Med Microbiol.* 1993;38:187
- [11] Bhardwaj R & Joshi BN. Brain abscesses-a study of the causative organisms with special reference to anaerobes. *Indian J Pathol Microbiol* 1988;31(2):44-48
- [12] Morgan H, Wood MW and Murphy F. Experience with 88 consecutive cases of brain abscess. *J Neurosurgery.* 1973;38:698-704
- [13] Nielsen H, Carsten G, Harmsen A. Cerebral abscess: Etiology and pathogenesis; symptoms, diagnosis and treatment: a review of 200 cases from 1935-1976. *Acta Neurol, Scand* 1982;65:609-622
- [14] Estirado de Cabo E, Arzuaga Torre JA, Roman Garcia F, del Pozo Garcia JM, Perez Maestu R, Martinez Lopez de Letona J. Cerebral abscess: Clinical review of 26 cases. *Rev Clin Esp* 1995;195(5):304-7
- [15] Mampalam TJ, Rosenblum ML. Trends in the management of bacterial brain abscess: A review of 102 cases or 17 years. *Neurosurgery.* 1988; 23:451-458