

# Article of Carcinoma Brest with Tuberculosis of Breast

Dr. Sharad Sawant<sup>1</sup>, Dr. Bhosale Dattatray<sup>2</sup>

**Abstract:** Association of tuberculosis of breast with carcinoma of breast is very rare there may be tuberculosis of breast parenchyma or axillary lymph node

**Keywords:** Tuberculosis, Carcinoma, Breast, Node

## 1. Background

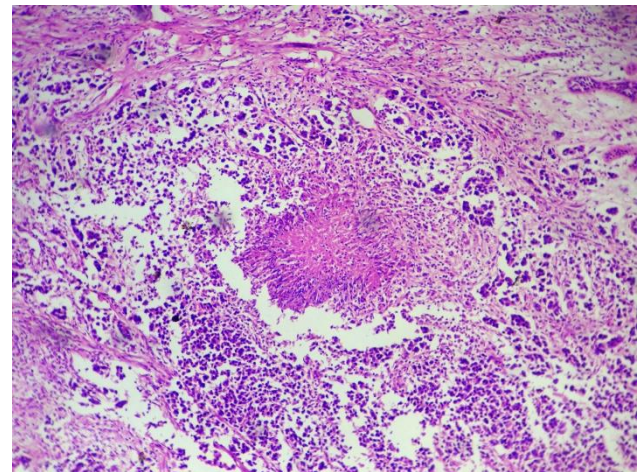
The association of carcinoma and tuberculosis of the breast is rare. The clinical situations that arise are the presence of carcinoma and tuberculous mastitis, carcinoma of the breast with axillary tuberculous adenitis or both.

## 2. Case Presentation

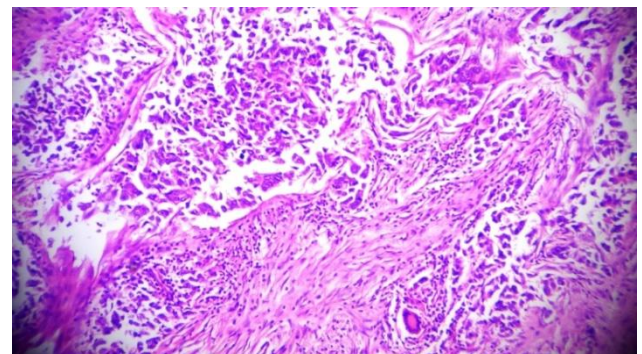
A 35 yrs old lady was seen in clinic for a rapidly increasing lump in the left breast which had been present for four months. There was no nipple discharge or nipple retraction and no family or past history of breast cancer or tuberculosis.

Clinical examination revealed a 5cm \* 4cm hard mass in the outer upper quadrant of left breast not fixed to skin or muscle. There was also a 2cm \*2cm palpable lymph node in the left axilla location (TNM Staging stage 2B). Ultrasound of left breast revealed approximately 5\*4 cm hypoechoic lesion with irregular borders and there was also 1.3 cm \*1.9 cm left axillary lymph node.

Fine needle aspiration cytology of the mass was suggestive of invasive carcinoma of the left breast. Abdominal ultrasound was normal, her liver function test, renal function test were normal. She underwent left sided modified radical mastectomy with axillary lymph node dissection up to level 1. The HPR was suggestive of invasive ductal carcinoma (no special type) grade 1 (2+2+1=5) according to Modified Bloom Richardson's system and multiple caseating granulomatous inflammation present in the breast tissue suggestive of tuberculosis was seen. ZN staining for acid fast bacilli were negative in this specimen. Section through axillary lymph nodes show no evidence of tumour. Subsequently patient investigated her Erythrocyte sedimentation rate is 13 mm/h, Chest x-ray was within normal limit, sputum for acid fast bacilli is negative.



**Figure 1:** Microphotograph showing caseation along with tumour, H&E, 4x.



**Figure 2:** Photomicrograph showing tumour along with granulomas and giant cells, H&E, 10x

Patient was discharged on post operative day ten and she is advised chemotherapy and category 1 anti tuberculous drugs under DOTS.

## 3. Discussion

Originally described by Kessler and Wolloch in 1972, idiopathic granulomatous mastitis should be differentiated from other forms of periductal mastitis. Although the exact aetiology remains unclear, associations with autoimmune disorders, oral contraceptive use, pregnancy, hyperprolactinemia, and alpha-1-antitrypsin deficiency have been suggested (14). Granulomatous inflammation of the breast is an inflammatory process with multiple aetiologies. It can be caused by tuberculosis, idiopathic granulomatous mastitis (GM), sarcoidosis, fungal infections like actinomycosis, parasite like filariasis, Wegener's

granulomatosis, duct ectasia, brucellosis, and traumatic fat necrosis(3). The commonest clinical presentation is that of a lump, , painful or not, most often located in the central or upper outer quadrant of the breast. Based on radiological and clinical characteristics the tuberculous mastitis can be described by three forms: nodular, diffuse and sclerosing. The nodular form is well circumscribed; slow growing, with an oval tumor shadow on mammography, which can hardly be differentiated from breast cancer. The disseminated form is characterized by multiple lesions associated with sinus formation. This form mimics inflammatory breast cancer on mammography. The sclerosing form of the disease is seen in elderly women and is characterized by an excessive fibrotic process(11 12 13). The coexistence of carcinoma and tuberculosis (TB) of the breast and the axillary lymph nodes is rare and was first reported by Pilliet and Piatot in 1897(6,7). TM is rare even in countries where tuberculosis is still common, accounting for 0.1 % of all cases(7,10). This is probably due to increased breast tissue restraints to the survival and multiplication on mycobacterium bacilli, antituberculous treatment, and under diagnosis of TM(10). The breast can be involved by a penetrating wound of the skin of the breast; the lactiferous duct via nipple; direct extension from the lungs and chest wall; the blood stream and the lymphatics(8). It is generally believed that tuberculous infection of the breast is usually secondary to a preexisting tuberculous focus located elsewhere in the body such as pre-existing focus could be of pulmonary origin or mammary or axillary lymph nodal basin(5).

Typically, the clinical picture is not one of active disease. In a review of 100 cases of TB mastitis in India, constitutional symptoms of fever, weight loss, night sweats, and failing general health were present in 20% of patients only. Pulmonary symptoms such as persistent cough with sputum were found in only 2 patients. The chest radiograph was normal in 94 patients, old calcific TB was evident in 4 patients, and 2 patients had active pulmonary TB(15). There does not appear to be a casual link between mammary tuberculosis and breast cancer, and there is no evidence that TB is carcinogenic at any site(9). The simultaneous occurrence of carcinoma and tuberculosis can lead to many problems regarding diagnosis and treatment as there are no pathognomic symptoms or signs to distinguish breast tuberculosis from breast cancer ,especially if the upper outer quadrant is involved ( 8 ,10).An isolated breast mass with out an associated sinus tract can commonly mimic the presentation of breast cancer since the clinically palpable breast mass is usually firm, ill defined ,irregular , and can be associated with fixation to the skin(5). A unique finding strongly suggestive of TM is the presence of a dense sinus tract connecting an ill defined breast mass to localized skin thickening and bulge(10). The key to proper treatment is biopsy of the lesion(6). If breast cancer is operable , radical mastectomy is indicated, followed by postoperative antituberculous chemotherapy for 18 months and if the cancer is incurable , palliative measures combined with antituberculous drugs are indicated (6).

#### 4. Conclusion

Breast TB is an obscure disease often mistaken for carcinoma especially if well-defined clinical features are

absent. The existence of tuberculosis and carcinoma in the breast is very rare. Their clinical and radiological presentations are very similar. Histology remains the keystone in confirming the diagnosis. Full liaison between surgeons, radiologists and pathologists is very important to plan best management of such conditions.

#### References

- [1] Going J ,Anderson T ,WillkinsonS,Chetty U :granulomatous lobular mastitis.Jclinpathol 1987, 40:535-540.{2}
- [2] Tuncbilek N , Karakas H ,Okten : Imaging of granulomatous mastitis: assessment of three cases. The breast 2004 ,13(6) :510-514.{4}
- [3] Akan A, Akyildiz H, DenemeM ,Akgun H ,Aritas Y : Granulomatous lobular mastitis : a complex diagnostic and therapeutic problem. World J surg2006 , 30:1403-1409.{1}
- [4] Heer R, Shrimankar J Griffith C : Granulomatous mastitis can mimic breast cancer on clinical, radiological or cytological examination : a cautionary tale. The breast 2003, 12(4):283-286.{3}
- [5] Akcay M , Saglam L, PolatP,ErdoganF,Albayrak Y, Povosaki S: Mammary tuberculosis-importance of recognition and differentiation from that of a breast malignancy; report of three cases and review of the literature. World J surgOncol 2007, 5:67.{9}
- [6] Miller R, Salomon P, West J: The coexistence of carcinoma and tuberculosis of the breast and axillary lymph nodes. Am J Surgery 1971, 121: 338-340.{7}
- [7] BalliniA,Zaritzky A, Lupo L: Radhika T : Spectrum of coexistence of carcinoma and tuberculosis in the breast and axillary lymph nodes. Am J Surgery 1971, 121:338-340.{5}
- [8] Tulasi N, Raju P, Damodaran V, Radhika T : Spectrum of coexistent tuberculosis of the breast and axillary lymph nodes. Am J Surgery 1971, 121: 338-340.{6}
- [9] Roinson A, Horne C Weaver A: Coexistence of axillarytuberculous lymphadenitis with lymph node metastasis from a breast carcinoma. Clinoncol 2001, 13:144-147.{10}
- [10] Bani-Hani K, Yaghan R, Matalka I, Mazahreh T: Tuberculous mastitis: a diseases not to be forgotten. Int J tuberc lung Dis 2005, 9(8):920-925.{8}
- [11] Maroulis, C. Spyropoulos, V. Zolota, E. Tzorakoleftherakis Mammary tuberculosis mimicking breast cancer: a case report Journal of Medicine Case Reports, 2 (2008), p. 34
- [12] K.S. Madhusudhan, S. Gamanagatti Primary breast tuberculosis masquerading as carcinoma Singapore Medical Journal, 49 (2008), pp. e3–e5
- [13] M. Tewari, H.S. Shukla Breast tuberculosis: diagnosis, clinical features and management Indian Journal of Medical Research, 122 (2005), pp. 103–110
- [14] Bani-Hani KE Yaghan RJ Matalka Shatnawi NJ.Idiopathic granulomatous mastitis: Time to avoid unnecessary, Mastectomy. Breast J 2004;10:318-22.
- [15] Shinde S R,Chandawarkar RY, Deshmukh SP Tuberculosis of the breast masquerading as carcinoma: A Study of 100 patients.World J Surg 1995;19:379-81