

# Chemical Identification of Volatile Oil of *Nigella Sativa* and Evaluation of its *In-Vivo* Wound Healing Activity

Karan Kumar Das\*

Assistant Professor, Bharat Technology, Uluberia, West Bengal, India

Email: karankumardas103[at]gmail.com

**Abstract:** To screen the wound healing activity of oil of *Nigella sativa* in excision, incision and burn wound models in albino rats. The seeds of *Nigella sativa*. (Family Ranunculaceae) were grinded by a suitable grinder and was subjected to continuous extraction with the steam on steam distillatory. Volatile oil has been separated out and collected in a tightly closed container. The extract was tested for various preliminary phytoconstituents, the chemical structure has been identified by Infrared spectroscopy (IR) method and screened for wound healing activity in excision, incision and burn wound models in albino rats at the dose of 5% (v/v), 10% (v/v) in LLP formulation by topical administration. Oil of seeds of *Nigella sativa* has shown better wound healing activity in excision, incision and burn wound models as compared to povidone iodine (used as standard drug in excision and incision wound model) and silver sulfadiazine (used as standard drug in burn wound model). From the results obtained it can be concluded that extract of seeds of *Nigella sativa* has significant wound healing activity.

**Keywords:** *Nigella sativa*, Extraction, Excision wound model, Incision wound model, Burn wound model, wound healing

## 1. Introduction

Wound is inescapable events of life. When healing take place in a direction away from its normal course, it is common to have non, under or over healing. Treatment therefore aimed at either shortening the time required for healing or minimizing the undesired consequences. Research on wound healing drugs is a developing area in modern biomedical sciences. Scientists who are trying to develop newer drugs from natural resources are looking toward the Ayurveda, the Indian traditional system of medicine. Several drugs of plant, mineral, and animal origin are described in the Ayurveda for their wound healing properties. Most of these drugs are derived from plant origin. Some of these plants have been screened scientifically for the evaluation of their wound healing activity in different pharmacological models and patients, but the potential of most remains unexplored. In a few cases, active chemical constituents were identified. Some Ayurvedic medicinal plants, namely, *Ficus bengalensis*, *Rubia cordifolia*, *Pterocarpus santalinus*, *Ficus racemose*, *Glycyrrhiza glabra*, *Curcuma longa*, *Centella asiatica*, *Euphorbia nerifolia*, *Aloe vera* etc. were found to be effective in experimental models. Still there is a dearth of safe, economic and effective pro-healing agents for the wound management programme, which can enhance healing as well as control infection.

Mainly there are 3 phases of wound healing:

- **Inflammatory Phase (0-3 days):** The inflammatory phase of wound healing begins immediately after injury. Injury causes disruption of the small vessels in and around the skin resulting in bleeding. The immediate response is for the vessels to constrict, limiting hemorrhage. After a clot is formed, it soon dissipates and the blood vessels open up (vasodilatation) to increase blood flow to the injury site. This occurs about

10 minutes after the injury. This increased blood flow bringing inflammatory cells to fight infection and other cells to clean up the damaged tissue. The result is redness and swelling around the injured site for 2-3 days.

- **Proliferative Phase (3-21 days):** The proliferative phase overlaps the inflammatory phase and occurs 3-5 days following injury and lasts for 14-21 days. The three important segments of the proliferative phase of wound healing are epithelialization, fibroplasia, and angiogenesis. **Epithelialization** is the process of new skin formation over the injured area. **Fibroplasia** is the process of fibroblasts forming and laying down new collagen. **Angiogenesis** is the process of forming new blood vessels.
- **Maturation Phase (2 weeks-1 year):** The maturation phase of wound healing is characterized by collagen remodeling. During the proliferation phase, type III collagen is laid down in a random, disorganized fashion. Type I collagen, which is a stronger type of collagen, replaces type III and the collagen becomes more organized. Remodeling usually begins about 21 days after the injury and continues for about a year. The tensile strength of a wound reaches its peak in 60 days, but a healed wound will never reach full strength and may only have 80% of its original tensile strength.

The present work deals with *in-vivo* evaluation of the extract (volatile oil) of *Nigella sativa* extracted by steam distillation for wound healing activity.

## 2. Objectives

A prospective and retrospective study of “Chemical identification of volatile oil of *Nigella sativa* and evaluation of its wound healing activity.” was undertaken

at the laboratory of Bharat Technology, Uluberia, West Bengal with the following aims and objectives.

1. Preliminary phytochemical investigation of extracts (volatile oil) of *Nigella sativa*.
2. Infrared (IR) spectral analysis of the extracts (volatile oil) of *Nigella sativa*.
3. Oral dose determination of the extracts through acute oral toxicity studies.
4. Proper formulation determination of the extracts.
5. Investigation of wound healing activity of the extracts by using following animal models:
  - a. Wound excision model.
  - b. Wound incision model.
  - c. Burn model.

The following parameters were checked in the present study to assess the effects of *Nigella sativa* seed extract on wound healing:

- Collagenation phase of healing (for this incision wound model)
- Wound contraction (excision wound model and burn wound model)
- Epithelization phases of healing (excision wound model and burn wound model).

### 3. Methodology

#### • Experimental Animals:

Albino Wister rats weighing 120-150 gm. of either sex were used to study in different models. The animals were procured from animal supplier, 2 weeks prior to study, so that the animals could adapt to the new environment. Animal house was well maintained under standard hygienic conditions, at a temperature (22±2°C), 65% relative humidity, 12 hr light and dark cycle. Rats were housed in groups of 4 in polypropylene cages (32x24x16cm). They were provided with commercial food pellets and tap water. Cleaning and sanitation works were done on alternate days. Paddy husk was provided as bedding material, which was changed every day. The cages were maintained clean and all experiments were conducted between 10am-5pm.

#### • Materials:

General surgical materials were obtained from Chatterjee Scientific Mart, Kolkata.

#### • Chemicals:

Twin 80, Light liquid paraffin (LLP) were obtained from Loba Chemie, *Aloe vera* (standard drug) gel formulation was obtained from Abhi Natural Products Pvt Ltd, T-36/38, Bhosari, Pune-26., Povidone iodine i.e. Zylo-P 5% w/v was obtained from Leben Laboratories Pvt. Ltd., Silver sulphadiazine ointment i.e. Silverex 1% w/w was obtained from Rexcin Pharmaceutical Pvt. Ltd.

#### • Methods:

##### ➤ Extraction of *Nigella sativa* Seeds

The powdered seeds of *Nigella Sativa* were subjected to successive extraction of volatile oil with the steam of water on steam distillatory. Volatile oil separated out along with water, collected in a beaker. The pure volatile oil is collected from the upper layer of water by an insulin syringe and collected. Volatile oil has been stored in a tightly closed container and kept in a cool and dark place.

##### ➤ Preliminary Phytochemical Investigations of The Extracts

The oil of *Nigella sativa* were subjected to qualitative analysis for various phytoconstituents like alkaloids, carbohydrates, cardiac glycosides, steroids, triterpenoids, saponins, tannins, proteins, amino acids, flavonoids, volatile oils and fixed oils.

##### ❖ Test for Alkaloids:

The extract (volatile oil) were treated with few drops of dilute hydrochloric acid and filtered. The filtrate was tested for the presence of alkaloids.

1. **Hager's test**-Extract treated with Hager's reagent (saturated picric acid solution), yellow precipitate.
2. **Mayer's test**-Extract treated with Mayer's reagent (potassium mercuric iodide solution), cream precipitate.
3. **Dragendroff's reagent**-Extract treated with Dragendroff's reagent (potassium bismuth iodide solution), orange precipitate.
4. **Wagner's test**-Extract treated with Wagner's reagent (iodine-potassium solution), reddish-brown precipitate.

##### ❖ Test for Carbohydrates:

Dissolved small quantities of extracts separately with 5ml of distilled water and filtered. The filtrate was subjected to Molisch's test. Extract treated with Molisch reagent (alpha naphthol in 95% ethanol) and few drops of concentrated hydrochloric acid at the sides of the test tube, violet ring at the junction. A small portion of extract was separately treated with the following ways:

1. **Fehling's test**-Extract heated with Fehling's reagent (Fehling's reagent A-Copper sulphate in water and Fehling's reagent B-Sodium potassium tartarate), red colour.
2. **Barfoed's test**-Extract heated with Barfoed reagent (copper acetate in water and glacial acetate), red colour.
3. **Benedict's test**-Extract heated with Benedict reagent (copper sulphate, sodium citrate and sodium carbonate in water), red colour.

##### ❖ Tests for Steroids, Triterpenoids and Cardiac Glycosides:

1. **Liebermann-Burchard test**-10 mg extracts were dissolved in 1ml of chloroform; 1ml of acetic anhydride was added following the addition of 2ml of concentrated

sulphuric acid from the sides of test tube. Formation of reddish violet colour at the junction indicates the presence of steroids, triterpenoids and cardiac glycosides.

- 2. Salkowski test**-1ml of concentrated sulphuric acid was added to 10mg of extracts dissolved in 1ml of chloroform. A reddish brown colour exhibited by chloroform layer and green fluorescence by the acid layer suggests the presence of steroids.
- 3. Noller's test**-5mg of extracts were dissolved in 2ml of 0.01% anhydrous stannic chloride in pure thionyl chloride. Formation of purple colour indicates the presence of triterpenoids.
- 4. Legal's test**-The extracts were treated with sodium nitroprusside in pyridine and methanolic alkali. The formation of pink colour indicates the presence of cardiac glycosides.
- 5. Keller Killani's test**-5mg of extracts were treated with 1ml of glacial acetic acid and few drops of ferric chloride solution in a test tube. 2ml of concentrated sulphuric acid was added carefully along the sides of the test tubes. The formation of reddish brown colour at the junction of two layers and formation of bluish green upper layer indicates the presence of deoxy sugar in carbohydrates.

#### ❖ Test for Saponins:

1. Diluted 1ml of extracts separately with distilled water to 20ml and shake in a graduated cylinder for 15min. One centimeter layer of foam indicates the presence of saponins
- 2. Hemolysis test**-2ml of 1.8% sodium chloride solution was taken in two test tubes. To one test tube 2ml of distilled water was added and to another 2ml of 1% filtrate. Blood is obtained by pricking the thumb and 5 drops of blood were added to each tube, the contents were gently mixed and observed under microscope. If hemolysis occurs then saponins are present.

#### ❖ Test for Tannins:

Diluted small quantities of extracts with distilled water and subjected to the following tests:

- 1. Ferric chloride test**-Extract treated with ferric chloride solution, blue colour.
- 2. Gelatin test**-Extract treated with gelatin solution, white precipitate.
- 3. Lead acetate test**-Extract treated with lead acetate solution, yellow precipitate.

#### ❖ Test for Proteins and Amino Acids:

Dissolved small quantities of extracts separately with few drops of distilled water and then subjected to the following tests:

- 1. Millon's test**-Extracts treated with Millon's reagent (mercuric nitrate in nitric acid), red colour.
- 2. Biuret test**-Extracts treated with sodium hydroxide and copper sulphate solution added dropwise and mixed, violet colour.

- 3. Ninhydrin test**-Extracts treated with Ninhydrin reagent and ammonia, heated, violet colour.
- 4. Sodium bicarbonate test**-Extract treated with sodium bicarbonate solution, brisk effervescence.

#### ❖ Test for Flavonoids:

- 1. Ferric chloride test**-To extracts few drops of neutral ferric chloride solution, blackish red colour.
- 2. Lead acetate test**-To extracts add lead acetate solution, yellow precipitate.
- 3. Magnesium ribbon test**-To extracts added few fragments of magnesium ribbon and concentrated hydrochloric acid along the sides of test tubes, magenta colour.
- 4. Zinc-hydrochloric acid test**-To extracts a pinch of zinc dust was added and concentrated hydrochloric acid along the sides of test tubes, magenta colour.

#### ❖ Test for Volatile Oils:

1. To the thin section of the extract add alcoholic solution of Sudan III. Red colour obtained by globules indicate the presence of volatile oils.
2. To the thin section of the extract add a drop of tincture alkane. Red colour indicates the presence of volatile oils.

#### ❖ Test for Fixed Oils:

1. Mix 1ml 1% copper sulphate solution and 5 drops of extracts. Then add 5 drops of 10% sodium hydroxide solution. A clear blue solution is obtained which shows fixed oil is present in the sample. The cupric hydroxide formed in the reaction does not precipitate out as it is soluble in fixed oil.
2. Take 5 drops of extract in a test tube and add a pinch of sodium hydrogen sulphate. Pungent odour from the tube indicates the presence of fixed oil.

#### ➤ Infrared (IR) Spectroscopic Analysis of The Oil

##### Name of Infrared Spectrophotometer:

SHIMADZU

**Model of Infrared Spectrophotometer:** FTIR-8400S

**Phase:** Liquid

**Solvent:** Chloroform

**Extracts:** The oil under investigation viz *Nigella sativa* oil has collected by steam distillation procedure.

#### ➤ Selection of Dose and Treatment Period

The LLP formulation has been prepared for topical administration. *Nigella sativa* oil (5%) in LLP is used as low dose and *Nigella sativa* oil (10%) in LLP is used as high dose for topical use in excision, incision and burn wound model.

The treatment period was considered 10 days for incision wound model and the treatment period was considered till scar falling of wound in case of excision and burn wound model.

➤ **Acute Oral Toxicity Study** The acute oral toxicity study was performed according to the OPPTS (Office of the Prevention, Pesticides and Toxic Substance) guidelines following Up and Down Procedure. Male/Female rats of Wister strain (220-240g) were maintained under controlled standard animal house conditions with access to food and water. The rats were acclimatized for 5 days and fasted overnight, food but not water was withheld; limit and main test were performed. The limit test is carried out first at 5000mg/kg body weight for one animal and if animal dies, main test is performed. If the animal survives two more animals are dosed, if both survives the test should be terminated. The main test is performed with an initial dose of 175mg/kg body weight. The following sequence is followed:

175, 550, 1750 and 5000mg/kg body weights. First one animal is dosed with 175mg/kg body weight. If animal dies a much lower dose is tested. If animal survives, then two or more animals are dosed, after 48hrs. Observation of the first animal. If survives, then the main test should be terminated. If animal dies two or more animals are dosed and observed.

➤ **Evaluation of Wound Healing Activity:**

#### ❖ **Excision Wound Model:**

Four groups with total 10 animals were shaved by scissors and hair removing cream in the right lumber section. After 24 hours they were anaesthetized with chloroform. A circular piece of full thickness of skin was cut off from on the shaved area of the rat using a surgical blade and scissors having 500mm<sup>2</sup> square area. Bleeding was arrested using cotton wool. Ethyl alcohol was used as disinfectant on the wound area. The wounds were left undressed to open environment. The animals were divided in four groups. In 5% (v/v) extract gel group and 10% (v/v) extract gel group contains 6 animals each, povidone iodine 5% (w/v) group and liquid paraffin base group contains 6 animals in each group. The animals of each group were placed in separated cages. 5% (v/v) extract gel and 10% (v/v) extract gel was called low dose (L. D.) group and high dose (H. D.) group respectively, povidone iodine and liquid paraffin was called standard group and control group respectively. Then the drugs i. e. 5% (v/v) LD gel, 10% (v/v) HD gel, povidone iodine 5% (w/v) and liquid paraffin base were applied topically to the scheduled animals till the wounds were healed completely.

#### ❖ **Incision Wound Model**

Wister male albino rat weighing between 250-275 gm body weigh were divided into four groups same as followed in excision wound model.

Para vertebral straight incision of 6 cm length each was made through the entire thickness of the skin, on either side of the vertebral column with the help of a sharp scalpel. After complete homeostasis the wound were closed by means of interrupted sutures placed at equidistance points about 1 cm apart. Animals were treated daily with drugs, from 0 day to 9<sup>th</sup> post-wounding day. On 10<sup>th</sup> day of wounding the wound breaking strength were estimated by continuous, constant water flow technique. Allis forceps were firmly applied on either side of incision wound 3 mm away from wound margin on adjacent normal skin. The forceps on one side was hooked to a fixed metal rod while the other forcep was attached to a thread suspended by weights running over a pulley. As soon as gapping of the wound occurred, addition of weights was stopped and simultaneously the weights were lifted so as to avoid opening of the entire wound. The weights required to produce gapping were noted.

#### ❖ **Burn Wound Model**

Wister male albino rat weighing between 250-275 gm were divided into four groups same as mentioned earlier in excision wound, except here the standard group has received silver sulphadiazene instead of povidone iodine.

Partial thickness burn wounds were inflicted, on overnight-starved animals under pentobarbitone (30 mg/Kg) anesthesia, by pouring hot molten wax at 80<sup>o</sup>C into a cylinder of 300 mm<sup>2</sup> circular openings placed on the shaven back of the animal until the wax get solidified. Which took about 10-12 minutes then the cylinder with wax adhered to the skin was removed which left demarked partial thickness circular burn wound of 300mm<sup>2</sup>. Immediately after the injury and on subsequent days the drugs or vehicle was applied topically. Apart from the drug under investigation no local/systemic chemotherapeutic cover was provided to the animals.

#### • **Statistical Analysis**

Results are expressed as mean±S. E. M. The differences between experimental groups were compared by one-way Analysis of Variance (ANOVA) (control vs. treatment) followed by Bonferroni's test and were considered statistically significant when P<0.05.

## 4. Results

#### • **Extraction of *Nigella sativa* Seeds**

The successive extraction of powdered seeds of *Nigella Sativa* with the steam of water on steam distillatory. The oil extraction yield from crude *Nigella sativa* is 12%.

#### • **Preliminary Phytochemical Investigation**

The preliminary phytochemical investigation of the extract (oil) of the medicinal plant *Nigella sativa* revealed the presence of following chemical constituents (Table-1)

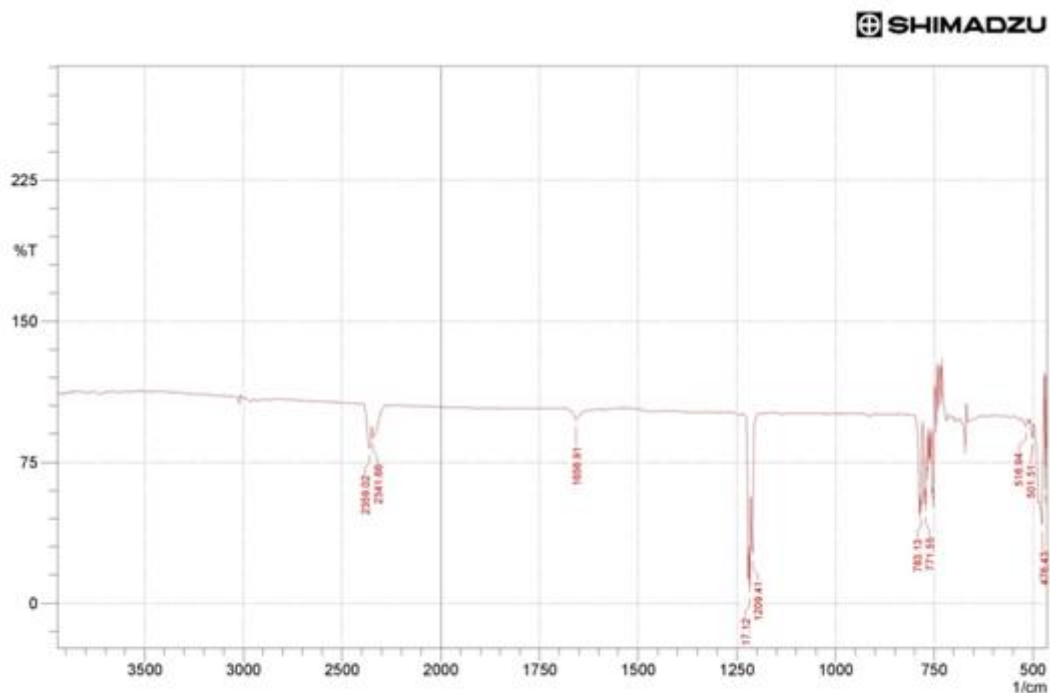


**Table 1:** Preliminary phytochemical investigation of extract (oil) of *Nigella sativa*

Extract	Chemical constituents present
<i>Nigella sativa</i> extract (NSE)	Steroids, Fixed oils and Volatile oils

• **Infrared (IR) Spectroscopic Analysis of The Oil**

The Infrared spectra of the oil are shown below:



Peak	Intensity	Corr. Intensity	Base (H)	Base (L)	Area	Corr. Area	
1	426.28	32	127.26	432.07	422.42	2.12	3.87
2	443.64	16.76	136.25	445.57	439.78	2.07	2.51
3	468.72	60.75	61.24	470.65	466.79	0.26	0.58
4	476.43	41.48	62.81	495.72	472.58	4.56	4.59
5	501.51	87.63	8.67	507.3	497.65	0.35	0.19
6	516.94	93.99	4.02	530.44	513.08	0.3	0.16
7	771.55	49.07	42.79	777.34	765.77	2.16	1.74
8	783.13	48.23	49.38	800.49	779.27	2.44	2.29
9	1209.41	25.8	17.91	1213.27	1188.19	2.24	0.44
10	1217.12	5.88	58.67	1224.84	1215.19	5.94	4.44
11	1656.91	97.46	4.3	1666.55	1641.48	0.04	0.22
12	2341.66	87.92	6.38	2347.45	2283.79	1.03	0.82
13	2359.02	82.18	14.47	2389.88	2349.38	1.47	1.37

Comment:

Date/Time: 03/03/2020 02:17:33 PM  
 No. of Scans; 30  
 Resolution; 4 [1/cm]  
 Apodization; Happ-Genzel  
 User; FTIR

• **Acute Oral Toxicity Study**

There was no mortality in control groups of rat up to a dose of 5000mg/kg body weight of the extract (oil) of the medicinal plant *Nigella sativa* (Table-2).

**Table 2:** Acute oral toxicity study of extract (oil) of *Nigella sativa* on rats

Drugs studied	Dose mg/kg body weight				Inference
	175	550	2000	5000	
<i>Nigella sativa</i> oil	0	0	0	0	Stop dosing

0 = Survived

• **Evaluation of Wound Healing Activity**

➤ **Excision Wound Model**

A significant decrease in period of epithelization was observed after N. S. E. (5%) and N. S. E. (10%) on application. Treatment with Povidone iodine (standard) also significantly reduced period of epithelization as compared with control group. At the same time N. S. E. (5%) and N. S. E. (10%) and Povidone iodine also decreased the wound contraction (50%) as compared with control. Comparative analysis revealed that N. S. (5%), N. S (10%) and Povidone iodine had almost equal wound healing activity (Table-3).

**Table 3:** Excision wound model study of oil of *Nigella sativa* on rats

Drugs studied	Epithelization period (days)	Wound contraction wc-50% (days)
Control (LLP)	21.00 + 0.3651	8.608 + 0.457
Povidone iodine	15.833 + 0.542***	5.660 + 0.375**
N. S. E. (5%) in LLP	14.01 + 0.577***	5.381 + 0.264***
N. S. E. (10%) in LLP	12.560 + 0.516***	4.294 + 0.141***

All values are mean + SEM, n=6, \*\* p<0.01, \*\*\* p<0.001 vs. control

### ➤ Incision Wound Model

The breaking strength of 10 day wound was significantly increased in all treatment groups when compared with control (Table-4).

**Table 4:** Incision wound model study of oil of *Nigella sativa* on rats

Drugs studied	Breaking strength
Control (LLP Base)	339.2 + 3.962
Povidone iodine	423.3 + 5.27***
N. S. E. (5%)	476.7 + 6.280***
N. S. E. (10%)	507.5 + 3.594***

All values are mean + SEM, n=6, \*\* p<0.01, \*\*\* p<0.001 vs. control

### ➤ Burn Wound Model

Both N. S. E. (5%) and N. S. E. (10%) applied topically shorten the period of epithelization significantly when compared with control. Silver sulfadiazine gel applied topically shortens the period of epithelization and all the three also decreased the wound contraction (50%) significantly as compared with control (Table-5).

**Table 5:** Burn model study of oil of *Nigella sativa* on rats

Drugs studied	Epithelization period (days)	Wound contraction wc-50% (days)
Control (LLP Base)	20.50 + 0.500	7.87 + 0.320
Silver sulfadiazine	16.16 + 0.401***	5.37 + 0.275***
N. S. (5%) in LLP	14.33 + 0.614***	4.31 + 0.225***
N. S (10%) IN LLP	16.50 + 0.670***	5.22 + 0.274***

All values are mean + SEM, n=6, \*\* p<0.01, \*\*\* p<0.001 vs. control

## 5. Discussion

The present study was undertaken to evaluate whether *Nigella sativa* seed oil could promote wound healing in experimentally produced wounds in rats. This observation substantiates the use of *Nigella sativa* seeds in folklore medicine for the treatment of wounds.

The study was designed to investigate the influence of the oil of *Nigella sativa* seed on three main phases of wound healing, namely collagenation, wound contraction and epithelization.

In the present study the extract applied topically or given orally promoted the breaking strength the wound contraction and period of epithelization.

Collagenation, wound contraction and epithelization are crucial phase of wound healing.

The phase inflammation, macrophasia, fibroplasia and collagenation are intimately interlinked. Thus an intervention into any one of these phases by drugs could eventually lead to either promotion or depression of the collagenation phase of healing.

Growth hormone is also known to promote the proliferation of fibroblasts<sup>53</sup>, and fibroblast proliferation form the granulation tissue. In the dead space wound model *Nigella sativa* treatment increased granuloma tissue weight and breaking strength. Hence it can assume the pro-healing activity of *Nigella sativa* could be due to the direct or indirect influence on growth hormone release.

Lipid peroxidation is an important process of several types of injuries like burn, inflicted wound and skin ulcers are any drug that inhibits lipid peroxidation is believed to increase the viability of collagen fibrils, increasing the strength of collagen fibers by an increase in circulation, thereby preventing the cell damage and promoting the DNA synthesis. It is reported that antioxidants, such as metronidazole, vitaminC, vitaminE have been shown to promote wound contraction and epithelization<sup>54</sup>. The antioxidant property of the *Nigella sativa seeds*, conferred upon it by the presence of high amounts of tannin, may be responsible to the prohealing action of the extract in wound models.

Since *Nigella sativa* is more potent than povidone iodine in excision, incision and silver sulfadiazine in burn wound. Isolation of the active principle from the oil may lead to development of a wound healing agent that may turn out to be a promising agent in not only open wound but also leg ulcer, skin grafting and severe type of burn.

## 6. Conclusion

The preliminary phytochemical investigation of the oil extracted from the seeds of *Nigella sativa* revealed that it contains volatile oil, fixed oil, steroids and saponins.

In the excision wound model, a significant decrease was observed in the wound closure and epithelization period at both dose levels as compared to standard and control. Tensile strength was measured to confirm the wound healing activity claimed for this plant, in the incision wound model. An increase in tensile strength of extract treated wounds as compared to standard and control may be due to an increase in collagen concentration and stabilization of the *fibers* facilitating wound healing. In the burn wound model, a significant decrease was observed

also in the wound closure and epithelization period at both dose levels as compared to standard and control.

So, *Nigella sativa* has wound healing effect evident by faster rate of wound closure and epithelization period in excision wound model, burn wound model and significant increase in skin breaking strength in incision wound model.

## References

- [1] Biswas TK, Mukherjee B. Plant medicines of Indian origin for wound healing activity: a Review. Int J Low Extrem Wounds. 2003; 2 (1): 25-39.
- [2] <http://www.bioskinrepair.com/regeneration/biologyofwoundhealing.html> retrieved on 14/5/2011 at 6.41pm.
- [3] <http://www.northcoastfootcare.com/pages/Wound-Healing.html> retrieved on 14/5/2011 at 6.39 pm.
- [4] [www.eco-planet.com/herbalextracts/Nigellasativa.htm](http://www.eco-planet.com/herbalextracts/Nigellasativa.htm) retrieved on 2.01.11 at 3.00pm
- [5] Padhye S, Banerjee S, Ahmad A, Mohammad R, Sarkar FH. Antitumor Activity of Gemcitabine and Oxaliplatin is augmented by thymoquinone in pancreatic cancer. Cancer Ther.2008; 6 (b): 495-510.
- [6] Kanter M, Coskun O, Uysal H. The antioxidative and antihistaminic effect of *Nigella sativa* and its major constituent, thymoquinone on ethanol-induced gastric mucosal damage. Archives of Toxicology. 80 (4); 217-224.
- [7] Zaoui A, Cherrah Y, Lacaille-Dubois MA, Settaf A, Hassar M. Diuretic and hypotensive effects of *Nigella sativa* in the spontaneously hypertensive rat. Therapie.2000; 55 (3): 379–382.
- [8] A. Benhaddou-Andaloussi Martineau LC, Vallerand D, Haddad Y, Afshar A, Settaf A, Haddad PS. Multiple molecular targets underlie the antidiabetic effect of *Nigella sativa* seed extract in skeletal muscle, adipocyte and liver cells. Diabetes, Obesity and Metabolism.2010; 12 (2): 148–157.
- [9] <http://blackcumin.blogspot.com/2011/04/black-seed-nigella-sativa-deserves-more.html> retrieved on 17/5/2011 at 11.40am.
- [10] Ali BH, Blunden. Pharmacological and toxicological properties of *Nigella sativa*. Phytotherapy Research. 2003; 17 (4): 299–305.
- [11] Khan MA, Ashfaq MK, Zuberi HS, Mahmood MS, Gilani AH. The in vivo antifungal activity of the aqueous extract from *Nigella sativa* seeds. Phytother Res.2003; 17: 183–186.
- [12] El-Fatraty HM. Isolation and structure assignment of an antimicrobial principle from the volatile oil of *Nigella sativa* L. seeds. Pharmazie.1975; 30 (2): 109-111.
- [13] Neveen, Noor A, Iman, Mourad M. Evaluation of Antioxidant Effect of *Nigella sativa* oil on Monosodium Glutamate-Induced Oxidative Stress in Rat Brain. Journal of American Science.2010; 6 (12): 13-19.
- [14] Midwood KS, Williams LV, and Schwarzbauer JE. Wound Healing. Int. J. Biochem Cell Biol.2004; 36 (6): 1031–1037.
- [15] Mansour M, Tornhamre, S. J Enzyme Inhib Med Chem.2004; 19: 431–436.
- [16] Senel O, Cetinkale O, Özbay G, Ahcioglu F, Bulan R. Ann plast surg.1997; 39: 516-523.
- [17] <http://curezone.com/forums/fm.asp?i=1454106> retrieved on 29/4/2011 at 8.08pm.
- [18] Nagi A, Haj AL. Characterization of *Nigella Sativa* L. Essential Oil-Loaded Solid Lipid Nanoparticles. American Journal of Pharmacology and Toxicology.2010; 5 (1): 52-57.
- [19] <http://nigella-sativa-research.com/nigella-sativa-users> retrieved on 29/4/2011 at 8.54pm.
- [20] <http://www.kalonji-oil.com/kalonji-oil.html> retrieved on 29/4/2011 at 8.56pm.
- [21] Mathur ML, Gaur J, Sharma R, Haldiya KR. Antidiabetic Properties of a Spice Plant *Nigella sativa*. J Endocrinol Metab.2011; 1 (1): 1-8.
- [22] Toama MA, El-Alfy TS, El-Fatraty HM. Antimicrobial Activity of the Volatile Oil of *Nigella sativa* Linnaeus Seeds. Antimicrobial Agents and Chemotherapy.1974; 17 (6): 225-226.
- [23] <http://flaxindia.blogspot.com/2011/02/nigella-sativa.html> retrieved on 29/4/2011 at 9.39pm.
- [24] <http://nigellasativa.org/> retrieved on 29/4/2011 at 10.5pm.
- [25] <http://nigella-sativa-research.com/nigella-sativa-research/> retrieved on 29/4/2011 at 8.48pm.
- [26] <http://www.ncbi.nlm.nih.gov/pubmed/19539020> retrieved on 29/4/2011 at 10.20pm.
- [27] Shenoy C, Patil MB, Kumar R, Patil S. Preliminary Phytochemical Investigation and Wound Healing Activity of *Allium cepa* Linn (LILIACEAE). International Journal of Pharmacy and Pharmaceutical Sciences.2009; 2 (2); 100-105.
- [28] Vinothapooshan G, Sundar K. Wound Healing Effect of Various Extracts of *Adhatoda vasica*. International Journal of Pharma and Bio Sciences.2010; 1 (4); 42-56
- [29] Patil SB, Ghodke DS, Magdum CS, Naikwade NS. Evaluation of Healing activity of Marketed Formulations on Excision wounds models in Albino Rats. International Journal of PharmTech Research.2009; 1 (3): 500-501.
- [30] Nayak BS, Maiya A, Kumar P. Influence of Helium-Neon Laser Photostimulation on Excision Wound Healing in Wistar Rats. On Line Journal of Biological Sciences.2007; 7 (2): 89-92.
- [31] Umachigi SP, Jayaveera KN, Kumar Ashok CK, Kumar GS, Vrushabendra swamy BM and Kumar Kishore DV. Studies on Wound Healing Properties of *Quercus infectoria*. Tropical Journal of Pharmaceutical Research. March 2008; 7 (1): 913-919.
- [32] <http://www.woundsearch.com/content/the-effects-topical-and-systemic-beta-gluca-administration-wound-healing-impaired-corticost> retrieved on 30/4/2011 at 1.59pm.
- [33] Jayasheelana V, Maheswari AP, Shanmugarathinam A, Puratchikody A. Wound healing potential of *Psammaphysilla purpurea*: A pharmacological and biochemical evaluation. Journal of Pharmacy Research.2010; 3 (6): 265-267.

- [34] Malviya N, Jain S. Wound Healing Activity of Aqueous Extract of *Radix paeoniae* Root. Acta Poloniae Pharmaceutica n Drug Research.2009; 66 (5): 543-547.
- [35] Jarrahi M, Vafaei AA. Effect of Topical Phenytoin Cream on Linear Incisional Wound Healing in Albino Rats. Daru.2004; 12 (4); 156.
- [36] Shetty BS, Udupa SL, Udupa AL, Somayaji SN. Effect of *Centella asiatica* L (Umbelliferae) on Normal and Dexamethasone-Suppressed Wound Healing in Wistar Albino Rats. J Ethnopharmacol. 2002 Dec; 83 (3): 193-199.
- [37] Roy K., Shivakumar H., Sarkar S. Wound Healing Potential of Leaf Extracts of *Ficus Religiosa* on Wistar albino strain rats. International Journal of PharmTech Research.2009; 1 (3): 506-508.
- [38] Deshmukh PT, Fernandes J, Atul A, Toppo E. Wound healing activity of *Calotropis gigantea* root bark in rats. J Ethnopharmacol. 2009; 125 (1): 178-181.
- [39] Kumari M, Eesha BR, Amberkar M, Babu S, Rajshekar and Kumar N. Wound healing activity of aqueous extract of *Crotalaria verrucosa* in Wistar albino rats,. Asian Pacific Journal of Tropical Medicine.2010; 3 (10): 783-787.
- [40] <http://cat.inist.fr/?amodele=afficheN&Cpsidt=17086953> retrived on 30/4/2011 at 10.22pm.
- [41] Shetty S, Udupa S, Udupa LA, Vollala RV. Wound Healing Activities of Bark Extract of *Jatropha curcas* Linn in Albino Rats. Saudi Med J.2006; 27 (10): 1473-1476.
- [42] Sharma K, Sing A, Sharma U, Pawan M, Dr. Kumar UA, Rai D. Wound Healing Activity of *Kigelia pinnata* Bark Extract. Research Article. J Ethnopharmacol. 2003; 53 (3): 123-129.
- [43] Ramesh HA, Mohammad A, Malay B, Mohammed A. Wound healing activity of human urine in rats. Research Journal of Pharmaceutical, Biological and Chemical Sciences.2010; 1 (3): 750-758.
- [44] Hassan KA, Deogratius O, Nyafuono JF, Francis O, Engeu OP. Wound healing potential of the ethanolic extracts of *Bidens pilosa* and *Ocimum suave*. African Journal of Pharmacy and Pharmacology.2011; 5 (2): 132-136.
- [45] Priya KS, Gnanamani A, Radhakrishnan N, Babu M. Healing potential of *Datura alba* on burn wounds in albino rats. J Ethnopharmacol. 2002; 83 (3): 193-199.
- [46] <http://www.greenmedinfo.com/article/chamomile-extract-acclerates-burn-wound-healing-rats-o> retrived on 30/4/2011 at 11.06pm.
- [47] Nithya V, Dr. Brinda P and Anand KV. Wound Healing Activity of *Leonotis Nepetaefolia* R. br. in Wistar Albino Rats. Asian Journal of Pharmaceutical and Clinical Research.2011; 4 (2): 23-26.
- [48] <http://www.scialert.net/fulltext/?doi=ajbs.2010.18.27&org=12> retrived on 30/4/2011 at 11.56pm.
- [49] Gurfinkel R, Palivatkel-Naim M, Gleisinger R, Rosenberg L, Singer AJ. Comparison of purified olive oil and silver sulfadiazine in the treatment of partial thickness porcine burns. Am J Emerg Med. 2010.
- [50] Bhaskar HN, Udupa SL and Udupa AL. Effect of Nifedipine and Amlodipine on Wound Healing in Rats. Indian J Physiol Pharmacol.2004; 48 (1): 111-114.
- [51] Sheeba M, Emmanuel S, Revathi K, Ignacimuthu S. Wound Healing Activity of *Cassia occidentalis* L. in Albino Wistar Rats. International Journal of Integative Biology.2009; 8 (1): 1-6.
- [52] Rajput R, Sagar VS, Adiga S, Ramyasudha. Effect of *Punica Granatum* Peel Extract on Burn Wound Healing in Albino Wistar Rats. International Journal of Applied Biology and Pharmaceutical Technology.2011; 2 (1): 353-357.
- [53] Williams TC, Frohman LA. Potential therapeutic indication for growth hormone releasing hormone in the condition other than growth retardation. Pharmacotherapy.1986; 311-318.
- [54] Rao CM, Ghosh A. Does metronidazole reduce lipid peroxidation in burn injuries? Indian J Pharmacol.1997; 29: 29