

Crouzon Syndrome: A Rare Case Report

Poornima Tripathi, Sonal Gupta, Sakshi Patel

Abstract: *Crouzon syndrome also called craniofacial dysostosis is an autosomal dominant disorder characterized by premature closure of cranial sutures, midfacial hypoplasia, and orbital defects. Herein we report a case of this rare entity with Ectomorphic body shape, Exophthalmoses eyes, Flat broad nasal bridge, and low set ears.*

Keywords: Craniofacial dysostosis, crouzon syndrome, copper beaten appearance, exophthalmos

1. Introduction

Cranial skeletogenesis is unique. Cranial bones and cartilages are derived from neural crests and mesoderms and evolved greatly throughout evolution. Despite their rarity, cranial malformations can compromise a person's mental well-being as well as function. Crouzon's syndrome is an autosomal dominant genetic disorder known as a branchial arch syndrome.

As described by a French neurosurgeon Octave Crouzon in 1912,³ it is a rare genetic disorder, this syndrome specifically affects the first branchial (or pharyngeal) arch, which is the precursor of the maxilla and mandible. Since the branchial arches are important developmental features in a growing embryo, disturbances in their development create lasting and widespread effects. This disease is autosomal dominant with complete penetrance and variable expression or can be caused by mutations.²

The disease is characterized by premature synostosis of coronal and sagittal sutures which begins in the first year of life. It can be transmitted as an autosomal dominant genetic condition. This is caused by mutation in the *fibroblast growth factor receptor 2* (FGFR2) genes.⁴ Once the sutures become closed, growth potential to those sutures is restricted. However, multiple sutural synostoses frequently extend to premature fusion of skull base causing midfacial hypoplasia, shallow orbit, maxillary hypoplasia, and occasional upper airway obstruction.⁵ Airway distress is a well described characteristic feature of this syndrome, and both upper and lower airway obstruction may be present. Obstructions in the upper airway have been reported secondary to septal deviation, midnasal and choanal abnormalities, and nasopharyngeal narrowing. Oral manifestations include mandibular prognathism, overcrowding of upper teeth, and V-shaped maxillary dental arch.^[3] Narrow, high, or cleft palate and bifid uvula can also be seen. Occasional oligodontia, macrodontia, peg-shaped, and widely spaced teeth have also been reported.

Crouzon's syndrome occurs in approximately 1 in 25,000 births worldwide.⁶ Prevalence in the United States is 1 per 60,000.⁷ Crouzon syndrome makes up approximately 4.8% of all cases of craniosynostoses.⁸ No known race or sex predilection exists.⁵

2. Case Report

A male child of 7 years old with Crouzon's syndrome reported to the Department of Pediatric and Preventive

Dentistry K. D dental college and hospital; Mathura. He was accompanied by his father who reported the chief complaint of pain in his left and right back tooth region since 8 - 10 months. He experienced dull aching pain in his mandibular posterior right and left tooth region. The pain usually aggravated on eating and stopped once the patient stopped eating. He also complained of mal-aligned teeth IRT to his anterior maxillary tooth region. Patient's father gave the dental history of surgery for his cleft lip when he was 5 months old. Patient again underwent surgery for his cleft palate when he was 6 years old. Patient had difficulty in speaking and could not utter a word until his last surgery after which he was able to speak a little and is under therapy for the same.

On Examination

Extra-oral examination revealed Ectomorphic body shape, brachycephaly shaped head, with dolichofacial growth pattern, and convex facial profile. The presence of Exophthalmoses eyes, Flat broad nasal bridge, low set ears which is the characteristics of the Crouzon disease triad, can be observed. (Figure 1)

Intra-Oral Examination with no Abnormality Detected in Palate, Floor of the mouth, Tongue, Salivary Glands, Lymph nodes. Patient is in early mixed dentition, with all primary teeth in the maxillary and mandibular arch. Chronology of eruption and exfoliation status was normal for the patient's age. Dental caries 75, Root stumps IRT 74, 84 Grossly decayed 85, Disto-labial rotation IRT 11, Mesio-labial rotation IRT 21 anterior crowding. (Figure 2, 3) The orthopantomograph (OPG) was taken for the patient has confirmed these findings. The OPG also showed the presence of all succedaneous teeth which looked healthy. (Figure 4)

Investigations

Lateral skull radiograph revealed shallow orbits, depressed nasal bridge, copper beaten skull, asymmetrical calvarial thickening. (Figure 5) (Figure 6)

The panoramic image showed decayed 75, 85; root stumps IRT 74, 84. All the permanent tooth buds were as shown in the image.

Differential Diagnosis -

Apert syndrome
Carpenter syndrome

Volume 11 Issue 10, October 2022

www.ijsr.net

Licensed Under Creative Commons Attribution CC BY

Pfeiffer syndrome
 Seatre - Chotzen syndrome
 Jackson Weiss syndrome

Final Diagnosis: Crouzon syndrome with acanthosis nigricans

Treatment Plan

A through plaque control regimen was followed. It was regulated by providing oral prophylaxis at regular intervals. Dentinal caries was removed for 75 and pulpectomy for 85 was performed followed by permanent GIC restoration for both. Extraction was done under LA for 84 and 74. (Figure 7) Proper oral hygiene instructions and motivation of the patient was done on each visit. After one month the patient was recalled and evaluated. Further it was decided to follow up the patient every month to evaluate plaque control and dental caries.

3. Discussion

Craniofacial abnormalities are often present at birth and may progress with time. Crouzon's syndrome is an autosomal - dominant disorder with complete penetrance and variable expressivity, but about one third of the cases does arise spontaneously. The incidence of Crouzon's syndrome is 3: 1 among males and females.^{2, 10} With the advent of molecular technology, the gene has been identified at chromosome 10q 25.3 - q26, and more than 30 different mutations have been documented in different families.^{2, 10}

A child with Crouzon's syndrome may display a mild presentation with subtle midface deficiency or a severe presentation with multiple cranial sutures fused and marked midface and eye defects. This condition can lead to acute respiratory distress and mental retardation is rare in these children.^{3, 11} Increased intracranial pressure can lead to optic atrophy, which can produce blindness if the condition is not treated. Early diagnosis and management of Crouzon's disease are key to a successful outcome. During the first year of life, the synostotic sutures of the skull are usually released to allow adequate cranial volume and optimal brain development. If necessary, mid face advancement and jaw surgery can be done to provide adequate orbital volume and reduce the exophthalmoses to correct the occlusion to an appropriate functional position and to create a more natural appearance. Prognosis depends on malformation severity.^{6, 11} Mandibular prognathism, overcrowding of upper teeth, and a V - shaped maxillary dental arch are some of the intraoral symptoms.³ Narrow, high, or cleft palates and bifid uvula are also common. Occasional oligodontia, macrodontia, peg - shaped and widely spaced teeth have been reported.^{3, 5} Unfortunately, our patient never sought treatment for this disorder. His oral hygiene was compromised owing to the lack of awareness on the part of the parents. A proper oral rehabilitation was done followed by oral prophylaxis. We expect him to live a normal and healthy life after all his treatment is completed.

4. Conclusion

The dental team needs to understand these abnormalities in order to make the appropriate referrals to make sure the patient receives the best treatment available. Pediatric dentists should be an integral part of the multidisciplinary team.

Declaration of patients consent

The authors certify that they have obtained all appropriate patient consent forms. In the form the patient (s) has given his consent for their images and other clinical information to be reported in the journal.

References

- [1] Helms JA, Schneider RA. Cranial skeletal biology. *Nature*.2003; 423: 326–31.
- [2] Fogh - Andersen P. Craniofacial dysostosis (Crouzon's disease) as a dominant hereditary affection. *Nord Med*.1943; 18: 993–6.
- [3] Crouzon LE. Dysostose cranio - facialehereditaire. *Bulletin de la Societe des Medecins des Hopitaux de Paris*.1912; 33: 545–55.
- [4] Fries PD, Katowitz JA. Congenital craniofacial anomalies of ophthalmic importance. *SurvOphthalmol*.1990; 35: 87–119.
- [5] Hlongwa P. Early orthodontic management of Crouzon Syndrome: A case report. *J Maxillofac Oral Surg*.2009; 8: 74–6. Cohen MM., Jr *Craniosynostosis update 1987*. *Am J Med Genet Suppl*.1988; 4: 99–148.
- [6] Cohen MM, Jr, Kreiborg S. Birth prevalence studies of the Crouzon syndrome: Comparison of direct and indirect methods. *Clin Genet*.1992; 41: 12–
- [7] Gray TL, Casey T, Selva D, Anderson PJ, David DJ. Ophthalmic sequelae of Crouzon syndrome. *Ophthalmology*.2005; 112: 1129–34.
- [8] Regezi JA, Sciubba JJ.4th ed. Philadelphia: W. B. Saunders co; 1999. Oral pathology–Clinical pathologic correlations; pp.477–8.
- [9] Gorlin RJ, Cohen MM, Levin LS.3rd ed. Oxford: Oxford University Press; 1990. Syndromes of the head and neck; pp.516–26.
- [10] Jarund M, Lauritzen C. Craniofacial dysostosis: Airway obstruction and craniofacial surgery. *Scand J PlastReconstrSurg Hand Surg*.1996; 30: 275–9.



Figure 1: Facial Profile Showing Exophthalmos Eyes, Flat Broad Nasal

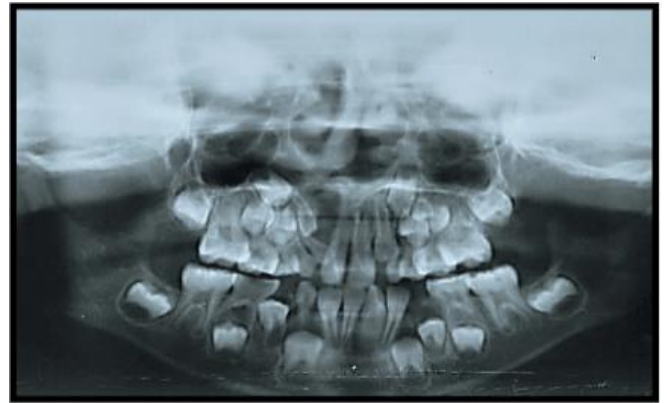


Figure 3: Panoramic Image Showing Decayed 75,85. Root Stumps IRT 74,84. All Permanent Tooth Buds Present

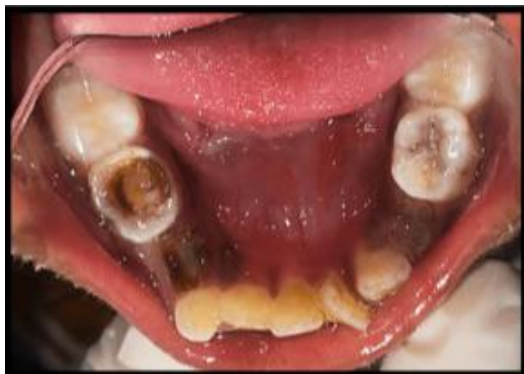
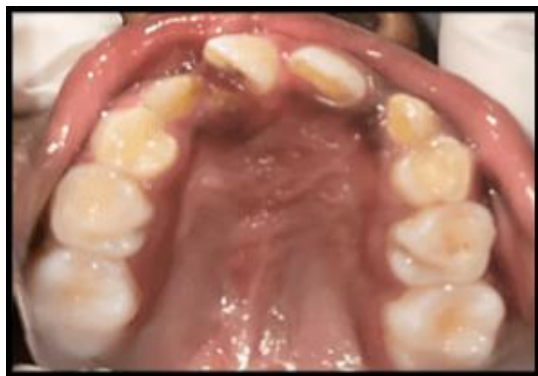
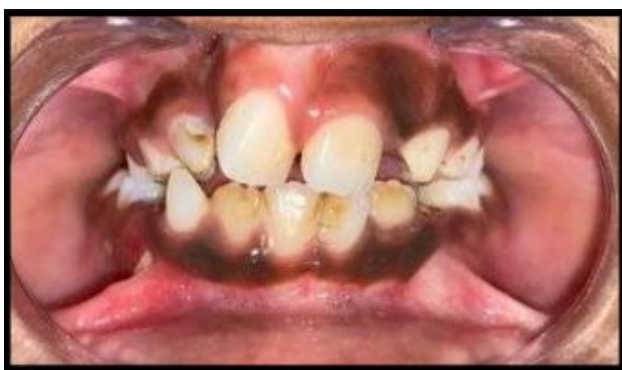Figure 2: Intra Oral Photographs Showing Dentinal Caries IRT 75, Root Stumps IRT 74,84 and Grossly Decayed IRT 85

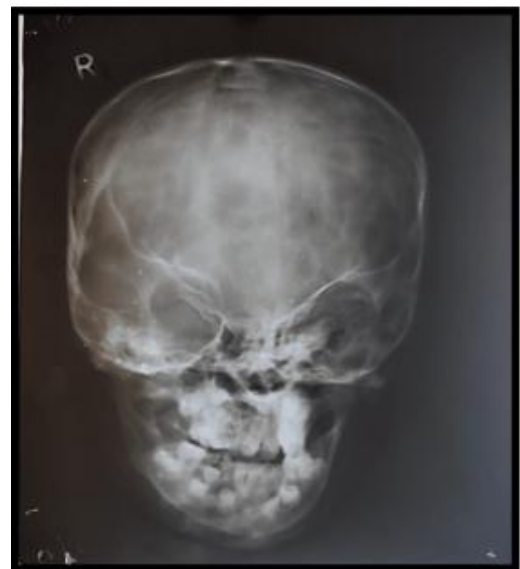
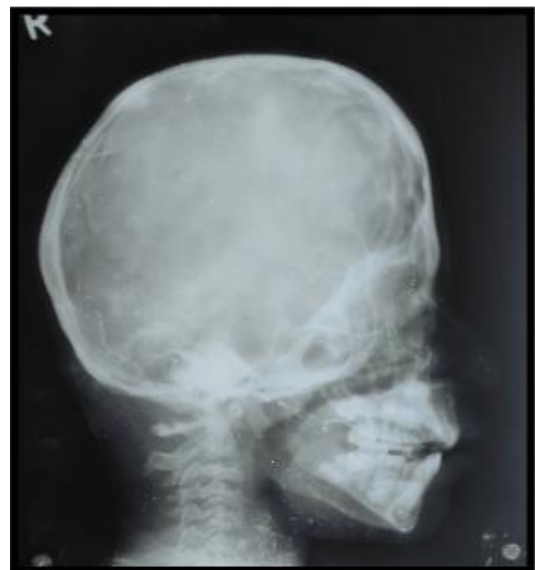
Figure 4: Lateral Skull Radiograph & Pa View Revealed Shallow Orbits, Depressed Nasal Bridge, Copper Beaten Appearance, Calvarial Thickening

