

# A Rare Case Desmoid Tumour of Appendix Mimicking a Gastrointestinal Stromal Tumor

Ketan Borkhataria, Bhargav Shingala

**Abstract:** A 48 year-old male patient with complaint of an abdominal pain and a palpable abdominal mass came to our general surgery outpatient clinic. The computed tomography revealed a well-circumscribed solid mass, approximately 12 cm in diameter, which is thought to be a gastrointestinal stromal tumor originating from the cecum. The colonoscopy detected an external pressure on the cecum. No remarkable feature was noted in the patient's history. Right hemicolectomy was performed. Pathological examination revealed a collagen-rich hypocellular mesenchymal tumor originating from the appendiceal wall, which was negatively stained with CD117 immunohistochemical antibodies. The histopathological diagnosis revealed a desmoid tumor (fibromatous lesions). The patient was discharged on postoperative day 6 and was transferred to the oncology department.

**Keywords:** Appendix tumor, desmoid tumor, intraperitoneal fibromatosis, intraabdominal mass

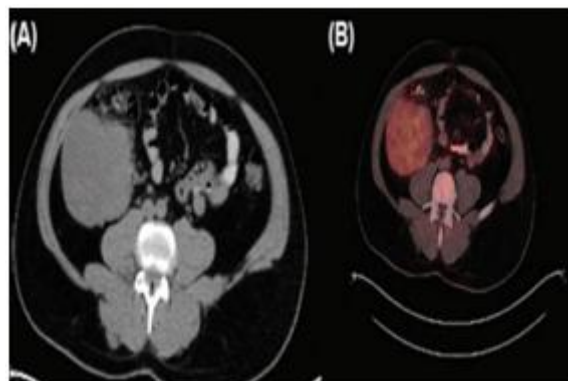
## 1.Introduction

Desmoid tumors are fibromatous masses with an incidence of 2-4/1, 000, 000 per year, which are histologically composed of spindle cells abundantly surrounded by collagen. (1, 2) Surrounding tissue invasion and after resection recurrence is seen but does not metastasize. (1, 3) Desmoid tumors are seen in different parts of the body; however, intraperitoneal desmoid tumors are very rare. 30% of the intraperitoneal desmoid tumors occur sporadically in the mesentery root or pelvis. These tumors develop in patients with familial adenomatous polyposis (FAP), Gardner syndrome, and adenomatous polyposis coli (APC) mutation. 1, 2, 4 Studies reported that desmoid tumors developed following gastrointestinal stromal tumors (GISTs) resection. Four Other more common intraperitoneal masses should be considered in the differential diagnosis before desmoid tumors in patients with palpable mass and compression symptoms. Surgery is primarily preferred for intraperitoneal desmoid tumor treatment; however, resection is impossible in some cases. (5, 6) Here patient Presented is a 48-year old male patient who underwent right hemicolectomy with a preliminary diagnosis of GIST and had a pathological diagnosis of an appendiceal desmoid tumor.

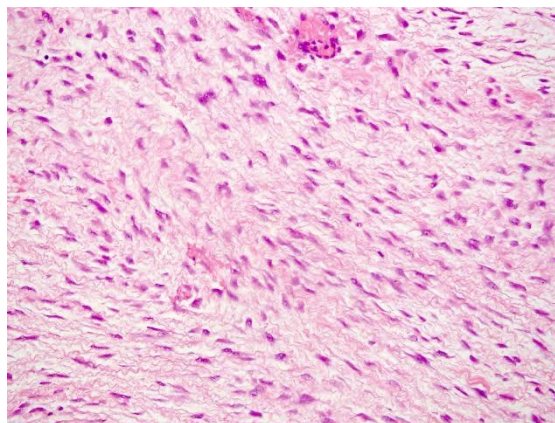
## 2.Case Report

A 48-year-old male patient complained of a right lower quadrant mass. The intravenous contrast-enhanced abdominal computed tomography (CT) revealed a well circumscribed mass, 12 cm in diameter, with smooth borders originating from the cecum. The patient's tumor markers were within normal limits. A colonoscopy was performed and no feature was observed in the cecum other than the external compression. A positron emission tomography (PET) /CT was performed with Fluorine-18 Fluorodeoxyglucose (F18-FDG). The Maximum standard unit value of the mass was 6.29. (Figure 1). The patient applied to our clinic for surgery and was operated with a pre-diagnosis of GIST of cecal origin. During the surgery, the mass was observed to be localized in the ileocecal region, which caused traction to the right ureter. Right hemicolectomy and ileo-transverse anastomosis were performed. Pathological macroscopic examination

revealed a mass originating from the appendiceal wall. Microscopic interpretation revealed a hypocellular mesenchymal collagen-rich tumor. The tumor was negative with CD117, CD34, desmin, calretinin (-), and S-100, and positive with cyclin D-1,  $\beta$ -catenin, and androgen receptor, immunohistochemically. Ki-67 proliferation index of the tumor was 3%-4%. The tumor was diagnosed as fibromatosis (desmoid tumor) (Figure 2). The patient was discharged without any complications on postoperative day 6. A 46-year-old male patient complained of a right lower quadrant mass. The intravenous contrast-enhanced abdominal computed tomography (CT) revealed a well circumscribed mass, 12 cm in.



**Figure 1:** a) A well-circumscribed solid mass originating from the cecum on abdominal CT (red arrow), b) F18-FDG involvement determined by PET/CT.



**Figure 2:** Spindle cell tumor originating from the appendiceal wall suggesting of fibromatosis.

### 3. Discussion

Desmoid tumor is a rare mesenteric neoplasm with fibromatous features. (1) It is a fibroblastic / myofibroblastic tumor, originating from the musculoaponeurotic structures, arising in deep soft tissues. (1, 7) Desmoid tumors can be observed in different parts of the body. (1, 8) Gardner syndrome, FAP, APC, unopposed estrogen, and previous surgeries are known risk factors. (6) Basic histological features of desmoid tumors are spindle cells and fibroblasts surrounded by abundant collagen. Its morphological features sometimes mimic GIST; however, it does not immunohistochemically express either CD117 or DOG-1. 1, 3, 9 Extra-abdominal masses are detected earlier; however, desmoid tumors located intra-abdominally are later presented. (5) Intraperitoneal desmoid tumors without specific findings are usually detected due to signs of pressure on adjacent organs and as palpable masses. In our case, the patient's only complaint was a palpable mass and pain abdomen at the time of admission. Desmoid tumors are the most common mesenteric primary tumor but are very rare in the gastrointestinal system. Cases located in the pancreas, stomach, small intestine, colon, and appendix with different findings were reported in the literature. (1, 4, 10) Intraperitoneal desmoid tumors are often confused with GIST before resection, and definitive diagnosis can only be made with tissue biopsies. (3) Desmoid tumors can mimic local recurrence after GIST resection. (4) Desmoid tumors of the appendix are very rare and only a few cases were reported. These tumors, seen as masses in the cecal region, rarely cause acute appendicitis by occluding the appendiceal lumen and are sometimes confused as periappendicular abscess. (11, 12) GIST is often suspected since they present as well-circumscribed solid masses originating from the cecum in preoperative evaluations. (3, 4) In our case, a similar pre-diagnosis was considered and the decision for surgery was made. CT and magnetic resonance imaging are the preferred diagnostic imaging methods. (1, 3) Endoscopy demonstrates compression from the outside or protrusion into the lumen due to the mass effect. Percutaneous tissue biopsy is performed for differential diagnosis in patients with unresectable tumors. PET/CT is rarely used to diagnose desmoid tumors and is generally recommended in patient follow-ups for recurrence. (6) In our case, F18-FDG involvement was determined by PET/CT. A multidisciplinary approach is very important in desmoid tumor treatment originating from the gastrointestinal system. Active follow-up together with chemotherapy and radiotherapy (RT) provides a 5-year survival rate of 50% in desmoid tumors. (6) Resection is the first choice of treatment for intraperitoneal desmoid tumors. (1, 2, 4) Resection with negative surgical margins should be considered due to local recurrence possibility. The recurrence rates in intraperitoneal tumors are relatively low although 20% recurrence has been reported in desmoid tumors with negative surgical margins. (6) Chemotherapy is considered when tumor removal is impossible and as recurrence prevention after resection. (2, 6) The use of RT together with surgical treatment was reported to be more successful than surgical treatment alone. In our case, a right hemicolectomy was performed

due to the presence of a cecum-derived tumoral mass. The patient was transferred to the oncology center for chemotherapy and RT. In conclusion, desmoid tumors are rarely seen in the entire gastrointestinal system, including the appendix. Multidisciplinary treatment should be adopted and patients should be closely followed. These tumors mimicking GIST have high recurrence rates. Therefore, care should be taken in surgical treatment and negative surgical resection margins should be provided to prevent a recurrence.

### References

- [1] Shinagare AB, Ramaiya NH, Jagannathan JP, Krajewski KM, Giardino AA, Butrynski JE, Raut CP. A to Z of desmoid tumors. *AJR Am J Roentgenol* 2011; 197: W1008-1014.
- [2] Napolitano A, Mazzocca A, Spalato Ceruso M, Minelli A, Baldo F, Badalamenti G, Silletta M, Santini D, Tonini G, Incorvaia L, Vincenzi B. Recent advances in desmoid tumor therapy. *Cancers (Basel)* 2020; 12: 2135.
- [3] Wong SL. Diagnosis and management of desmoid tumors and fibrosarcoma. *J Surg Oncol* 2008; 97: 554-558.
- [4] Kim JH, Ryu MH, Park YS, Kim HJ, Park H, Kang YK. Intra-abdominal desmoid tumors mimicking gastrointestinal stromal tumors-8 cases: a case report. *World J Gastroenterol* 2019; 25: 2010-2018.
- [5] Bertagnolli MM, Morgan JA, Fletcher CD, Raut CP, Dileo P, Gill RR, Demetri GD, George S. Multimodality treatment of mesenteric desmoid tumours. *Eur J Cancer* 2008; 44: 2404-2410.
- [6] Desmoid Tumor Working Group. The management of desmoid tumours: a joint global consensus-based guideline approach for adult and paediatric patients. *Eur J Cancer* 2020; 127: 96-107.
- [7] Zreik RT, Fritchie KJ. Morphologic Spectrum of Desmoid-Type Fibromatosis. *Am J Clin Pathol* 2016; 145: 332-340.
- [8] Keskin M, Üçüncü MZ, Memişoğlu E, Bayraktar A, Balık E, Bulut MT. Our experience with desmoid tumors. *Turk J Colorectal Dis* 2016; 26: 90-97.
- [9] Chu Y, Guo Q, Wu D. Mesenteric fibromatosis after resection for gastrointestinal stromal tumor of stomach: A case report. *Medicine (Baltimore)* 2017; 96: e8792.
- [10] Asenov Y, Genadiev S, Timev A, Panaiotova J, Hadjiiska V, Veselin T, Sedloev T. Ruptured desmoid tumor imitating acute appendicitis-a rare reason for an emergency surgery. *BMC Surg* 2019; 19: 194.
- [11] Bravo-Taxa M, Vásquez-Vásquez CL, López-Blanco A, Taxa-Rojas L. Fibromatosis tipo desmoide de apéndice cecal: reporte de caso inusual y revisión de la literatura [Appendicular desmoid tumor: unusual case and review of the literature]. *Rev Gastroenterol Peru* 2020; 40: 193-197. (Spanish)
- [12] Peled Z, Linder R, Gilshtein H, Kakiashvili E, Kluger Y. Cecal fibromatosis (desmoid tumor) mimicking periappendicular abscess: a case report. *Case Rep Oncol* 2012; 5: 511-514

## Author Profiles

**Dr Ketan Borkhataria**, (MBBS, DNB Surgery), Senior Resident, Pacific Medical college, Udaipur, Rajasthan, India

**Dr Bhargav Shingala**, (MBBS, DNB Surgery), Senior Resident, Shantabaa Medical college, Amreli, Gujarat, India