

# Indirect Esthetic Restoration - A Review

Suditi Pal<sup>1</sup>, Savitha P. N.<sup>2</sup>, Archana S.<sup>3</sup>, P. Jahnavi Sai Sri<sup>4</sup>

<sup>1</sup>General Practitioner

<sup>2</sup>Reader Department of Prosthodontics, The Oxford Dental College, Bengaluru, Karnataka, India

<sup>3</sup>Reader Department of Conservative Dentistry, The Oxford Dental College, Bengaluru, Karnataka, India

<sup>4</sup>Post Graduate Student, Department of Prosthodontics, The Oxford Dental College, Bengaluru, Karnataka, India

**Abstract:** *Aesthetic appearance is very crucial in modern dentistry. Patients are attracted to a restoration that matches the color of their natural teeth. Hence, an esthetic restorative material must simulate the natural tooth in color, translucence, and texture, yet must have adequate strength and wear characteristics, good marginal adaptation and sealing, insolubility, and biocompatibility. These materials must also remain color stable and maintain external tooth morphology to provide a lasting esthetic restoration. Options for tooth-colored restorations include ceramics and direct and indirect composite based materials. The success of the treatment depends on a number of factors. This article reviews the case selection, preparation designs, material selection of various indirect restorative materials.*

**Keywords:** veneers, composite, resin bonding, inlays, onlay, inlay, esthetic

## 1. Introduction

Aesthetic appearance is very crucial in modern dentistry. Patients are attracted to a restoration that matches the color of their natural teeth. Hence, an esthetic restorative material must simulate the natural tooth in color, translucence, and texture, yet must have adequate strength and wear characteristics, good marginal adaptation and sealing, insolubility, and biocompatibility. These materials must also remain color stable and maintain external tooth morphology to provide a lasting esthetic restoration.

Presently, materials available for esthetic restoration are:

- a) Direct esthetic restorative material:
  - Direct composite resins.
- b) Indirect esthetic restorative materials:
  - Indirect resin composite.
  - Dental ceramics.

The ideal restorative material should fulfil the following basic functions:

- 1) Permit the most conservative approach to cavity preparation
- 2) Optimally restore the morphology and the original mechanical resistance of the tooth to allow it to resume proper function
- 3) Ensure external and internal adaptation and seal of the restoration, to prevent recurrent decay, pulpal injuries, and dentinal sensitivity
- 4) Be biologically compatible with the underlying vital substrate
- 5) Provide satisfactory longevity.

Direct composite resins are popular esthetic restorative materials, for advantages like having conservative tooth preparation, insulative, bonded to tooth structure, resulting in good retention, and being repairable. Yet, it has its disadvantages.

However, teeth can also be restored using indirect techniques, in which restorations are fabricated outside of

the mouth. Tooth coloured indirect systems include laboratory processed composites or ceramics such as porcelain fired on refractory dies or hot pressed glasses. In addition, computer aided design/ computer assisted manufacturing system is currently available and is used to fabricate ceramic restorations.

The advantages of indirect tooth colored restorations over direct are improved physical properties, Variety of materials and techniques, Wear resistance, Reduced polymerization shrinkage, Ability to strengthen remaining tooth structure, More precise control of contours and contacts, Biocompatibility and good tissue response and Increased auxiliary support<sup>1</sup>.

**Material and Technique Selection:** Selecting the appropriate technique and material is very important when patients demand an esthetically pleasing restorative material; dentists must follow basic guidelines for making recommendations to patients<sup>2</sup>.

- First and foremost, the long-term prognosis of the tooth and the restoration must take precedence over any other factor.
- Second, the restorative material chosen should permit the most conservative preparation possible to accomplish the restoration.
- Third, when large defective amalgams or extensive decay dictate more aggressive cavity designs, it is imperative that the clinician assess the opposing occlusion and determine the point of centric contact and the width of the antagonistic cusp, so that the appropriate restorative material can be determined.

### Laboratory Processed Indirect Resins<sup>2</sup>.

Clinically, ceramic restorations can be extremely brittle; they cannot be reliably repaired in the mouth, are highly rigid, and distribute occlusal stress to the underlying tooth structure; they are nearly impossible to polish intraorally, are often more expensive to fabricate compared to their composite counterparts, and show a high propensity to abrade the opposing dentition. In an effort to overcome these

significant disadvantages, manufacturers have introduced numerous indirectly processed resin restorations over the past 20 years.

<b>First generation</b>	<ul style="list-style-type: none"> <li>Dentacolor (Kulzer, Irvine, California),</li> <li>SR Isosit N (Ivoclar North America Inc., Amherst, New York), and</li> <li>Visio-Gem (ESPE, Norristown, Pennsylvania) were produced.</li> </ul>	All these were microfill resin systems that explored a variety of curing mechanisms but possessed low flexural strength and wear characteristics, because of the low filler content and high percentage of exposed resin.
<b>Second generation</b>	<ul style="list-style-type: none"> <li>Concept (Ivoclar),</li> <li>Herculite Lab (Kerr/Lybron, Orange, California),</li> <li>Tetric Lab (Vivadent),</li> <li>Conquest (Jenerid/Pentron, Wallingford, Connecticut),</li> <li>ArtGlass (Kulzer), Targis (Ivoclar),</li> <li>Sculpture (Jeneric/Pentron),</li> <li>BelleGlass HP (Belle de St. Claire Kerr, Orange, California),</li> <li>Cristobal (Dentsply/ Ceramco, York, Pennsylvania)</li> </ul>	<p>These are characterized by an increase in filler loading, increased flexural strength, and resistance to wear similar to enamel.</p> <p>With the exception of Concept (Ivoclar), which is a microfill, all of the second-generation materials are variations of submicron hybrid resin systems.</p>

<b>Coltene Inlay System<sup>3</sup></b>	The Coltene Inlay system (Colténe AG) was first designed for direct/indirect application.
<b>Cristobal<sup>2</sup></b>	Cristobal (Dentsply Ceramco, Inc.) is a patented bioglass polymer material designed for fixed prosthetic restorations, including single crowns with or without metal support.
<b>TrueVitality<sup>2</sup></b>	True vitality (Den-Mat, Inc.) is a hybrid composite resin with three curing modes: heat curing, self-curing and light curing.
<b>Belle Glass<sup>3,4</sup></b>	Belleglass consists of mixture of aliphatic and urethane dimethacrylate resins, it and Concept are the only heat and pressure cured indirect composite system.
<b>Art glass<sup>3,4</sup></b>	Artglass isopolyglass, a new class of indirect restorative material with improved resin and filler technology and was designed an alternative to porcelain
<b>Sculpture/ FibreKor (Jeneric/ Pentron)<sup>3,4</sup></b>	This restorative system is composed of a PCDMA resin and unique glass filler with promising wear characteristics that is reinforced with an advanced glass fibre.
<b>Targis/Vectris<sup>4</sup></b>	Targis is a ceromer restorative material and vectris is a fiber glass reinforced composite similar to fibreKor.

Advantages of using these materials over their porcelain counterparts include the following<sup>2</sup>:

- They have lower elastic moduli and are less brittle.
- They easily and reliably can be repaired in the mouth.
- They are less rigid and transmit less functional stress to the underlying tooth structure.
- They are easily adjusted and polished intraorally.
- They are simpler to produce and less expensive than most porcelain restorations, and are less likely to abrade the opposing dentition.

Feldspar, Quartz and Clay. They only differ in the relative proportion of each component and on the firing procedure. Dental ceramic: An inorganic compound with nonmetallic properties typically consisting of oxygen and one or more metallic or semi metallic elements that is formulated to produce the whole or part of a ceramic-based dental prosthesis<sup>5</sup>.

These materials can be defined by their inherent properties; they form hard, stiff, and brittle materials due to the nature of their inter-atomic bonding, which is ionic and covalent.

**Dental Ceramics**

Ceramics encompass a group of materials from earthenware to porcelain. They have three common ingredients namely

<i>Indications</i>	<i>Properties</i>	<i>Composition</i>
<ul style="list-style-type: none"> <li>Aesthetic alternative for discolored teeth.</li> <li>Badly or grossly carious teeth.</li> <li>Traumatic fracture of incisal angles or cusps of teeth.</li> <li>Congenital abnormalities.</li> <li>Veneers.</li> <li>Inlays or onlays.</li> <li>Abutment retainers.</li> <li>Denture as tooth material.</li> <li>Splinting of mobile teeth with metal backing.</li> </ul>	<ul style="list-style-type: none"> <li>Compressive Strength - 170MPa</li> <li>Flexural Strength - 50-75 Mpa</li> <li>Tensile Strength - 25 Mpa</li> <li>Elastic Modulus - 69-70 Gpa</li> <li>Thermal Co-efficient of expansion - 12-14 X 10<sup>-6</sup> /°C</li> <li>Surface Hardness - 460 KHN (enamel 343 KHN)</li> </ul>	<ul style="list-style-type: none"> <li>Feldspar: 60-80% (Basic glass former)</li> <li>Kaolin: 3-5% (Binder)</li> <li>Quartz: 15-25% (Filler)</li> <li>Alumina: 8-20% (Glass former)</li> <li>Boric Oxide: 2-7% (Glass former and flux)</li> <li>Oxides of Na, K &amp; Ca: 9-15% Fluxes (Glass modifiers)</li> <li>Metallic pigments: &lt; 1% (Colour Matching)</li> </ul>

At a microstructural level, we can define ceramics by the nature of their composition of glass-to-crystalline ratio<sup>6</sup>.

There can be infinite variability of the microstructures of materials, but they can be broken down into four basic compositional categories, with a few subgroups:

- Composition Category 1-Glass based systems (mainly silica)

- Composition Category 2-Glass based systems (mainly silica) with fillers, usually crystalline (typically leucite or, more recently, lithium disilicate)
- Composition Category 3-Crystalline- Based systems with glass fillers (mainly alumina)
- Composition Category 4-Polycrystalline solids (alumina and zirconia)

According to Processing Technique: They are classified as

- 1) Conventional (powder-slurry) ceramics
  - Duceram (Degussa Corp)
  - Optec HSP(Jeneric/Pentron)
- 2) Castable porcelain
  - DICOR (Dentsply)
  - Cera Pearl
- 3) Machined porcelain
  - Cerec Vitablocs Mark I and II (Vident)
  - Celay Blocks (Vident)
  - DICOR MGC (Dentsply)
- 4) Infiltrated porcelain
  - In-Ceram (vident)
- 5) Pressed porcelain –
  - IPS Empress (Ivoclar)
  - Optec Pressable ceramic (Jeneric/Pentron)

### Clinical Recommendations<sup>7</sup>

- Leucite and feldspathic glass ceramics are indicated for onlays, three quarter crowns, and veneers, but their strength limits their use to complete coverage crowns in the anterior segment, only.
- Lithium-disilicate glass ceramics can perform successfully in the posterior segment for single crowns and 3-unit FPDs in the anterior area.
- Glass-infiltrated alumina cores can be considered for single-unit restorations and anterior FPDP applications, with the exception of In-Ceram Spinell, which is only recommended for anterior crowns.
- Zirconia-modified alumina is indicated for posterior crowns and FPDs, while densely sintered alumina is indicated for veneers, crowns, and anterior FPDs.
- Zirconia has superior mechanical properties as a core material for posterior crowns and FPDs, implant abutments, and implant-supported restorations. The stronger ceramic core materials can be rather opaque and this may limit their application when a high degree of translucency is required.

### Anterior Veneers

A veneer is a layer of tooth-colored material that is applied to a tooth for esthetically restoring localized or generalized defects or intrinsic discoloration. Constructing a veneer and bonding it to an etched tooth structure has been referred to as laminating. It can be a Partial veneer or Full veneer.

### A new classification of ceramic veneer based on indications by Jean Roulet<sup>8</sup>.

**Type I** – teeth resistance to bleaching

**Type IA**- tetracycline discoloration

**Type IB**- teeth unresponsive to external and internal bleaching.

**Type II**- teeth which need major morphologic modifications.

**Type IIA**- conoid teeth

**Type IIB**- closure of diastema and interdental black triangle

**Type IIC**- Augmentation of incisal length and prominence

**Type III**- extensive restoration in the adult

**Type IIIA**- extensive coronal fracture

**Type IIIB**- extensive loss of enamel-Older age group.

Dietary acids, bulimia, consumption of acidic foods, acidic reflux and chlorine consumption are typical etiological factors of loss of enamel.

**Type IIIC**- Generalized congenital and acquired malformation like enamel dysplasia.

### Indirect Composite Veneers<sup>3</sup>

Indirect composite resin veneers are the treatment of choice in many situations:

Abrasion considerations, darkly stained teeth, conservation of tooth structure, as fabrication alternatives, chairside repairs.

### Clinical technique:

- Clean the tooth and the neighboring tooth with pumice.
- Select the desired shades of composite resin while the teeth are wet with saliva.
- Determine the desired alignment of teeth.
- Prepare the eight maxillary anterior teeth by removing small amounts of enamel with a medium grit flame or chamfer bur. If only minimal preparation is necessary to improve alignment and increase facial contour, remove only 0.25-0.50 mm of enamel from the facial area and none from the incisal area. If incisal reduction is necessary, remove 1-1.5 mm.
- Make a full arch impression of the prepared teeth with a vinyl polysiloxane impression material. No retraction cord is needed because the margins are placed at the gingival crest.
- Make a full arch irreversible hydrocolloid opposing impression.
- Place a provisional restoration if needed.
- Acid etch the lingual side of the veneers with 10% hydrofluoric acid gel for 30 seconds or lightly sandblast with a micro etcher or air abrasion unit and rinse thoroughly.
- Evaluate the internal surface of the veneer to ensure that an etch surface has been achieved.
- Clean the teeth with No. 4 fine pumice in a prophylaxis cup, rinse, and dry with water free and oil free air.
- Use 37% phosphoric acid for 15 seconds to etch the enamel and remove the smear layer from any exposed dentin surface of the first central incisor.
- Rinse thoroughly.
- Leave the tooth surface slightly moist for wet bonding.
- Using a brush, apply silane coupling agent to the internal surface of the veneers and air dry.
- Liberally coat the etched surfaces with a hydrophilic primer from a fourth generation dentin and enamel bonding agent and dry the primer with oil-free and water-free air until the surface appears glossy without

being wet. This indicates that the “hybrid” layer has been established in the dentin and the enamel is thoroughly coated with the resin in the primer.

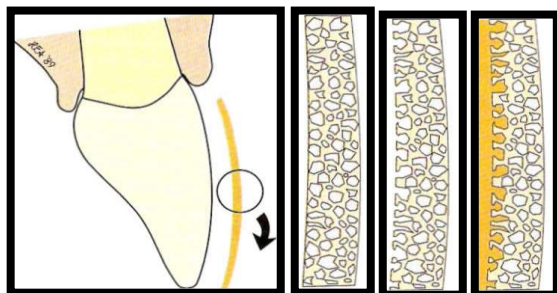
- Paint a thin layer of bonding resin onto the internal surface of the veneers.
- Apply a luting composite resin to the internal surface of one of the veneers. Place the veneer on the prepared tooth and remove excess luting composite resin with a brush dipped in bonding agent.
- Light cure for 40 seconds on the facial and lingual surfaces of the tooth.
- Remove excess cured luting composite resin with a No. 12 surgical blade or a scaler.
- Place the other veneers in the same fashion.
- Finish the margins with 12- and 30-fluted carbide finishing burs, fine diamonds, rubber polishing cups, finishing disks, or other composite resin finishing techniques.

### Bonding indirect resin restorations

- The solubility of glass macro fillers has been used to improve the bond strength of a resin luting agent on a pre-cured resin surface. Strong etching solutions (eg. hydrofluoric acid) have been used as a conditioner to remove soluble macro fillers from the surfaces of pre-cured indirect resin veneers. The spaces left by the glass filler particles allow formation of resin tags, creating a micro mechanical bond to the composite luting agent. This bonding results in greatly improved strength for these indirect resin veneers.
- This method of attachment is only effective with resin restorations in which the internal layer contains a macro filled composite with a soluble glass filler. In addition, the etching solution used must be matched to the filler to dissolve it away effectively. This method of attachment is not advised for restorations made entirely on micro filled composite.

### Delayed resin-resin bonding

Because laboratory processing results in a greater degree of polymerization, fewer bond sites remain in the processed composite for subsequent bonding to the resin cement. A *delayed resin-resin* bonding occurs between the processed composite and the tooth.



### Procedure for delayed resin-resin bonding

Step 1: Remove the outer layer of resin with a coarse diamond, leaving a rough surface. If possible, extend the preparation to the natural margins of the tooth.

Step 2: Etch the resin surface for 15 seconds with phosphoric acid to dissolve any organic debris. If enamel is to be bonded in the same preparation, the enamel should be etched in the usual fashion. With glass-filled composites, sandblasting or etching with hydrofluoric acid (i.e., 9-10%) for 5 seconds, followed by silane, may improve bonding.

Step 3: Rinse with water for 10 to 15 seconds to clean.

Step 4: Dry with an electric dryer, vacuum, or syringe.

Step 5: Add a thin layer of silane, then dry and add a thin layer of bonding agent. Cure.

Step 6: Place and shape the composite resin. Cure and finish in the usual manner.

### Porcelain veneers

Porcelain is generally considered the most esthetic and biocompatible material available for dental restorations.

### Advantages of Porcelain Veneers<sup>4</sup>

- Natural and stable color
- Highly acceptable tensile bond strength
- Inherent porcelain strength
- Extremely good biocompatibility with gingival tissues
- Long lasting
- Exceptional resistance to wear and abrasion
- Resistance to stain.
- Surface luster retention.
- Lack of radiopacity.

### Clinical Technique

A key element in success with porcelain veneers is carefully controlled but appropriate tooth tissue reduction. The aims of tooth preparation are to:

- Provide some space into which the technician can build porcelain without over-contouring the tooth
- Provide a finished preparation that is smooth and has no sharp internal line-angles which would give areas of high-stress concentration in the restoration
- Maintain the preparation within enamel whenever possible
- Define a finish line to which the technician can work.

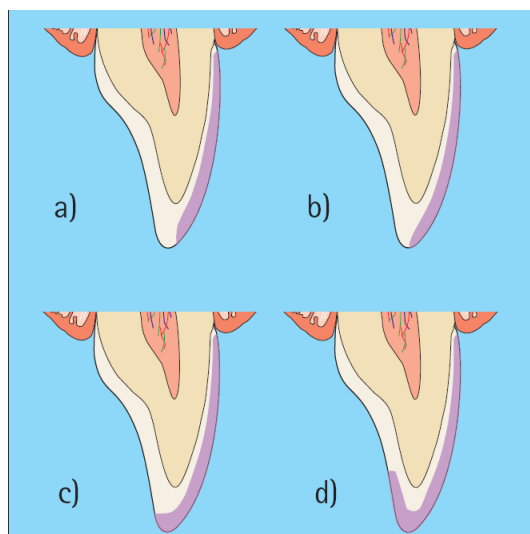
### Depth of preparation<sup>4</sup>

It is desirable for the tooth preparation to remain within enamel so careful control of preparation depth is important. Obviously, the enamel thickness varies from the incisal edge to the cervical margin. Hence the preparation depth will need to vary over the length of the tooth to avoid (if possible) exposing dentine. The preparation depth should be of the order of 0.4 mm close to the gingival margin, rising to 0.7 mm for the bulk of the preparation. This is best achieved by using a depth mark of some sort.

### Incisal edge reduction<sup>9</sup>

One important decision to make before commencing the preparation is whether or not the incisal edge of the tooth is to be reduced. There are four basic preparation designs that have been described for the incisal edge.

- Window**, in which the veneer is taken close to but not up to the incisal edge. This has the advantage of retaining natural enamel over the incisal edge, but has the disadvantage that the incisal edge enamel is weakened by the preparation. Also, the margins of the veneer would become vulnerable if there is incisal edge wear whilst the incisal lute can be difficult to hide.
- Feather**, in which the veneer is taken up to the height of the incisal edge of the tooth but the edge is not reduced. This has the advantage that once again guidance on natural tooth is maintained but the veneer is liable to be fragile at the incisal edge and may be subject to peel/shear forces during protrusive guidance.
- Bevel**, in which a bucco-palatal bevel is prepared across the full width of the preparation and there is some reduction of the incisal length of the tooth. This gives more control over the incisal aesthetics and a positive seat during try in and luting of the veneer. The margin is not in a position that will be subjected to direct shear forces except in protrusion. However, this style of preparation does involve more extensive reduction of tooth tissue.
- Incisal overlap**, in which the incisal edge is reduced and then the veneer preparation extended onto the palatal aspect of the preparation. This also helps to provide a positive seat for luting whilst involving more extensive tooth preparation. This style of preparation will also modify the path of insertion of the veneer which will have to be seated from the buccal/incisal direction rather than the buccal alone. Care needs to be taken to ensure that any proximal wrap around of the preparation towards the gingival margin does not produce an undercut to the desired path of insertion for the veneer. It may be necessary to rotate such veneers into place by locating the incisal edge first then rotating the cervical margin into position.



### Axial tooth reduction<sup>4,9</sup>

Axial tooth reduction is best undertaken using diamond burs in either an aerator or a speed accelerating hand piece with a conventional motor. It is easier to achieve predictable tooth reduction using either a parallel sided or tapered bur with straight sides rather than a flame shaped bur. Some clinicians advocate preparing the gingival finish line as the first step using a round diamond bur of appropriate diameter, which will automatically produce a chamfered finish line.

### Proximal finish lines and cervical finish lines<sup>4,9</sup>

It is best if the proximal finishing margins for the preparation do not extend beyond the contact point in the incisal third of the tooth.

The cervical finish lines for a veneer should be a chamfer with about a 0.4 mm maximum depth. The rounded internal line angle will help to reduce stresses in the margin of the veneer that may otherwise develop during firing.

### Recording an impression<sup>4</sup>

Impression technique and soft tissue handling are dealt with elsewhere in this series, so we will not go into great detail here. However, it is appropriate to use short sections of retraction cord around the margins of the preparations to facilitate the capture of both the finishing edge of the preparation and the adjacent area of the unprepared tooth. Electro-surgery is best avoided because of the risk of gingival recession revealing the veneer margin

### Trial placement<sup>4</sup>

Check the quality of fit and gingival extension of the veneer against the tooth, which should have been cleaned with pumice in water prior to the trial. Once you are happy that the quality of fit is acceptable, the next stage is to assess the color match. If it is necessary to try to modify the color of the finished restoration using the luting resin then the veneer must be tried in with an appropriate colour of paste.

### Luting the veneer<sup>4,9</sup>

Having applied the dentine/enamel bonding system the veneer should be loaded with luting resin and located on the surface of the tooth. At this stage the excess of unset resin around the periphery of the veneer can best be removed using a metal instrument or a brush dipped in unfilled resin.

Once all gross excess is removed the luting resin can be cured using a visible light activation unit. It is essential to ensure an adequate exposure to cure fully the luting resin through the porcelain veneer. Most manufacturers' guidelines suggest 30–40s cure times. This is inadequate with research suggesting that 60s is more realistic. Light-activation of a luting agent through an opaque veneer or one of greater than 0.7 mm thickness is not adequately effective.

**Post placement finishing<sup>9</sup>**

The final stage for any restoration is finishing the margins of the restoration and any functional contacts to give a smooth and harmonious transition from tooth to restoration. It is particularly important to eliminate any occlusal interferences. The finishing process for porcelain veneers involves using small particle size diamond burs or multi-fluted tungsten carbide burs in either an aerator or a speed accelerating handpiece. Burs are available in a variety of grit sizes to polish the margins progressively and ideally should be followed by the use of 10 mm particle size diamond polishing paste to maximize the luster on the porcelain and the cement lute.

Finishing can also be achieved using rotating abrasive disks that are available for composite resin restorations (eg Soflex discs, Super-Snaps etc).

**Clinical steps:**

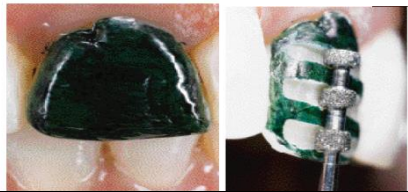
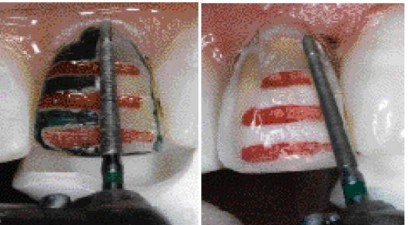

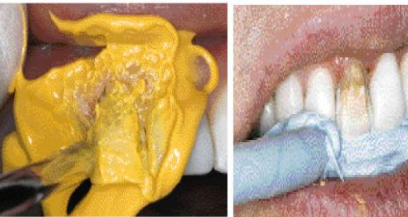
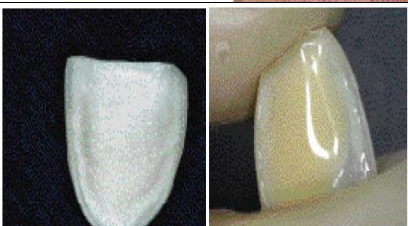
**Non-Standard Veneers<sup>9</sup>**

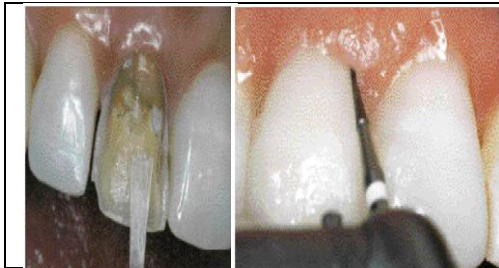Veneers are generally prescribed for the buccal aspects of maxillary anterior teeth, but there are a number of ‘non-standard’ applications. These include veneers for:

- The palatal/lingual aspect of teeth which have been worn or fractured
- Diastema elimination using slips restricted to the proximal aspects of teeth
- Lower incisors
- Posterior occlusal onlays

**Indirect Bonding--Lumineers® Indirect bonding without shots**

LUMINEERS BY CERINATE is a cosmetic solution for permanently stained, chipped, discolored and misaligned teeth. It may even be used to revitalize old crowns and bridgework.

	<p>The discolored incisor is painted green to help guide the depth cuts. The special three-tier extra-coarse diamond depth curter (Brasseler, Savannah, GA) comes in 0.5-mm (LVS-1) and 0.3-mm (LVS-2) thicknesses and is so efficient that usually one sweep across the labial surface completes the depth cut.</p>
	<p>After completing the depth cur (marked in red for illustrative purposes only), the remainder of the preparation is completed with the two grit diamond.</p> <p>The tip of the two-grit diamond LVS-3 or -4, Brasseler, has a fine grit for marginal finishing.</p>
	<p>Gingival displacement cord is carefully removed after remaining in the sulcus for approximately 10 minutes.</p> <p>With the tissue displaced, the gingival margin can now be placed just into the gingival sulcus.</p>
	<p>Vinyl polysiloxane is an excellent material for a final impression.</p> <p>After applying another layer of syringe material a tray filled with the vinyl polysiloxane putty is pressed into place.</p> <p>Occlusal registration is also made with vinyl polysiloxane paste.</p>
	<p>The interior view of the laminate shows the presence of an opaque layer to help mask the dark tooth.</p> <p>After etching and silanating the interior surface of the porcelain laminate, the tinted cement is added.</p>
	<p>The prepared tooth is cleansed with coarse pumice and etched before the bonding agent is applied.</p> <p>The filled laminate is gently pressed to place. and held there with a gloved linger while polymerizing with the light for 5 to 8 seconds. Interproximal excess is removed with the sickle end of the Novatech 12 and the laminate is then completely cured for 60 seconds labially and 60 seconds lingually; or 10 seconds with an argon laser or xenon light</p>



All remaining composite resin cement excess is then removed with the LVS-5 30-blade carbide bur. If contouring is required it can easily be accomplished with the LVS4 -7, or -8 burs.

## Inlays and Onlays

### Indirect Composite Inlay/Onlay

Composite resin inlays and onlays are the treatment of choice in many situations<sup>3</sup>: Esthetic considerations, structural considerations, Abrasion considerations, Conservation of tooth structure, Supragingival margins, and Chairside repairs.

### Advantages of indirect Composite Inlays Compared to Direct Composite Restorations<sup>3,10</sup>.

- a) With the Indirect technique the dentist can
  - more easily control the cervical adaption
  - shape the interproximal and occlusal surfaces
  - make an appropriate contact point
- b) Through the processing and shaping of the composite in the laboratory, it's possible clearly to improve the material properties (density, wear resistance. and water absorption).
- c) Since the clinical process is relatively simple for composite inlays, and it is easier to produce good and sealed margins, composite inlays show lower secondary caries frequency and fewer color changes than direct composites when used in posterior region.
- d) Reduced micro leakage.

### Disadvantages Compared to ceramic Inlays<sup>3</sup>

- Lower wear resistance than ceramic inlays.
- Still inappropriate for substituting occlusal surfaces exposed to large forces.

### Etched Posterior Porcelain Restorations<sup>4,11</sup>

Although new developments continually improve the composite resins used for indirect inlays and onlays, porcelain has numerous advantages.

#### Indications

Etched porcelain inlays are suitable for any clinical situation for which porcelain has superior esthetics ability to restore strength to compromised teeth, and conservative treatments are indicated.

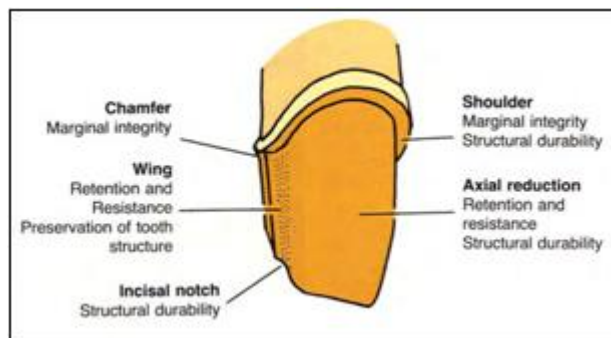
- 1) Small to moderate carious lesions for which the patient requests a highly esthetic restoration.
- 2) Large amalgam or composite restorations involving the mesial- or distolingual surface of a cuspid showing unacceptable discoloration or compromised contacts.

- 3) Large carious or traumatic lesions with undermined enamel to the extent that a cast metal restoration or a full crown would otherwise be necessary For these situations the cross-linked resin-bonded porcelain restoration will bond to the remaining tooth structure, binding it together into what is, in effect, a homogeneous mass.
- 4) The endodontically compromised tooth where the access cavity has compromised the strength and prognosis of the tooth. An etched porcelain restoration can be a conservative alternative to a post-and-core and hull-coverage crown.
- 5) Heavily undermined incisal edge or proximal surface on an incisor requiring support to keep an otherwise pleasing intact tooth from fracturing.
- 6) Class IV restorations replacing missing incisal and/or proximal aspects of the tooth.
- 7) Teeth opposed by existing porcelain restorations, which otherwise would tend to wear extensively
- 8) Teeth where it is difficult to develop retention form. The bonded restoration's adhesive nature may be more effective than other means of developing retention such as pins, periodontal crown lengthening or a post and core after elective endodontic therapy.
- 9) Patients for whom allergy to metal is proven or suspected.

#### **Contraindications:**

- 1) It is not a restoration of choice if an anterior tooth is grossly involved either proximally or cervically. There must be adequate tooth structure to support the restoration.
- 2) When access to the lesion is poor and overcutting of tooth structure would be required Eg; in rotated teeth. In such conditions other restorations should be considered.
- 3) Patients with poor oral hygiene and inadequate motivation.
- 4) When short teeth preclude developing adequate resistance and retention forms. Eg: Heavily worn down teeth.
- 5) Teeth with insufficient tooth substance for bonding.
- 6) Preparations with excessive undercuts
- 7) Where adequate isolation is not possible.
- 8) Teeth with large pulp chambers, which limit the reduction of tooth structure.
- 9) Where posterior group function and reduced vertical dimensions apply strong lateral forces on the restorations.

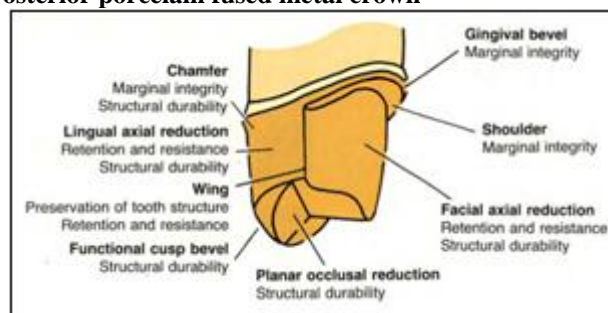
Double inlay technique: <sup>12</sup>	Gold and ceramic have long been used in prosthetic dentistry. In the posterior region, it is possible to use both materials with the double-inlay technique to add the strength of metal to the esthetics of ceramic.
Natural inlay: <sup>13</sup>	Here the restoration is milled from an extracted human tooth instead of a porcelain block.
Cerana-prefabricated inlay system <sup>14</sup>	Cerana Inlay System from Nordiska Dental offers quick and easy, durable ceramic inlays in a single visit without the need for a laboratory and the inconvenience of impression taking.



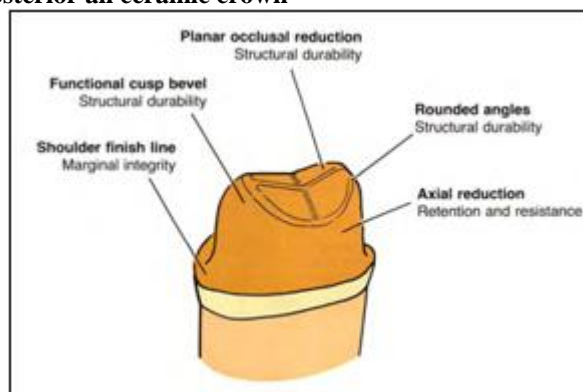
**Clinical Problems Associated with Ceramic Inlays and Onlays <sup>15</sup>**

- Fracture
- Hypersensitivity
- Fit
- Marginal integrity
- Microleakage
- Bonding
- Cement wear
- Ceramic inlay/onlay material wear and opposing tooth wear
- Plaque accumulation, gingivitis, and secondary caries
- Colour
- Anatomic form
- Radiopacity

**Posterior porcelain fused metal crown**



**Posterior all ceramic crown**



**Complete Crown Restorations**

**Indications for a full crown are:**

- 1) Teeth with extensive decay
- 2) Teeth weakened by extensive restorations
- 3) Teeth with excessive extensive wear
- 4) Teeth severely weakened or prone to fracture as a result of endodontic treatment
- 5) Teeth fractured or compromised with extensive microcracks and needing to be restored
- 6) Severely extruded teeth (to restore the plane of occlusion)
- 7) Teeth with an inappropriately short coronal portion
- 8) Malformed teeth
- 9) Abutments for fixed partial dentures
- 10) Long-span fixed partial dentures (where abutment teeth need maximum retention)
- 11) Teeth with unattractive tissue recession and unsightly interdental spaces

**Teeth Preparation <sup>16</sup>**

**Anterior porcelain fused metal crown**

**2. Conclusion**

Dentistry is an ever changing science. As new research and clinical experience broaden our knowledge, changes in treatment are required. This paradigm shift in the field of dentistry comes along just in time to meet the final needs and wants of patient who perceives an attractive smile no longer as a luxury but rather a necessary part of their life style. Aesthetic dentistry enables the dentist to change the appearance, size, color, shape, spacing, positioning of the teeth. The allure of conservative preparations, the potential for excellent esthetic results and gingival.

Health has made this branch of dentistry very popular over the world. No wonder it has enjoyed such a wide spread utilization and at the same time proven itself with such predictable and excellent results.

Dr. Charles Pincus is rightly recognized as the Father of esthetic dentistry made a prophetic statement in the year 1937 which is quoted as “A captivating smile showing an even row of gleaming white natural teeth is a major factor in achieving the dominant characteristic known as personality. This entails a lack of inferiority complex which causes a hand to be raised to cover the mouth.



It is this lack of confidence in the dental equipment, which often spells the difference between success and failure in the life of many people.

The above statement was true in the year 1937 is a reality today and will be so in the years to come.

## References

- [1] *Sturdevent, Art and Science of Operative dentistry, 5<sup>th</sup> edition*
- [2] Jeff T. Blank. Scientifically Based Rationale and Protocol for Use of Modern Indirect Resin Inlays and Onlays. *J Esthet Dent* 2000 12:195-208
- [3] *Aschheim KW, Dale BG. Esthetic dentistry: a clinical approach to techniques and materials. 2nd ed. St. Louis: Mosby; 2001.*
- [4] Ronald E Goldstein, *esthetic in dentistry 2<sup>nd</sup> edition, vol I.*
- [5] Kenneth J. Anusavice, *Phillips' Science of Dental Materials. 11<sup>th</sup> Edition.*
- [6] Edward A. McLaren, Phong Tran Cao. *Ceramics in Dentistry-Part I: Classes of Materials. Inside dentistry. October 2009*
- [7] Heather J. Conrad, Wook-JinSeong, and Igor J. Pesun. *Current ceramic materials and systems with clinical recommendations: A systematic review. J Prosthet Dent* 2007;98:389-404)
- [8] Jean-Fracois Roulette, *Advances in Dentistry 2005.*
- [9] A. W. G. Walls<sup>1</sup> J. G. Steele<sup>2</sup> and R. W. Wassell *Crowns and other extra-coronal restorations: Porcelain laminate veneers British Dental Journal Volume 193 no. 2 July 27 2002.*
- [10] Douglas A. Terry, *Compendium / February 2001 Vol. 22, No. 2.*
- [11] ALFREDO MEYER FILHO, *J EsthetRestorDent* 15:338-352,2003.
- [12] Hannig Matthias. *Esthetic posterior restorations utilizing the Double-Inlay technique: A novel approach in esthetic dentistry. Quintessence International, 1997,28:2:79-83.*
- [13] Moscovich H et al *The novel use of extracted teeth as a dental restorative material- the ' Natural Inlay', Journal of Dentistry, 26:1:21-24.*
- [14] Millar BJ. *Cerana--a direct ceramic inlay technique. Prim Dent Care. 1999 Apr;6(2):59-62.*
- [15] Mark A. Bergman, *The clinical performance of ceramic inlays:A review, Australian Dental Journal* 1999;44:(3):157-168
- [16] Herbert T. Shillingburg Jr., Sumiya Hobo, Lowell D. Whitsett, Richard Jacobi, Susan E. Brackett, *Fundamentals of Fixed Prosthodontics, 3<sup>rd</sup> Edition.*