

# Study on Clinical Profile and Efficacy of Prazosin in Scorpion Sting Envenomation in Children of Anathapur

Aswathy Thankachy .K<sup>1</sup>, Dr. S. Srilatha<sup>2</sup>, Dr. Shankar Narayana<sup>3</sup>

<sup>1</sup>Dr Y. S. R University of Health Sciences

<sup>2</sup>Assistant Professor Department of Pediatrics, Government General Hospital, Anathapur

<sup>3</sup>Assistant Professor, Department of Pediatrics, Government General Hospital, Anathapur

**Abstract:** This study was an evaluation of the pattern of presentation, the outcome and the efficacy of Prazosin in scorpion sting envenomation at a tertiary care hospital in Anathapur, Andhra Pradesh. **Methods:** A total of 120 consecutive children were prospectively studied. The data included demographics, the time of presentation to the hospital, the clinical features, and the premedication which was given before the arrival of the subjects at the hospital, response to the oral Prazosin and the hospital outcome. **Results:** Local pain, sweating and peripheral circulatory failure were the common clinical presentations. Complications like acute pulmonary oedema, myocarditis, shock and encephalopathy were also seen. These were treated with a combination of Prazosin with either inotropes or vasodilators. Mortality was seen in 6 (5%) children. The usage of antihistaminics and steroids in these children led to higher mortality. Oral Prazosin, a postsynaptic alpha -1 blocker, is a highly effective drug for scorpion sting envenomation. **Conclusion:** Scorpion sting envenomation is an acute life threatening emergency and an early presentation to the hospital and an early intervention with Prazosin can hasten the recovery in the scorpion sting victim.

**Keywords:** scorpion sting, envenomation, myocarditis, oral prazosin, vasodilators, late presentation, PICU

## 1. Introduction

Scorpion sting envenomation is an acute life threatening time limited medical emergency, if left untreated. It is a frequent event in the tropical, subtropical and the temperate zones of the world and poses a public health problem in certain parts of India also. *Mesobuthus tamulus* or the Indian red scorpion is the most lethal scorpion species. These are found abundantly in western Maharashtra, northern Karnataka, Andhra Pradesh and Tamilnadu. Children are at greater risk of developing severe envenomation like cardiac, respiratory and neurological complications as compared to the adults. The clinical manifestations of scorpion envenomation are vomiting, profuse sweating, cold extremities, pulmonary oedema and death. The deaths in scorpion sting envenomation are attributed to cardiopulmonary complications like myocarditis and acute pulmonary oedema.

Prazosin, a postsynaptic alpha -1 blocker, counteracts the effects of excessive catecholamines and arrests the development of severe systemic features. It has been found to be an effective drug for scorpion sting envenomation and it has reduced the mortality rate to 1% as compared to a 30% mortality rate in the pre-Prazosin era. The present study was done to observe the pattern of presentation and also the outcome and the efficacy of Prazosin in scorpion sting envenomation in children who were admitted at tertiary care center.

## 2. Materials and Method

- This prospective study was conducted at Government Medical College, Anathapur, a tertiary care hospital in Andhra Pradesh, India, during the period from AUGUST 2020 to MARCH 2022 (21 MONTHS). All the cases who were aged between 0-12 years and who

presented to the emergency department with a history of scorpion sting envenomation, the presence of the sting mark and or the scorpion seen in the vicinity of the child by the parents or near family members were admitted. In total, around 120 cases were studied during this 21 month period. Informed consent was taken from the parents or the relatives of the children. The details of the clinical features and the treatment which was given at the PHC/referring hospital were noted from the reference letter. All clinical details including blood pressure, heart rate, chest findings and the temperature of the extremities were recorded at admission and thereafter at each one hour on a pretested standard proforma.

- The diagnosis of various systemic involvements was done, based on the clinical manifestations and investigations. Myocarditis was diagnosed if the child had tachycardia, muffled heart sounds, a gallop rhythm and a systolic murmur, ECG changes (low amplitude, ST segment changes, and the presence of arrhythmias), elevated LDH, cardiomegaly on chest X-ray and a decreased ejection fraction on 2 D Echocardiography. Acute pulmonary oedema was diagnosed on the basis of the presence of tachypnoea, a pinkish frothy sputum, bilateral crepitations and radiological findings, which were complemented by the ABG analysis. The autonomic storm was diagnosed on the basis of sweating, vomiting, excessive salivation, priapism, shivering and hypotension or hypertension
- The patients were continuously monitored in the intensive care unit for pulse rate, respiratory rate, blood pressure, temperature, SPO2, capillary refilling time and for signs of systemic involvements like the development of pulmonary oedema, myocarditis, encephalopathy and shock. A complete haemogram, serum electrolytes, blood sugar, arterial blood gas analysis, renal function tests, ECG and chest radiographs were done and

Volume 12 Issue 1, January 2023

[www.ijsr.net](http://www.ijsr.net)

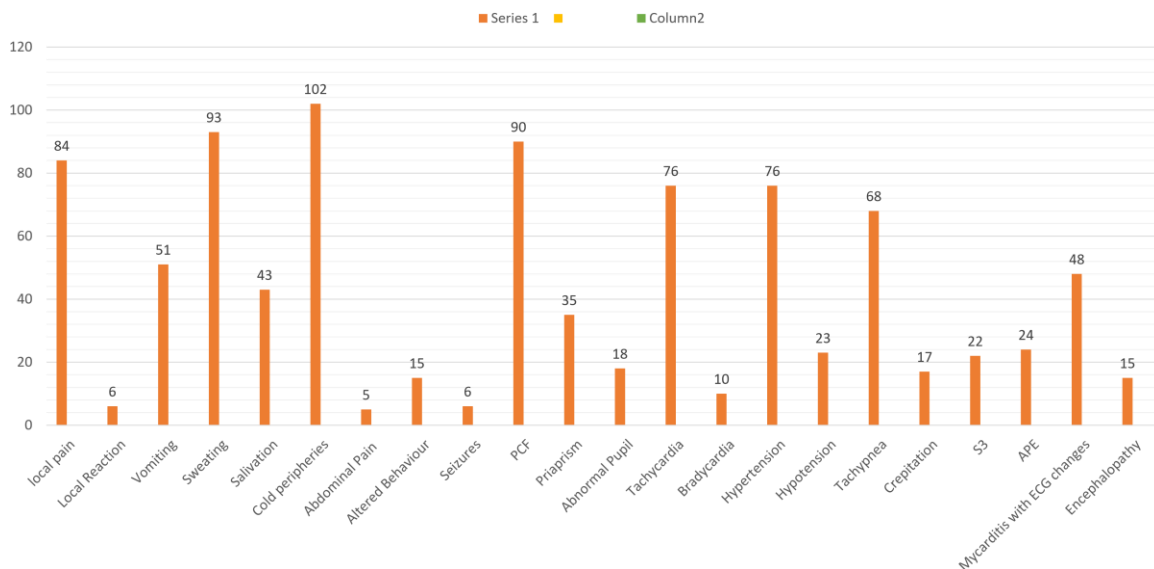
Licensed Under Creative Commons Attribution CC BY

evaluated in all children. 2D Echocardiography was done in all patients with myocarditis

- Cases with a history of scorpion sting which came within 6 hours were given Paracetamol for pain and a dose of Prazosin (30ug/ kg) tablet either through a nasogastric tube or per oral, which were given 4 hourly till all the symptoms subsided. Asymptomatic cases which came after 6 hours of the scorpion sting were kept under observation and they received only symptomatic treatment without Prazosin. All the symptomatic cases were given Prazosin and supportive care. Children with acute pulmonary oedema were managed with the judicious use of vasodilators and inotropes along with supportive measures and were ventilated whenever required. All the cases were observed for a minimum period of 24 hours. Cases with complications were discharged after they were off the drugs for 24 hours and after they were stable for 48 hours.
- The analysis was done in with respect to the complications, the time interval between the scorpion sting and admission to the hospital and mortality.

### 3. Results

- 120 children between the age group of 0-12 years were studied during the study period. 40 children had local involvement i.e. pain and swelling at the sting area.



Column 1

- Children who came late had the features of excessive sympathetic activity (tachycardia, intense vasoconstriction and carditis). Those children who presented immediately after the sting (within 30 minutes) had the features of parasympathetic hyperactivity (i. e. sweating, salivation bronchospasm and vomiting). All these symptoms indicated the autonomic storm at presentation. The most common presenting symptoms were irritability and profuse sweating, hurried breathing and cold extremities followed by an altered sensorium. The most common clinical signs were tachycardia, tachypnoea, cold extremities, perspiration and hypotension.
- Myocarditis was detected in 24 (20%) cases clinically could be diagnosed in 40% of cases after other investigations like ECG findings like ST segment depression in 25% cases. 24 cases (20%) had pulmonary oedema with myocarditis. Acute pulmonary oedema with myocarditis, shock and encephalopathy were found in 15 (12.5%) patients and 12 of them required mechanical ventilation. Out of the 12 patients, 6 died. All the 6 patients who died had received intravenous dexamethasone and antihistaminics prior to the presentation to the hospital and they had presented 6-12 hours after sting

- Most of the cases with myocarditis had acute pulmonary oedema and many had the S3 gallop. The late onset acute pulmonary oedema could have been due to the acute myocardial injury and the left ventricular failure and the toxin induced autonomic storm. There was no significant difference between the means of the basic parameters such as age, blood pressure, GCS, haemoglobin levels, total leukocyte count and serum electrolytes among both the survivors and the non survivors
- The time gap between the scorpion sting and presentation to the hospital is one of the significant risk factors which determine better outcomes and mortality. Children who presented after 6 hours of the sting had a significantly higher mortality rate, as was also reported by Biswal et al. Most of the cases with acute pulmonary oedema, encephalopathy and myocarditis, who came to us after 6 hours of the sting, had higher mortality and morbidity. However, some studies have shown higher mortality in those patients who were admitted between 30 min to 3 hours of the sting.
- Mortality and complications were seen in those patients who presented to the hospital after 6 hours of the sting. Most of the deaths (75%) were seen in the age group between 1-5 years. The highest mortality was due to cardiovascular complications i.e. myocarditis in 74%, pulmonary oedema in 22% and encephalopathy in 4% cases. 2 cases were complicated with thromboembolic features (deep vein thrombosis and arterial thrombosis).
- The mortality which was observed in this study was seen in 6 (5%) cases, as compared to the 1% to 10.7% which was reported by various authors from different places. The causes for higher mortality may be late presentation, the use of intravenous dexamethasone and antihistaminics and associated multiple systemic involvements. Dexamethasone alone or in combination with antihistaminics is known to potentiate the effect of catecholamine on the cardiovascular system and the CNS and to worsen the encephalopathy, as was also observed by other authors
- The mortality was less in cases which were treated with Prazosin alone in comparison to others who received dobutamine, dopamine or SNP along with Prazosin. This could be due to the protective effect of Prazosin on the cardiovascular and the respiratory systems. Prazosin reverses both the inotropic and hypokinetic phases and reverses the metabolic effects which are caused by depressed insulin secretion. So the early administration of Prazosin reduces the mortality which is associated with encephalopathy, which is due to the neutralization of the adverse effect of catecholamine which is released into the brain, as the catecholamines which are released outside the brain do not cross the blood-brain barrier.

#### 4. Discussion

- The Indian red scorpion's (*Mesobuthus tamulus*) venom is a potent sodium channel activator, resulting in the stimulation of the autonomic nervous system, which in turn leads to the sudden release of endogenous catecholamines into the circulation. The venom initially leads to a transient cholinergic phase, followed by sustained adrenergic hyperactivity, which is a venom

dose dependent phenomenon. The clinical manifestations depend upon the dose of the venom, the age of the child, the season of the sting and the time lapse between the sting and hospitalization.

- Of the 120 cases, 70 (58.3%) were boys and 50 (41.7%) were girls, as was also reported by Biswal et al. 107 (89.2%) cases of scorpion stings came from rural areas and 82 (68.3%) cases had the sting over the foot-leg, which was similar to Bosnak et al's observations, where 71% cases were from rural areas and 55.6% had the sting over the foot-leg. Peripheral circulatory failure cases with cold extremities were seen in 90 (75%) of the cases which was similar to the 83% cases which were reported by Bawaskar et al and the 75.5% cases which were reported by Biswal et al. This is due to early stage of compensated shock due to excessive catecholamine, resulting in peripheral vasoconstriction, but without significant myocardial dysfunction

#### 5. Conclusion

- Scorpion sting envenomation is an acute life threatening emergency in children and timely referral and early therapy with Prazosin may be life saving. The presence of metabolic acidosis, myocarditis, encephalopathy and acute pulmonary oedema are important determinants of the mortality and morbidity in children. Treatment with steroids and antihistaminics before admission was associated with a poor outcome.
- Oral Prazosin is fast acting, easily available, cheap, free from any anaphylaxis and highly effective. Early intervention with oral Prazosin and the appropriate use of dobutamine and SNP can hasten the recovery in the scorpion sting victim.

#### References

- [1] Santhanakrishnan BR, Ranganathan G, Ananthasubramanian P. Cardiovascular manifestations of scorpion stings in children. *Indian Pediatr* 1977; 14: 353-356.
- [2] Mahadevan S. Scorpion sting. *Indian Pediatr* 2000; 37: 504-513.
- [3] Ismail M. The scorpion-envenoming syndrome. *Toxicon* 1995; 3: 825-858.
- [4] Sofer S, Gueron M. Vasodilators and hypertensive encephalopathy following scorpion envenomation in children. *Chest* 1990; 97: 118-120.
- [5] Bawaskar HS, Bawaskar PH. Cardiovascular manifestations of scorpion sting in India (Review of 34 children). *Ann Trop Pediatr* 1991; 11: 381-387.
- [6] Santhanakrishnan BR, Balagopal Raju V. Management of scorpion sting in children. *Trop Med Hyg* 1974; 77: 133-135.
- [7] Biswal N, Murmu Uday C, Mathai B, Balachander J, Srinivasan S. Management of scorpion sting envenomation. *Pediatrics Today* 1999; 2 (4): 420-426.
- [8] Murthy KRK, Vakil AE, Yeolekar RE. Insulin administration reverses the metabolic and echocardiographic changes in acute myocarditis which is induced by Indian red scorpion (*B. tamulus*) venom in experimental dogs. *Ind Heart J* 1990; 42: 35-37

- [9] Bawaskar HS, Bawaskar PH. Utility of scorpion antivenom vs Prazosin in the management of severe *Mesobuthus tamulus* (Indianred scorpion) envenoming at a rural setting. *J Assoc Physicians India*.2007; 55: 14-21.
- [10] Miller R, Awarn A, Maxwell BB, Masson DT. Sustained reduction of cardiac impedance and preload in congestive cardiac failure with antihypertensive Prazosin. *New Engl J Med* 1977; 297: 303-307.
- [11] Bawaskar HS, Bawaskar PH. Scorpions sting: a review of 121 cases. *J Wilderness Medicine* 1991; 2: 164-174.
- [12] Vasconcelos F, Lanchote VL, Bendhack LN, et al. Effects of voltage-gated Na<sup>+</sup> channel toxin from *Tityus serrulatus* venom on rat arterial blood pressure and plasma catecholamines. *Comp Biochem Physiol C Toxicol Pharmacol*.2005; 141: 85-92.
- [13] Bawaskar HS, Bawaskar PH. Management of cardiovascular manifestations of poisoning by the Indian red scorpion (*Mesobuthus tamulus*). *Br Heart J* 1992; 68: 478-480.
- [14] Biswal N, Bashir RA, Murmu Uday C, Mathai B, Balachander J, Srinivasan S. Outcome of scorpion sting envenomation after a protocol guided therapy. *Indian J Pediatr* 2006; 73: 577-582.
- [15] Bosnak M, Levent YH, Ece A, Yildizdas D, Yolbas I, Kocamaz H, et al. Severe scorpion envenomation in children: management in the pediatric intensive care unit. *Hum Exp Toxicol* 2009; 28 (11): 721-728.
- [16] Bawaskar HS, Bawaskar PH. Prazosin in the management of cardiovascular manifestations of scorpion sting. *Lancet* 1986; 1: 510-511.
- [17] Bawaskar HS, Bawaskar PH. Indian red scorpion envenomation. *Indian J Pediatr* 1998; 65: 383-391.
- [18] Prasad R, Mishra OP, Pandey N, Singh TB. Scorpion sting envenomation in children: Factors affecting the outcome. *Indian J Pediatr* 2011; 78 (5): 544-548.
- [19] Graham RM, Hettinger WA. Drug therapy-Prazosin. *New Engl J Med* 1979; 300: 232-235.
- [20] Bawaskar HS, Bawaskar PH. Vasodilators: Scorpion envenoming and the heart (An Indian experience). *Toxicon* 1994; 32: 1031-1040