

Methylene Blue Adjunct Debridement for Postoperative Spinal Infection

Norisyam Y¹, Sughilan SM², CH Foo³, Zairul Anuar KB⁴

^{1,4} Spine Unit, Orthopedic Department, Penang Hospital, 10990 Georgetown, Penang, Malaysia
Email: [norisyamyusoff\[at\]gmail.com](mailto:norisyamyusoff[at]gmail.com)

^{2,3} Spine Unit, Orthopedic Department, Queen Elizabeth Hospital, 88200 Kota Kinabalu, Sabah, Malaysia
Email: [sughilan91\[at\]gmail.com](mailto:sughilan91[at]gmail.com)

Abstract: Introduction: Postoperative spine infections are a devastating surgical complication that to a poorer surgical outcome with increased morbidity and economic burden. There is no consensus set of diagnostic criteria to define a postoperative spine infection there are no well-established protocols for surgical treatment of postoperative spine infections. Successful treatment poses a significant challenge to eradicating the infection because of the presence of biofilms on metal instrumentation while the retention of implants is indicated for maintaining spinal stability. Methods: Seven patients were treated for postoperative spinal infection and we describe an adjunctive surgical approach with the application of methylene blue intraoperatively to enhance the debridement procedure to improve the outcome of the eradication of infection in retaining the spinal implant and evaluate clinical success based on the eradication of infection and infection free survival. Results: We report a series of 7 patients with deep postoperative spinal infection who were treated from January 2021 to December 2021 with a mean age of 41.14 years based on multiple surgical interventions and risk factor. All the patient were subjected to same protocols of management with methylene blue guided debridement, brushing and soaking with antibacterial cocktail solutions and followed by partial wound closure with vacuum assisted closure (VAC). The outcome of study is reporting on bacteriological study, progression of wound management and outcome of management. Conclusion: The management of postoperative spinal infection is crucial and challenging with no universally accepted protocols to establish the diagnosis and guide the treatment. Methylene blue guided debridement technique is useful as adjunct method for optimal removal of biofilms and effective debridement for total eradication of infection to improve the outcomes.

Keywords: Postoperative spinal infection, methylene blue, adjunct debridement

1. Introduction

Postoperative spine infections are devastating surgical complications that leads to poorer surgical outcomes, increased morbidity and economic burden. Recent literature reports the incidence of postoperative spinal infection after instrumented spinal surgery, which has been observed to range from 2.2% to 18% with variability of the spine surgery [1-2]. There is no consensus on a set of diagnostic criteria to define a postoperative spine infection with no well-established protocols for the surgical treatment of these infections. Successful treatment poses a significant challenge to eradicating the infection because of the presence of biofilms on metal instrumentation, while the retention of implant is indicated for maintaining spinal stability.

The methylene blue guided debridement technique is an established method in arthroplasty surgery to enhance the identification and removal of the bacterial biofilms on the implant as well as to allow for the adequate removal of nonviable and infected tissue while avoiding healthy tissue.

2. Methods

This study presents a retrospective analysis of a series of postoperative spinal infections that were treated at Queen

Elizabeth Hospital, Sabah, a spine center in East Malaysia. We describe an adjunctive surgical approach involving the intraoperative application of methylene blue to enhance the debridement procedure and improve the outcome of

eradicating infection in the retaining spinal implant, as well as evaluating clinical success based on the eradication of infection and infection-free survival.

A series of seven patients were treated for postoperative spinal infections from January to December 2021. All the patients underwent the same management protocol, which included a complete septic workup and assessment of infective parameters. Surgical debridement was performed as early as possible after diagnosis, and empirical antibiotics were initiated post intraoperative sampling, followed by therapeutic antibiotics based on the culture and sensitivity. The surgical debridement approach involved a combination of adjunctive surgical techniques with methylene blue-guided debridement, brushing, and soaking with an antibacterial cocktail solution, followed by partial wound closure with vacuum-assisted closure (VAC).

2.1 Methylene blue guided debridement

Before making an incision and exploring the wound, a larger bore needle was introduced to aspirate a specimen from the wound, which was then sent for culture. Afterward, 50 milliliters of dilute 0.1% methylene blue was injected into the wound and allowed to distribute for at least 1 minute to optimize tissue staining (Figure 1). The wound was subsequently explored through an initial surgical incision, and suction was used to aspirate the remaining dye within the wound. Before tissue sampling and debridement, 1 liter of normal saline solution was used to irrigate the wound (Figure 2). Tissue samples stained with blue were sent for microbiological studies, including bacterial, fungal, and

tuberculosis cultures, as well as tissue for histopathological examination. After exposing the wound, radical debridement was performed zone by zone to remove all the blue-stained soft tissue, including tissue beneath the spinal implant (Figure 3)

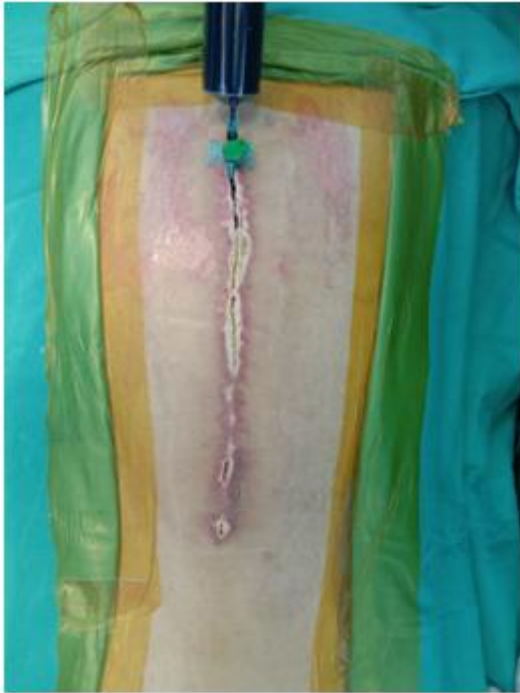

Figure 1: Surgical wound was injected with dilute 0.1% of methylene blue prior to wound exploration.

2.2 Brushing and soaking with antibacterial cocktailsolutions

After the thorough and satisfactory debridement of all blue-stained soft tissue, antibacterial cocktail solutions consisting of 6% Hydrogen Peroxide, 10% Povidone Iodine, and 4% Chlorhexidine Gluconate were used to scrub all visible blue staining over the implant. This solution was allowed to soak for 5 minutes. Finally, the wound was irrigated with at least 6 liters of normal saline solution (Figure 4).

2.3 Partial wound closure with vacuum assisted closure (VAC)

After cleaning and irrigation, a surgical team member replaced their used gloves, and the wound was re-draped with clean drapes. The upper half of the wound was partially closed with watertight suturing (Figure 5), and a VAC dressing was applied to the lower half of the wound as a dependent area for drainage (Figure 6). Every 5 days, wound assessment was performed to decide on subsequent therapy, which could include either a continuation of VAC dressing, re-debridement of the wound followed by VAC dressing, or secondary closure of the wound.

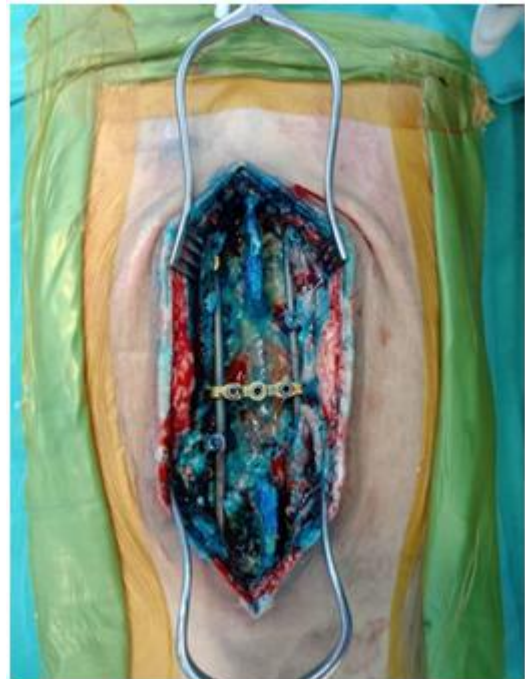


Figure 2: Surgical wound was stained with color of methylene blue to indicated nonviable tissue and biofilm on implant.

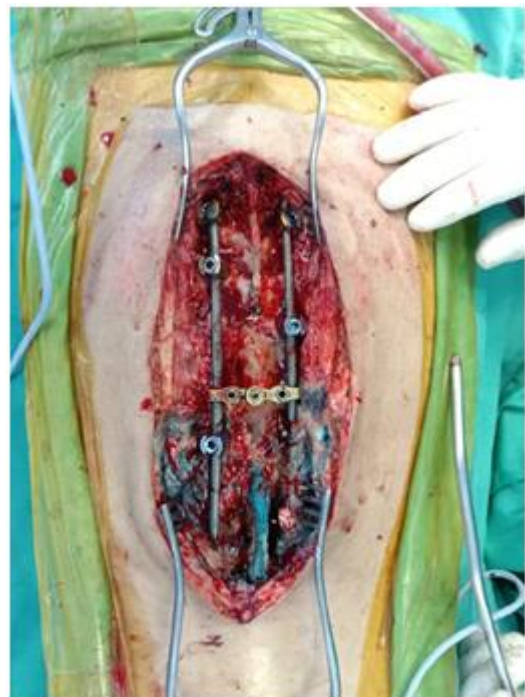

Figure 3: Surgical wound was debrided zone by zone with radical debridement.

Results

Out of a total of 77 patients who underwent spinal instrumentation surgery in 2021, 7 patients developed postoperative spinal infections, resulting in a rate of 0.1%. Among these cases, there were 3 men and 4 women with an average age of 41.14 years, ranging from 12 to 67 years. Only 1 case involved an early onset of deep spinal infection that occurred 2 weeks after surgery, specifically related to post-traumatic lumbar instrumentation, while the other 6 cases were classified as late-onset spinal infections,

manifesting at an average of 35.3 weeks postoperatively, with a range from 8 weeks to 15 months.

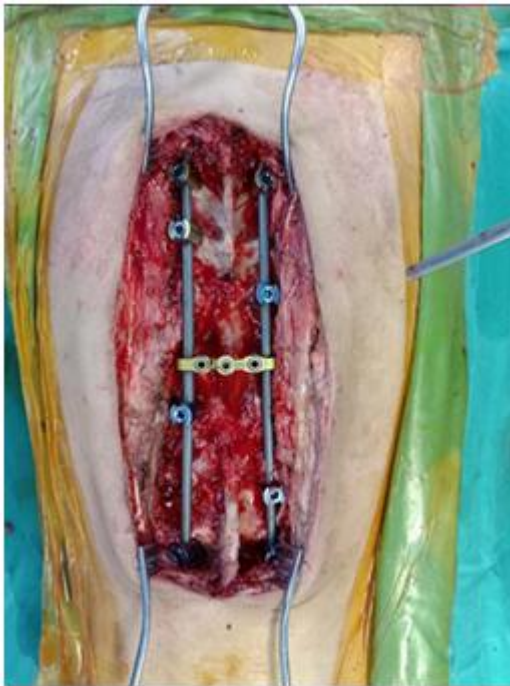


Figure 4: Surgical wound after brushing and soaking with cocktail solutions and irrigated with normal saline with no bluer stained tissue

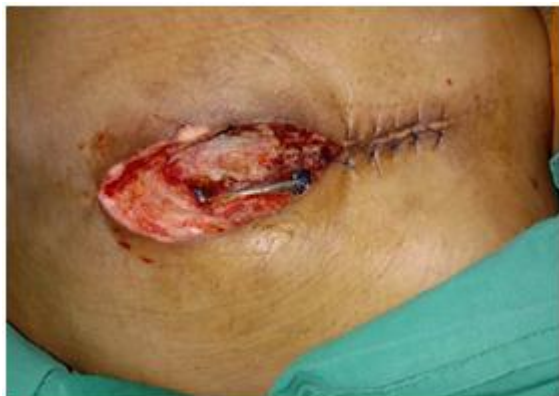

Figure 5: Partial closure with water tight suturing of upper half of the wound.

The late onset of surgical site infection involved 1 growing rod scoliosis implant with 2 lumbar and 3 thoracic instrumentations. The primary pathologies varied among the cases, including 1 case of tuberculous infection, 1 case related to traumatic surgery, 2 cases associated with scoliosis surgery, and 3 cases resulting from spinal metastases surgery. All patients had established risk factors for postoperative infection, except for 1 case of adolescent idiopathic scoliosis, which did not exhibit a clear risk factor. The other scoliosis case was at risk due to neuromuscular scoliosis. Clinical characteristics of the patients are summarized in Table 1.

A bacteriological study, as shown in Table 2, revealed that *Pseudomonas Aeruginosa* was the most common pathogen, found in 3 cases, with 1 case each for *Staphylococcus Aureus* and *Enterobacter Cloacae*, while 2 cases tested

negative for culture. Surprisingly, a histopathology examination revealed that one case had tuberculous infection, characterized by positive granulomatous inflammation.

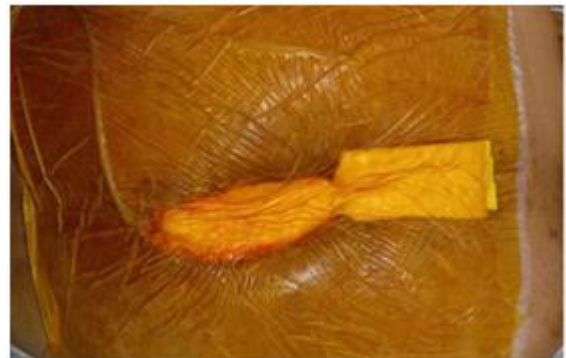

Figure 6: VAC dressing was applied as wound management to facilitate wound healing and eradication of infection.

Based on bacterial culture and drug sensitivity tests, intravenous antibiotics were administered for a minimum of 6 weeks, followed by a 6-week course of oral antibiotic therapy in each infected patient. Serial monitoring of infective parameters was conducted, except for the patient with a positive tuberculosis diagnosis, who started antituberculosis therapy after 3 weeks of antibiotic treatment.

A vacuum-assisted closure dressing was applied for an average duration of 36.8 days (ranging from 10 to 57 days) before secondary wound closure, and 2 patients required 2 or more surgical debridements.

The mean follow-up period was 7.5 months (ranging from 6 to 11 months), and 5 patients achieved wound healing with complete eradication of the infection, while 1 patient developed another deep surgical site infection after 7 months, and 1 patient was lost to subsequent follow-up. Overall, infection was controlled in 5 patients, resulting in a 71% success rate for infection eradication. The current data did not have sufficient statistical power for analysis.

4. Discussion

Postoperative spinal infection is a dreaded complication because it can lead to a prolonged hospital stay and multiple surgeries, as well as short-term and chronic pain, a worsening neurological status, pseudoarthrosis, back deformity as a negative surgical outcome, and even death [3-5].

The best way to control postoperative spinal infection is through prevention, which involves optimizing modifiable risk factors, including malnutrition, smoking, obesity, and intraoperative prophylactic antibiotic use [6]. Extra care should also be taken to manage partially modifiable risk factors, such as extreme age, underlying diabetes mellitus, immunosuppression, spinal trauma surgery, and neuromuscular scoliosis [7]. In addition to these numerous risks, revision surgery is a nonmodifiable risk factor for

Table 1. Clinical characteristic of the seven patients with postoperative spinal infection

Patient	Sex	Age (year)	Onset (month)	Site	Pathology	Risk Factor
1	Female	12	6	Thoracic	Scoliosis	Neuromuscular
2	Female	20	12	Thoracic	Scoliosis	None
3	Female	50	6	Thoracic	Metastasis	Malignancy
4	Female	51	12	Lumbar	Metastasis	Malignancy
5	Male	54	2	Thoracic	Metastasis	Malignancy
6	Male	34	0.5	Lumbar	Fracture	Trauma
7	Male	67	15	Lumbar	Infection	Diabetes

Table 2: The finding of bacteriological and histopathological studies from intraoperative sample

Organism	No of patients	Percentage
Pseudomonas Aeruginosa	3	42
Staphylococcus Aureus	1	14
Enterobacter Cloacae	1	14
Negative for culture	2	28
	(1 case was positive for granulomatous inflammation form HPE)	
HPE, histopathological examination		

postoperative spinal surgery due to the exposure of devitalized soft tissue.

The management of postoperative spinal infection presents a significant challenge, primarily because retaining the implant is essential to maintaining spinal stability and preventing instability-related pain, deformities, and neurological complications. Additionally, the presence of the implant can render the area inaccessible during debridement. In cases of delayed infection, certain bacteria can form a biofilm over the implant, developing resistance to antibiotic treatment and the host's immune response [8]. The risk of infection persisting after debridement while retaining the implant in cases of delayed infection is approximately 50% [9].

To enhance the eradication of biofilm on the implant and wound tissue, and to control infection, it is crucial to visualize the biofilm by the naked eye. Recently, methylene blue has shown promise as an effective disclosing agent for identifying bacterial biofilms on implants and enabling optimal debridement once visualized [10]. The role of methylene blue has been recommended as an adjunct method to provide a visual guide for debridement in cases of periprosthetic joint infection, improving the identification of the causative organism and treatment outcomes [11-12].

To the best of our knowledge and based on our literature searches, none of the previous publications have described the role and outcomes of methylene blue-guided debridement in postoperative spinal infection. We report a series of cases with promising results, but the current data do not have sufficient power for statistical analysis. Further studies are necessary to evaluate the clinical efficacy of methylene blue-guided debridement.

Apart from methylene blue-guided debridement, several adjunctive surgical techniques have been described in the literature. Vacuum-assisted closure devices (VAC) are an established wound management method that facilitates wound healing and the eradication of complex postoperative

spinal infections [13-15]. The placement of antibiotic-containing beads in close suction irrigation techniques has proven to be a successful treatment approach [16-17]. Hyperbaric oxygen therapy has also been suggested to promote wound healing and reduce the biofilm and infection in the treatment of spinal infections [18].

We emphasize the principle of infection eradication while retaining the spinal implant as the primary treatment approach for postoperative spinal infection. This includes surgical debridement as soon as possible in patients with a high index of suspicion, enhancing the identification of the causative pathogen by withholding antibiotics until a positive culture result is obtained from blood, guided aspiration, or intraoperative samples. Initiation of therapeutic antibiotics should be based on sensitivity testing, with serial clinical monitoring to determine the duration of antibiotic treatment. Additionally, adjunctive surgical techniques, including methylene blue-guided debridement and optimized wound management with vacuum-assisted closure devices or flap coverage, are essential.

5. Conclusion

In conclusion, the management of postoperative spinal infection is crucial and challenging, with no universally accepted protocols to establish the diagnosis and guide treatment. Methylene blue-guided debridement is a useful adjunct method for the optimal removal of biofilms and effective debridement to achieve the total eradication of infection and improve outcomes.

References

- [1] Chaudhary SB, Vives MJ, Basra SK, Reiter MF. Postoperative spinal wound infections and postprocedural diskitis. *J Spinal Cord Med.* 2007; 30:441-451.
- [2] Parchi PD, Evangelisti G, Andreani L, et al. Postoperative spine infections. *Orthop Rev (Pavia).* 2015; 7:5900.
- [3] Dowdell J, Brochin R, Kim J, Overley S, Oren J, Freedman B, Cho S. Postoperative Spine Infection: Diagnosis and Management. *Global Spine J.* 2018 Dec;8(4 Suppl):37S-43S.
- [4] Pawar AY, Biswas SK. Postoperative spine infections. *Asian Spine J.* 2016; 10:176-183.
- [5] Sharif S, Gulzar F. Postoperative infections of the spine. *World Spinal Column J.* 2015; 1:19-26.
- [6] Lazennec JY, Fourniols E, Lenoir T, et al; French Spine Surgery Society. Infections in the operated spine: update on risk management and therapeutic

- strategies. *OrthopTraumatol Surg Res.* 2011;97(6 suppl): S107-S116.
- [7] Anderson PA, Savage JW, Vaccaro AR, et al. Prevention of surgical site infection in spine surgery *Neurosurgery.* 2017;80(3S): S114-S123.
- [8] Hall-Stoodley L, Stoodley P. Evolving concepts in biofilm infections. *Cell Microbiol.* 2009;11(7):1034–43.
- [9] Di Silvestre MD, Bakaloudis G, Lolli F, Giacomini S. Late developing infection following posterior fusion for adolescent idiopathic scoliosis. *Eur Spine J.* 2011;20(suppl 1): S121-S127.
- [10] Shaw JD, Brodke DS, Williams DL, Ashton NN. Methylene Blue Is an Effective Disclosing Agent for Identifying Bacterial Biofilms on Orthopaedic Implants. *J Bone Joint Surg Am.* 2020 Oct 21;102(20):1784-179.
- [11] Shaw JD, Miller S, Plourde A, Shaw DL, Wustrack R, Hansen EN. Methylene Blue-Guided Debridement as an Intraoperative Adjunct for the Surgical Treatment of Periprosthetic Joint Infection. *J Arthroplasty.* 2017 Dec;32(12):3718-3723.
- [12] Calanna F, Chen F, Risitano S, et al. Debridement, antibiotic pearls, and retention of the implant (DAPRI): A modified technique for implant retention in total knee arthroplasty PJI treatment. *Journal of Orthopaedic Surgery.* 2019;27(3).
- [13] Canavese F, Gupta S, Krajbich JI, Emara KM. Vacuum-assisted closure for deep infection after spinal instrumentation for scoliosis. *J Bone Joint Surg Br* 2008; 90:377-81.
- [14] Canavese F, Krajbich JI. Use of vacuum assisted closure in instrumented spinal deformities for children with postoperative deep infections. *Indian J Orthop* 2010; 44:177-83.
- [15] Jones GA, Butler J, Lieberman I, Schlenk R. Negative-pressure wound therapy in the treatment of complex postoperative spinal wound infections: Complications and lessons learned using vacuum-assisted closure. *J Neurosurg Spine* 2007; 6:407-11.
- [16] Ender JR, Hester S, Houle PJ, Choudhri HF, Rekito A, McDonnell DE. The use of closed-suction irrigation systems to manage spinal infections. *J Neurosurg Spine* 2005; 3:276-82.
- [17] Rohmiller MT, Akbarnia BA, Raiszadeh K, Raiszadeh K, Canale S. Closed suction irrigation for the treatment of postoperative wound infections following posterior spinal fusion and instrumentation. *Spine* 2010; 35:642-6.
- [18] Larsson A, Uusijaarvi J, Lind F, Gustavsson B, Saraste H. Hyperbaric oxygen in the treatment of postoperative infections in paediatric patients with neuromuscular spine deformity. *Eur Spine J.* 2011; 20:2217-2222.

Author Profile



Norisyam Y earned his Medical Doctor and Master of Orthopedic Surgery from Science University of Malaysia. Currently, he is a trainee in the Fellowship of Spine Surgery of the Ministry of Health Malaysia and is employed at the Spinal Unit of Penang Hospital, Malaysia.

Malaysia.