

Comparative Study to Assess the Outcome of Incisional Hernia Repair by Use of Mesh vs Newer Modality of Treatment with Expanded Hernia Sac

Dr. Narendra G Naik¹, Dr. Sukhdev V Adhikari², Dr. Sanjana S Patil³, Dr. Alauddin Tungekar⁴

¹Associate Professor of General Surgery and consultant Plastic surgeon, MGM Medical College, Navi Mumbai

²Assistant Professor, General Surgery, SIMSRC, Mangalore

³Surgery Resident, MGM Medical College, Navi Mumbai (Corresponding author)

⁴Consultant General Surgeon, MGM Medical College, Navi Mumbai

Abstract: *The main etiopathogenesis of the incisional hernia is poor anatomical repair of operative site, intraperitoneal contamination and poor postoperative mobilisation of the patient. The main difference between the congenital anterior abdominal wall and postoperative Incisional hernia is presence of tissue defect in congenital hernia (1). In the later, there is no tissue loss but there is generalised weakness of anterior abdominal wall muscle tone without any tissue loss. Most surgeons prefer prosthetic reconstructive method (2, 3) to achieve the structural continuity than functional integrity of the anterior abdominal wall. Here an attempt is made to share our experience on newer method of autogenous tissue by expanded hernial sac to reinforce the closed tissue defect and comparing its outcome with the onlay mesh repair.*

Keywords: Incisional hernia; Mesh; Autogenous tissue; Expanded hernial sac

1. Introduction

The basic principle of reconstruction of anterior abdominal wall incisional hernia is to achieve maximum anatomical repair by getting the dehiscence edge of the original or previous surgically explored wound by reducing contents of hernial sac and then reinforcing it by autogenous or prosthetic material to produce fibroconnective network in the reinforced structure (1, 2, 5). The reinforcing structure does not strengthen the abdominal wall but the invaginating fibroconnective network strengthens and improves tone of the abdominal wall. Methods of autogenous tissue used in literature study are reported in the form of fascia lata, plication and double breasting of transversalis fascia in inguinal hernia repair and components of anatomic separation technique by Ramirez (1). In this comparative study an attempt is made to introduce newer concept of autogenous tissue by use of Expanded hernial sac as a reinforcing material.

Aims and Objectives

- 1) To evaluate surgical outcome of patient operated by use of mesh vs expanded hernia sac in cases of incisional hernias
- 2) To compare the advantages and disadvantages of newer modality of repair of incisional hernia by expanded hernia sac with regular meshplasty.

2. Materials and Method

Study Design: Prospective comparative randomised study.

Study Setting: This was a prospective, comparative, randomised study, conducted on patients who were diagnosed with incisional hernia and admitted through

Outpatient Department of MGM Medical College and Hospital, Navi Mumbai from February 2023 to October 2023, included in the study after taking ethical clearance from Institutional Ethics Committee.

Study Period: February 2023 to October 2023

Study Population: Patients admitted in General Surgery Ward, MGM Hospital, Navi Mumbai, with incisional hernia during this period

Sample Size: 40.

Patients who met the inclusion criteria were divided by chit method into two Groups of 20 each. Group A and Group B corresponded with incisional hernia repair by mesh and new modality using expanded hernial sac respectively.

3. Methodology

- Complete clinical history and necessary pre operative investigations were recorded.
- Written Informed consent was taken from the patient and/or the relatives in the language best understood by them.
- Follow up of every patient was done on post operative day 7, 14, 30 days and after 2 months. Outcome of surgery was assessed by contrast CT abdomen on last visit.

Inclusion Criteria:

All patients above 18 years of age and diagnosed with incisional hernia for the first time at the same site on clinical and radiological examination with defect more than or equal to 4 cm as per pre operative CT findings who were willing to

Volume 12 Issue 11, November 2023

www.ijsr.net

Licensed Under Creative Commons Attribution CC BY

participate in this study and give consent for either of the two procedures i. e, incisional hernia repair by mesh or expanded hernial sac.

- 4) Patients under 18years age.
- 5) Pregnant woman.
- 6) Patients unwilling to participate and give consent for either of the two procedures that is incisional hernia repair by expanded hernia sac or use of mesh.

Exclusion Criteria:

- 1) Patients diagnosed with complicated incisional hernia - obstructed, incarcerated or strangulated.
- 2) All recurrent incisional hernias.
- 3) Hernia defect <4 cm as per pre operative CT findings.

4. Observation and Results

Table 1: Comparison between incisional hernia repair by mesh (Group - A) and expanded hernia sac (Group - B)

Particulars	Repair by mesh (Group - A)	Repair by Expanded hernia sac (Group - B)
Recurrence	5%	0%
Flap Necrosis	10%	5%
Infection without flap edge necrosis	15%	10%
Seroma formation	15%	5%
Wound dehiscence	5%	5%
Post surgical cosmesis	60%	100%

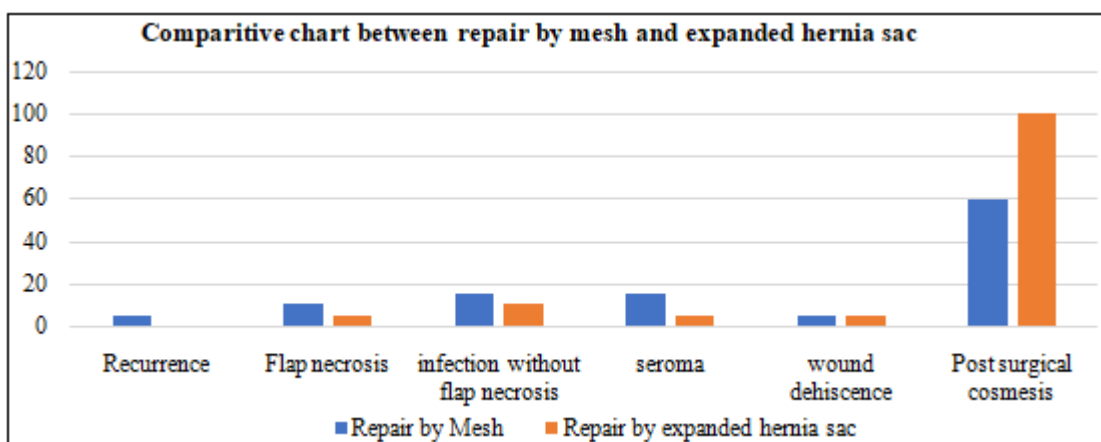


Table 2: Comparison between Mean duration of days of drain and suture removal in days for repair by mesh and repair by expanded hernia sac

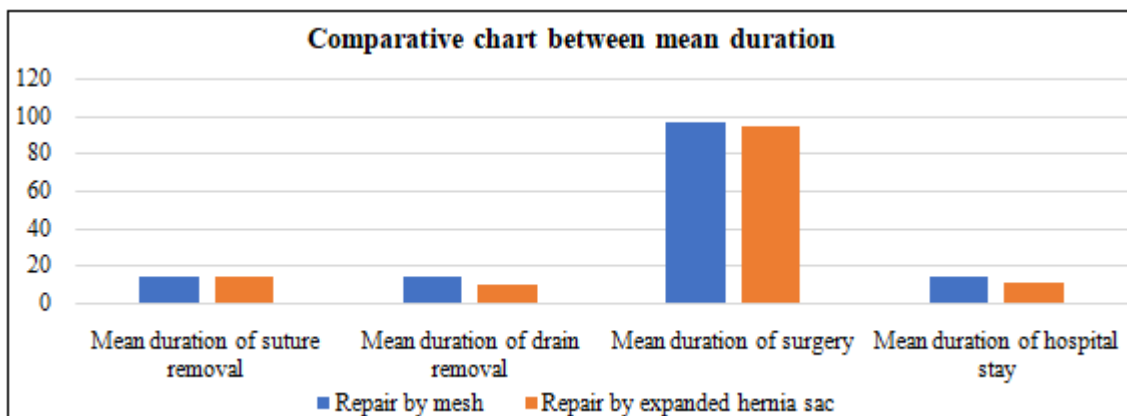
Particulars	Repair by mesh (Group - A)	Repair by Expanded hernia sac (Group - B)
Mean duration of suture removal	14	14
Mean duration of drain removal	14	10

Table 3: Comparison between Mean duration of surgery in minutes for repair by mesh and repair by expanded hernia sac

Particulars	Repair by mesh (Group - A)	Repair by Expanded hernia sac (Group - B)
Mean duration of surgery	97.25	94.20

Table 4: Comparison between Mean duration of hospital stay in days (day of surgery to day of discharge) for repair by mesh and repair by expanded hernia sac

Particulars	Repair by mesh (Group - A)	Repair by Expanded hernia sac (Group - B)
Mean duration of hospital stay	14	11



The operative techniques were compared using the following parameters - Recurrence, flap necrosis, infection without flap necrosis, seroma, wound dehiscence and post surgical cosmesis.

Recurrence was observed in one patient (5%) from Group A and none (0%) from Group B.

Raised flap edge - necrosis was observed in two patients (10%) from Group A and one patient (5%) from Group B. It was treated with suitable dressing and secondary suturing.

Post operative Infection without flap necrosis was observed in 3 patients (15%) from Group A and 2 patients (10%) from Group B and was treated with suitable antibiotics. Out of these 3 patients from Group A, one developed infection of the mesh which was surgically removed and treated with suitable antibiotics. This led to increased hospital stay and economic burden on the patient.

Seroma developed in 3 patients (15%) from Group A and one patient (5%) from Group B.

Wound dehiscence was observed in one case (5%) each from both groups and was treated with secondary suturing and antibiotics.

12 patients (60%) from Group A and all patients (100%) from Group B had good post operative cosmetic results in terms of body contour and scar satisfaction (Figures 2 and 3). One case from Group A had recurrence and an ugly scar due to infected mesh.

In Group A, drain was removed on 14th day and in Group B, on 10th day postoperatively.

Mean duration of suture removal in both groups was 14 days.

Mean duration of surgery for Group A was 97.25 minutes and for Group B was 94.20 minutes.

Mean duration of hospital stay i. e, from day of surgery to day of discharge, for Group A was 14 days and for Group B, it was 11 days.

5. Discussion

Incisional hernia (43%) are the most common of all ventral hernias especially around 50 years age. Obese patients, especially females, are associated with a higher rate of postoperative complications like wound infection, wound dehiscence and seroma formation (2, 5). Incisional hernias are usually common in lower midline incisions (34.9%) and after gynecological surgery (55.81%). About 70% of the patients present within three years of previous surgery.

Studies have shown that the incisional hernia becomes evident within the first year of surgery but patient presents with hernial swelling as late as 10 years or beyond (19). Two main elements predisposing to incisional hernia are infection and mechanical factors. Precise assessment of these elements can guide the surgeon to strategize well (6).

Lower abdomen has a weak anatomical configuration wherein the linea alba continues to remain same but

posterior rectus sheath ceases to exist midway between the umbilicus and pubic symphysis (3, 8). Linea alba too, is weaker infraumbilically as compared to supraumbilical portion. Maximum point of weakness in the linea alba is usually in the periumbilical region. It's this area where herniation takes place. Subsequently, the defect enlarges in direction of the line of least resistance. Therefore it's of utmost importance to reconstitute a strong midline during repair of midline incisional hernias for a successful long lasting outcome (7, 8, 10).

Reconstruction of massive midline abdominal wall defects as a result of intra - abdominal catastrophes has long challenged the surgeon. Previously, lack of awareness of usage of autogenous tissue often forced the surgeon to resort to synthetic materials, which may be complicated by adhesions, enterocutaneous fistulas, and infection (10). Introduction of the "components of anatomic separation" technique by Ramirez et al (1, 10) in 1990 allowed for autogenous reconstruction using bipedicle rectus flaps. This technique was far superior to any previous option but it had its limitations.

All repairs of incisional hernia are performed through scar tissue (2). Thus primary repair of incisional hernia is equivalent to herniorrhaphy for recurrent inguinal hernias with its increased risk of failure. Inadequate wound healing due to wound dehiscence at operative site causes abdominal wall weakness subsequently developing an incisional hernia. Even though the skin portion of previous wound is routinely removed, the musculoaponeurotic scar is not removed for fear of increased suture tension in subsequent repair (2). Since infection with necrosis is a strong risk factor for recurrence, it adds to the degree of scarring, as does the persistence of the original sutures (foreign body reaction).

Hernia defect along with contents was measured on firstly preoperative ultrasound and later contrast CT, in all the patients. In our study, the most common primary etiologies of incisional hernia were post - exploratory laparotomy, LSCS, Total abdominal hysterectomy or tubal ligation. Multiple factors like multi - parity, decreased abdominal muscle tone, history of gynecological surgeries via lower midline incision, etc., predispose females to ventral hernias. Diabetes mellitus, obesity and smoking are associated with high percentage of postoperative hernias. Several pathogenic mechanisms like peripheral tissue hypoxia, reduced collagen type I to type III ratio (23) and degradation of connective tissue caused by an imbalance between proteases and their inhibitors play a vital role (3, 4, 5). A study conducted by Toms et al. concluded that incisional hernias were more common following midline incision through the relatively a vascular line and less common following transverse incision where muscle splitting approaches were used.

6. Operating Techniques

Expanded sac method:

An elliptical incision over the previous scar of operative site was made. Skin flaps were separated from anterior rectus sheath and raised upto lateral abdominal wall to expose the peritoneum over the hernial sac. Hernial sac was identified and dissected upto preperitoneal fat and transfixed. The

expanded sac was then used as autologous tissue for reinforcement of repaired hernial site with plication of linea alba by monofilament polyamide No 1 (Figure 1). The aim of this repair was to reconstitute the original anatomical

structure of rectus sheath. Skin was closed with an underlying suction drain inserted into the subcutaneous space.




Figure 1: Incisional hernia repair - intraoperative picture of a case of 56 year female operated by expanded sac method.

Meshplasty:

After incising the subcutaneous tissue, hernial sac was identified and dissected up to the preperitoneal fat, transected and redundant portion of sac was excised. Onlay Mesh was placed on reconstructed defect in the anterior rectus sheath. The mesh was secured with interrupted 2/0 polypropylene sutures (7). Skin was closed with an underlying suction drain inserted into the subcutaneous space.

Follow up of every patient was done on post operative day 7, 14, 30 days and after 2 months in both groups A and B, to assess outcome of the surgery. Post operative Contrast CT scan was done to assess strength and healing of the operative site. Patients were advised pressure garments for 6 months to prevent recurrence for both groups.

Our results were comparable to a previous study done by Jaykar et al. Duration of surgery for onlay mesh hernioplasty was 97.25 minutes in our study and 94.20 minutes for expanded sac placement. In the present study, it was found that 5% of cases developed postoperative seroma, 10% had surgical wound infection and 5% had wound dehiscence.

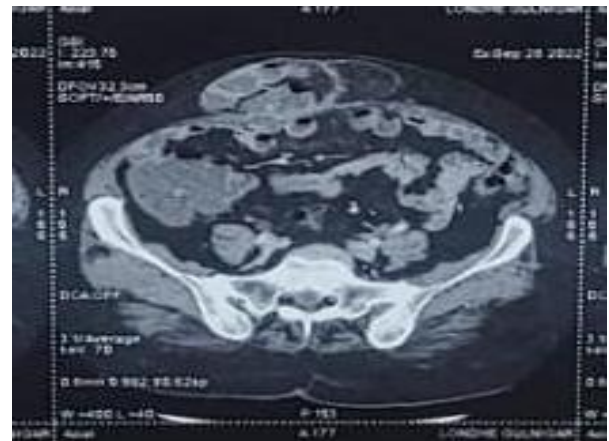


Figure 2 (b)

Fig 2a and 2b - Case of 65 year old female showing clinical picture of pre operative incisional hernia and CT scan

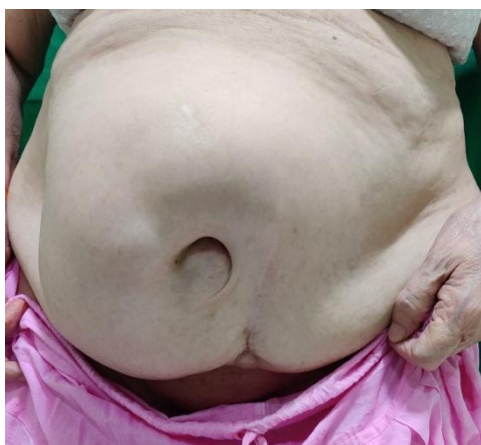

Figure 2 (a)

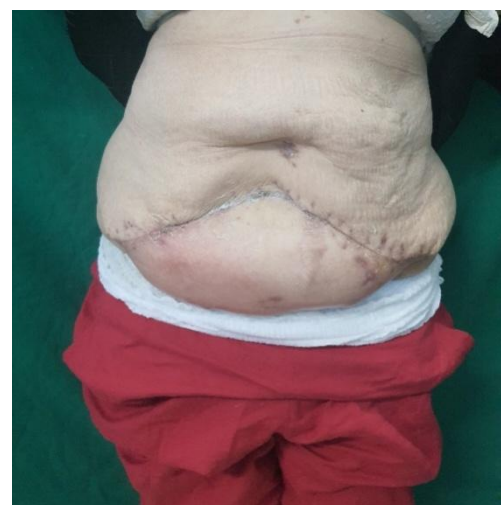

Figure 3 (a)

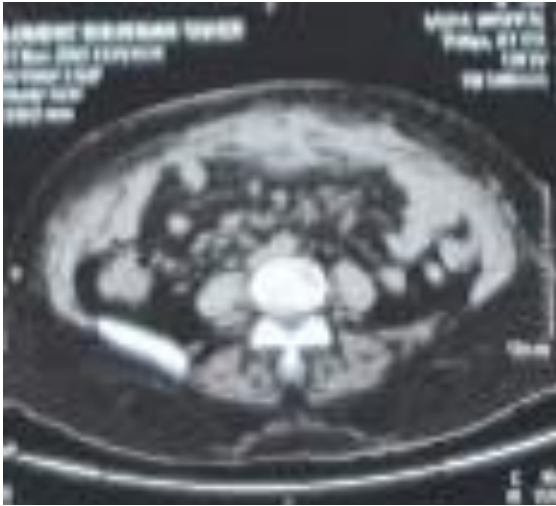

Figure 3 (b)

Fig 3a and 3b: showing post operative picture and CT scan of incisional hernia repair done by expanded hernial sac

7. Conclusion

From our study, we conclude that autologous tissue repair is a good method of choice for low socioeconomic status or in complicated cases as compared to meshplasty. The use of autogenous tissue for repair of incisional hernia leads to lesser surgical site infection, shorter hospital stay, and an early return to work. In our study, post operative contrast CT scan was used as the parameter to assess strength and healing of site of incisional hernia repair by expanded sac method. Further animal study may be required in the form of histopathological examination to understand the exact mechanism of acceptance of autogenous tissue like expanded hernial sac.

References

- [1] Incisional Hernia Repair by Preperitoneal (Sublay) Mesh Implantation Fakhar Hameed, Bashir Ahmed, Asrar Ahmed, Riaz Hussain Dab, Dilawaiz
- [2] Mudge M, Hughes LE. Incisional hernia: a 10 year prospective study of incidence and attitudes. *Br J. Surg* 1985 Jan; 72 (1): 70 - 71.
- [3] massive midline abdominal wall hernia. L Scott Ennis¹, Jeffrey S Young, Thomas J Gampper, David B Drake. PMID: 14509319.
- [4] Complications of the Suture Repair of Incisional Hernia R. C. Read.
- [5] Luijendijk RW, Hop WC, van den Tol MP, et al. A comparison of suture repair with mesh repair for incisional hernia. *N Engl J Med* 2000; 343: 392 - 8.
- [6] A Prospective Observational Study of Ventral Hernia 1 2 Gauri S. Jadhav , Geet R. Adhikari , Rajashree S. Purohit.
- [7] Jensen JA, Goodson WH, Hopf HW, Hunt TK: Cigarette smoking decreases tissue oxygen. *Arch Surg*.1991, 126: 1131 - 1134. doi: 10.1001/archsurg.1991.01410330093013.
- [8] Klinge U, Si ZY, Zheng H, Schumpelick V, Bhardwaj RS, Klosterhalfen B: Abnormal collagen I to III distribution in the skin of patients with incisional hernia. *EurSurg Res*.2000, 32: 43 - 46. doi: 10.1159/000008740.
- [9] Combined Tissue and Mesh Repair for Midline Incisional Hernia (A Study of 15 Cases) Authors Dr. Ketan Vagholkar¹, Dr. Abhijit Budhkar².
- [10] Biocellulose for Incisional Hernia Repair—An Experimental Pilot Study Falk Rauchfuß^{1, *}, Julian Helble¹, Johanna Bruns¹, Olaf Dirsch^{2, 3}, Uta Dahmen², Michael Ardelt¹, Utz Settmacher¹ and Hubert Scheuerlein^{1, 4}.
- [11] Bucknell TE, Cox PJ, Ellis H. Burst abdomen and incisional hernia: a prospective study of 1129 laparotomies. *Br MJ (Clin Res Ed)*.1982 Mar 27; 284 (6320): 931 - 933.
- [12] Surgical mesh for ventral incisional hernia repairs: Understanding mesh design Ali Rastegarpour MD¹, Michael Cheung MD¹, Madhurima Vardhan MS², Mohamed M Ibrahim MD¹, Charles E Butler MD FACS³, Howard Levinson MD¹.
- [13] Sauerland S, Walgenbach M, Habermalz B, Seiler CM, Miseriz M. Laparoscopic versus open surgical technique for ventral or insicional hernia repair. *Cochrane Database Sys Rev*.2011 Mar 16; 3: CD 007781. hernias. *J R CollSurgEdinb* 1998 Feb; 43 (1): 29 - 30
- [14] Usher FC. New technique for repairing incisional hernias with marlex mesh. *Am J Surg* 1979 Nov; 138 (5): 740 - 741.
- [15] Browse NL, Hurst P. Repair of long, large midline incisional hernias using reflected flaps of anterior rectus sheath reinforced with marlex mesh. *Am J Surg* 1979 Nov; 138 (5): 738 - 739.
- [16] Gurusamy KS, Allen VB. Wound drains after incisional hernia repair. *Cochrane database Sys Rev*.2013 Dec 17; 12: CD 005570.
- [17] Conde - Green A, Chung TL, Holton LH 3rd, Hui Chu HG, Zhu Y, Wang H, Zahiri H, Singh DP. Incisional negative pressure wound therapy versus conventional dressings following abdominal wall reconstruction: a comparative study. *Ann PlastSurg*.2013 Oct; 71(94): 394 - 7.
- [18] Jenkins TPN. Incisional hernia repair: a mechanical approach. *Br J Surg* 1980; 67: 335 - 336.
- [19] Vagholkar K. Negative pressure wound therapy: A promising weapon in the therapeutic management armamentarium. *J of Medical Science and Clinical research*.2014 Jun; 2 (6): 1314 - 19.
- [20] Satterwhite TS, Miri S, Chung C, Spain D, Lorenz HP, Lee GK. Outcomes of complex abdominal herniorrhaphy: experience with 106 patients. *Ann PlastSurg*.2012 Apr; 68 (4): 382 - 8.
- [21] Xing L, Culbertson EJ, Wen Y, Franz MG. Early laparotomy wound failure as the mechanism for incisional hernia formation. *J Surg Res* 2013; 182: e35 - 42.
- [22] Nguyen MT, Berger RL, Hicks SC, et al. Comparison of outcomes of synthetic mesh vs suture repair of elective primary ventral herniorrhaphy: A systematic review and meta - analysis. *JAMA Surg* 2014; 149: 415 - 21.
- [23] Major complications and mortality after ventral hernia repair: an eleven - year Swedish nationwide cohort

study MikaelLindmark*, ThyraLöwenmark, Karin Strigård and Ulf Gunnarsson.

- [24] Al Chalabi H, Larkin J, Mehigan B, McCormick P. A systematic review of laparoscopic versus open abdominal incisional hernia repair, with meta - analysis of randomized controlled trials. *Int J Surg.*2015; 20: 65–74.
- [25] Helgstrand F. National results after ventral hernia repair. *Dan Med J.*2016; 63.
- [26] Köckerling F, Sheen AJ, Berrevoet F, Campanelli G, Cuccurullo D, Fortelny R, et al. The reality of general surgery training and increased complexity of abdominal wall hernia surgery. *Hernia.*2019; 23: 1081–91.
- [27] Kroese LF, Gillion JF, Jeekel J, Kleinrensink GJ, Lange JF. Primary and incisional ventral hernias are different in terms of patient characteristics and postoperative complications—a prospective cohort study of 4, 565 patients. *Int J Surg.*2018; 51: 114–9.
- [28] Ahonen - Siirtola M, Vironen J, Makela J, Paaanan H. Surgery - related complications of ventral hernia reported to the Finnish Patient Insurance Centre. *Scand J Surg.*2015; 104: 66–71.
- [29] Verstoep L, de Smet GHJ, Sneiders D, Kroese LF, Kleinrensink GJ, Lange JF, et al. Hernia width explains differences in outcomes between primary and incisional hernias: a prospective cohort study of 9159 patients. *Hernia.*2021; 25: 463–9.
- [30] Luijendijk RW, Hop WC, van den Tol MP, de Lange DC, Braaksma MM, JN IJ, et al. A comparison of suture repair with mesh repair for incisional hernia. *N Engl J Med.*2000; 343: 392–8.