

A Rare Case of Isolated Hydatid Cyst of Breast

Dr. Pratiksha Badapurkar¹, Dr. Ajay Jungare², Dr. Suwarna Patil³, Dr. Dilip Sarate⁴

¹Postgraduate Student, Department of Pathology, GMC Akola

^{2,3}Associate Professor, Department of Pathology, GMC Akola

⁴Associate Professor and H. O. D. Department of Pathology, GMC Akola

Abstract: *Introduction:* Hydatid cyst in the breast is very rare and unusual for its location. Reported incidence of hydatid cyst in the breast is 0.27% in the literature. *Objective:* Preoperative diagnosis may be performed using fine - needle aspiration cytology, which also minimizes the risk of intraoperative rupture. *Case report:* We report the case of a 38 - year - old woman who was diagnosed with a hydatid cyst in breast using fine - needle aspiration cytology before surgery. *Conclusion:* Fine - needle aspiration cytology is an accurate and safe technique that can allow surgery to be avoided, especially in older patients or patients with high surgical risk.

Keywords: Breast lump, FNAC, Hydatid cyst, Echinococcus granulosus

1. Introduction

Hydatid cyst is a zoonotic infection that results from tissue infestation with the larval stage of the parasite *Echinococcus*. *Echinococcus granulosus* being the commonest species¹. It is endemic in sheep and cattle raising communities. The definitive hosts of the parasite are the dogs whereas the intermediate hosts are sheep and other ruminants. Humans are the accidental intermediate hosts². Hydatid cysts can affect all tissues and viscera of the body, with liver and lungs commonly involved; kidneys, pancreas, bladder, spleen ovary, brain, heart, thyroid, bone and muscles are rarely affected. Breast is also rarely involved accounting for 0.27% of cases.^{1,3}

Herein, we report a case of cytologically diagnosed isolated hydatid cyst of breast masquerading breast fibroadenoma and review the literature.

2. Case Report

A 38 year old female presented with gradually progressive painless lump in the left breast since 4 years. Breast local examination revealed a lump of size 3 x 3cm in the upper

outer quadrant of left breast which was firm in consistency and freely mobile. The mass was not fixed to underlying tissue or overlying skin. She had no associated pain, nipple discharge, skin discolouration, fever or family history of breast cancer. Also no association with menstrual cycle was noted. Nipple areola complex was normal and no axillary lymphadenopathy. Contralateral breast and axilla was normal. Systemic examination findings were unremarkable. Routine laboratory investigations including complete blood count and biochemistry were normal. Radiological examinations like chest radiograph and abdominal ultrasound were normal. In view of clinical diagnosis of breast fibroadenoma, fine - needle aspiration cytology (FNAC) was advised in our patient.

FNAC was performed and microscopy from smears of the breast aspirate shows acellular lamellated eosinophilic membrane fragments, scolices along with refractile hooklets against proteinaceous background. No complications of FNAC were observed in our patient. FNAC diagnosis of hydatid cyst of breast was offered. Patient underwent lumpectomy after medical treatment with albendazole for 2 weeks

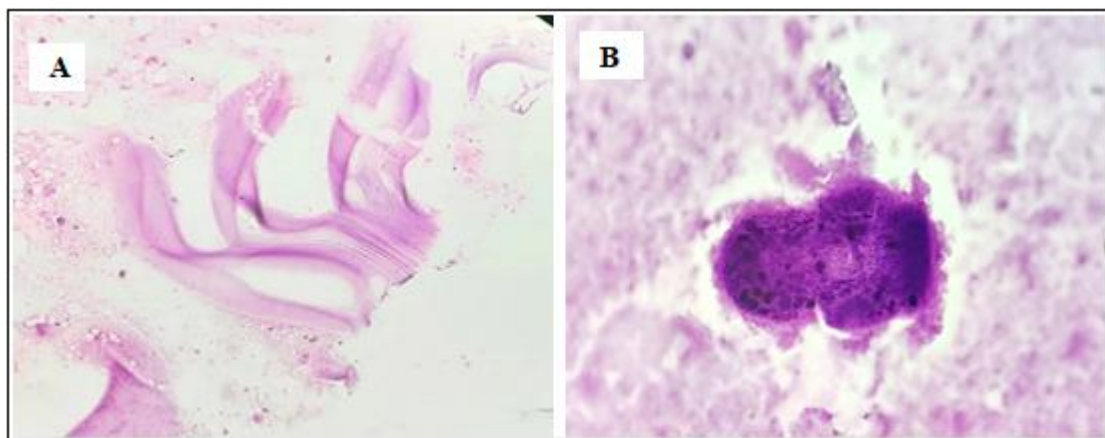


Figure 1: (A) Acellular lamellated membrane fragments (HE, 10x) (B) Scolex (HE, 40x)

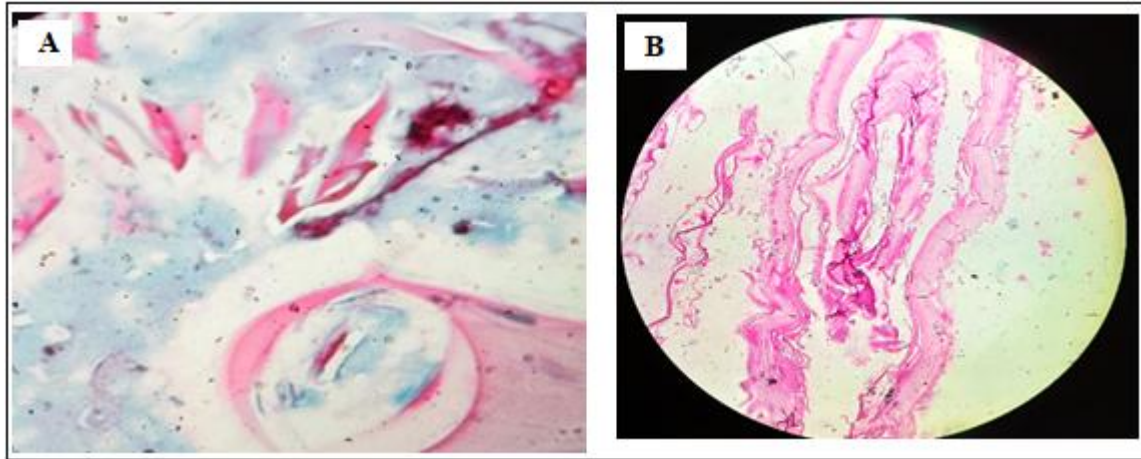


Figure 2: A) Multiple scattered hooklets (PAP, 40x) B) Photomicrograph of Histopathology slide showing membranous cyst wall of hydatid cyst with hooklets and eosinophils in the background

Grossly lumpectomy specimen measured 2.5 cm × 2 cm × 1.5 cm. Externally well - circumscribed lump. Cut section showed whitish cyst filled with a whitish membranous material.

Histopathological examination showed cyst wall comprising of outer fibrous laminar layer and focal inner germinal layer. The cyst lumen showed scolices and hooklets. The surrounding fibroadipose tissue and breast parenchyma showed moderate infiltration of eosinophils, lymphocytes, and focal area of foreign body giant cells reaction. Histopathological findings confirmed the cytological diagnosis of hydatid cyst of breast. Postoperative recovery was uneventful with no similar lesion at other sites during the last 5 months' follow - up.

3. Discussion

Hydatid disease is an endemic illness in many parts of the world (the Mediterranean, South America, North and East Africa, Australasia, Russia and China) and, due to immigration and travel, its presence in non - endemic areas is possible ⁴.

Hydatid disease is a cyclozoonosis caused by the larval (metacestode) stages of cestodes (flat worms) belonging to the genus *Echinococcus* and the family Taeniidae. The disease exists in two forms: the larval stage (metacestode) and the adult stage (tenia)⁵. The adult *E. granulosus* is a worm, when infected it produces eggs that are passed in stool. Eggs ingested by intermediate hosts like cows, sheep, and humans, liberate an embryo in the duodenum, which penetrates intestinal mucosa and enters the portal circulation.^{5, 6} The liver acts as a first filter and stops about 75%, while lungs, the second filter, stop about 10% and only 15% embryos are free to develop cysts in other organs of the body.⁷ Breast can be a primary site or part of disseminated hydatidosis.⁸

Clinically, hydatid cyst of breast usually present with a painless, slowly increasing lump in the breast of long duration without axillary lymphadenopathy. It affects generally women in the age group of 30 - 50 years. Patient with breast hydatid presents with painless breast lump which might mimic fibroadenoma, phyllodes tumor, chronic

abscesses, or even carcinoma.⁸ In our case also hydatid disease was not suspected and clinical diagnosis of breast fibroadenoma was made.

Mammography and ultrasound may be helpful but not conclusive because of the resemblance of radiological findings with that of benign cystic lesion and breast abscess. Mammography may show circumscribed mass lesion with ring - shaped structures inside the mass.⁹

Diagnosis of hydatid cyst of breast is made usually postoperatively in the histopathological examination of breast lump. Preoperative diagnosis can be made on FNAC of breast lump showing refractile hooklets and scolices. But due to risk of anaphylactic reaction it is not recommended by many authors in suspected cases of hydatid disease of breast. However, review of literature also showed no complications in preoperative diagnosis of hydatid cyst by FNAC in few studies.^{7, 10}

The treatment of choice of hydatid cyst of breast is complete surgical excision of cyst and its contents without spillage into the surrounding tissue. Preoperative chemotherapy with albendazole may reduce the recurrence of disease. The recurrence rate due to incomplete removal or unidentified cyst has remained between 2% and 25%.¹¹

4. Conclusion

Hydatid cyst in the breast is very rare and unusual for its location. High suspicion of this entity should be there in the differential diagnosis in the evaluation of breast lump in endemic areas as well as in migrant population. FNAC can provide a safe, fast, inexpensive preoperative diagnosis, minimizing the risk of intraoperative rupture.

Financial support and sponsorship

Nil

Conflicts of interest

There are no conflicts of interest.

References

- [1] Mujawar P, Suryawanshi KH, Nikumbh DB. Cytodiagnosis of isolated primary hydatid cyst of breast masquerading as a breast neoplasm: A rare case report. *J Cytol.*2015 Oct - Dec; 32 (4): 270 - 2.
- [2] Cancelo, M. J., Martín, M. & Mendoza, N. Preoperative diagnosis of a breast hydatid cyst using fine - needle aspiration cytology: a case report and review of the literature. *J Med Case Reports* 6, 293 (2012).
- [3] Meshram N, Kamal F, Gadkari R. Hydatid cyst of breast: unwelcome guest at unusual site; a case report and review of literature. *International Journal of Contemporary Medical Research* 2021; 8 (1): A12 - A16
- [4] Richter J, Orhun A, Grüner B, Müller - Stöver I, Reuter S, Romig T, Häussinger D, Kern P: Autochthonous cystic echinococcosis in patients who grew up in Germany. *Euro Surveill.*2009, 14 (22): pii: 19229 -
- [5] Garcia G., Shimizu R., Bruckner D. Sinus tract extension of liver hydatid cyst and recovery of diagnostic hooklets in sputum. *Am J Clin Pathol.*1986; 85: 519–521.
- [6] Langer J. C., Rose D. B., Keystone J. S., Taylor B. R., Langer B. Diagnosis and management of hydatid disease of the liver. *Ann Surg.*1983; 199 (4): 412–417.
- [7] Das D. K., Choudhury U. An unusual breast lump. *JIMA.*2002; 100 (5): 327–328.
- [8] Kumar A, Kumar A, Gaurav K, Chandra G, Tiwary AK, Bhagat S, Sarawgi M. A rare case of isolated hydatid cyst of breast. *Int J Surg Case Rep.*2015; 7C: 115 - 8.
- [9] Vega A, Ortega E, Cavada A, Garijo F. Hydatid cyst of the breast: Mammographic findings. *AJR Am J Roentgenol.*1994; 162: 825–6.
- [10] Mirdha BR, Biswas A. Echinococcosis: Presenting as palpable lumps of breast. *Indian J Chest Dis Allied Sci.*2001; 43: 239–41.
- [11] Yaqoob N, Kayani N, Shamim MS. Mammary echinococcosis: Two cases and literature review. *J Pak Med Assoc.*2004; 54: 283–4.