

Value of Contrast Enhanced CT in Detecting Active Haemorrhage in Patients with Blunt Abdominal or Pelvic Trauma

Tapan Pandey, Jahanvi Singh, Sumedh Meshram, Ashish Asutkar

Abstract: *Objectives-To evaluate the use of contrast enhanced CT to show sites of active haemorrhage as a guide for surgical or angiographic treatment in patients sustaining blunt abdominal or pelvic trauma. Place-Department of Radiodiagnosis, MGIMS Sevagram. Materials and methods-25 CT scans were reviewed to compare the location of extravasated contrast material (haemorrhage) detected on CT with the sites of active haemorrhage determined by surgery (fifteen) and angiography (five). The five remaining patients had no additional study done. The attenuation of extravasated contrast on CT was compared with CT attenuation of adjacent artery. Attenuation of clotted blood within the abdomen or pelvis was also measured. Results-The location of extravasation of contrast material as shown on CT scan included the spleen (seven), pelvis (six), retroperitoneum (four), kidney (four), liver (two) and adrenal gland (one). One patient had venous extravasation. The origin of bleeding was confirmed in all cases to correspond to the anatomic region of extravasated contrast on CT. The CT attenuation of active haemorrhage ranged from 75 to 350 HU (Mean 144 HU). Clotted blood revealed CT attenuation range of 45 to 65 HU (Mean 55), significantly differing from values of active haemorrhage. Conclusion-Active extravasation of contrast material can be distinguished from clotted blood by measuring CT attenuation. CT accurately shows the anatomical location of bleeding and indicates the probable vascular origin.*

Keywords: Haemorrhage, Contrast extravasation, Computed Tomography, CT attenuation, Trauma

1. Objectives

- To evaluate the use of contrast enhanced CT to show sites of active haemorrhage.
- To distinguish between active haemorrhage and clotted blood.

2. Introduction

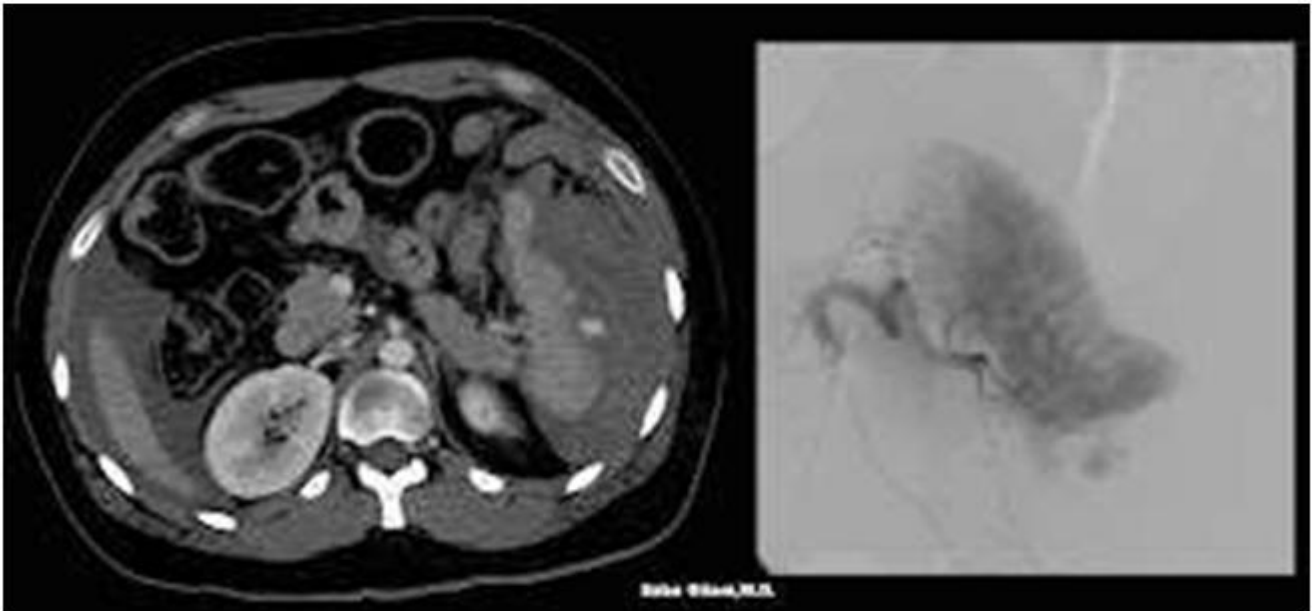
- FAST CT scanning helps in identification of visceral injury and hemoperitoneum resulting from blunt trauma.
- IV contrast-enhanced CT is even more sensitive for detecting solid visceral injury.
- The high attenuation of intravascular contrast material aids in the imaging of visceral injury by increasing the attenuation of normal parenchyma and also permits sites of active hemorrhage to be visualized.
- Identification of the exact anatomic site on sites of active hemorrhage, the presence and extent of abdominal or pelvic visceral injury, and the quantity of hemoperitoneum influences the decision about whether to use surgical intervention, angiographic intervention, or both.

3. Materials and Methods

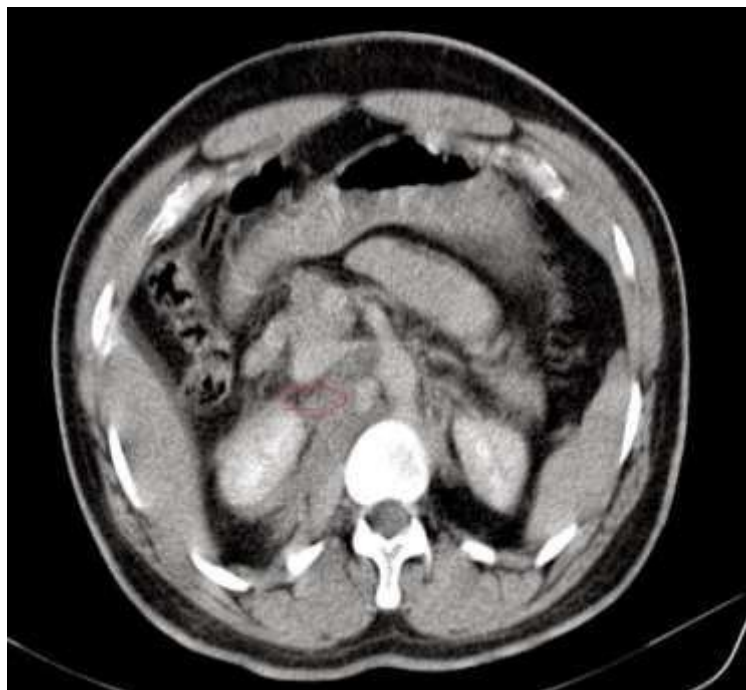Study design: Prospective observational study conducted from January 2022 to October 2022.

Place: Department of Radiodiagnosis, MGIMS Sevagram.

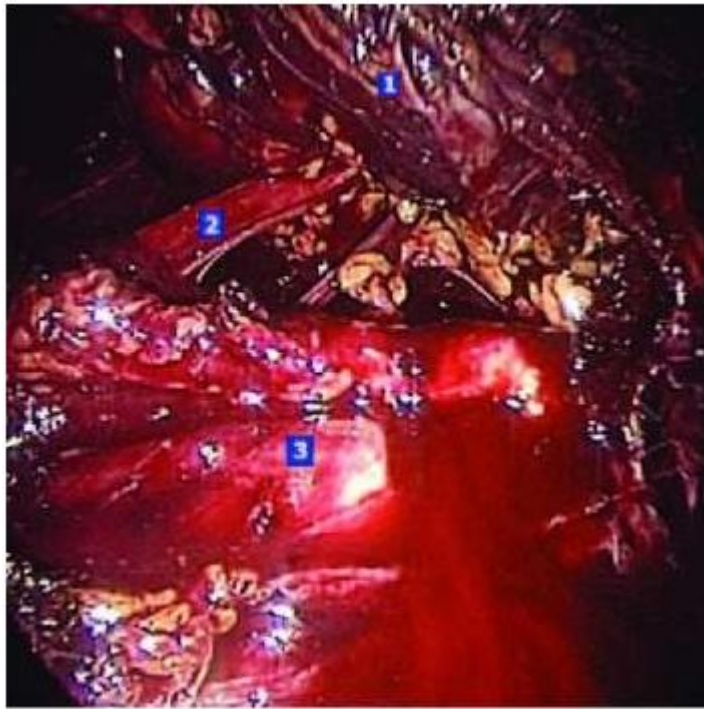
- Twenty five patients with blunt abdominal or pelvic trauma who were judged by the clinical admitting service to be stable to undergo CT scan were imaged with General Electronics Revolution 256 slice CT scan machine.
- Initially plane scan was done followed by contrast enhanced CT with the use of non ionic iodinated contrast material (Omnipaque 350) 1ml/kg dosage with injection rate of 1 ml/sec.
- Oral and rectal were administered to opacify the bowel.
- Delayed scan was taken after 10 mins.
- The abdomen was scanned from the lower lung base to the iliac crest and through the pelvis.
- The CT attenuation values of extravasated contrast material were measured with a region-of-interest (AOI) cursor and compared with attenuation values of contrast material measured with the same ROI cursor placed over an adjacent major artery or the abdominal aorta.
- To determine the range and mean of attenuation values of hematoma on our CT scanner, the attenuation values of clotted blood were measured with an identical ROI cursor on 25 other patients with blunt trauma who had intraabdominal or pelvic hematoma shown on CT scans obtained by using scanning methods identical to those used in the study group.



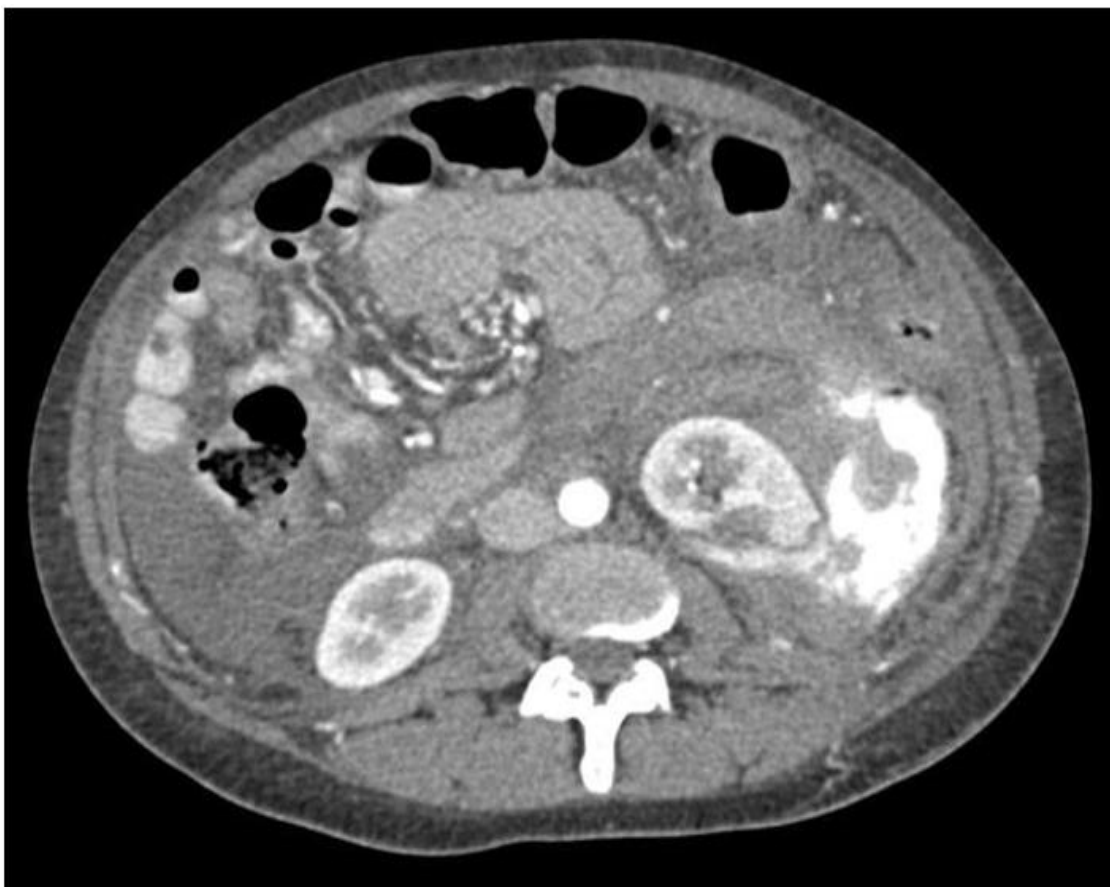
- The above CECT demonstrates a large subcapsular splenic hematoma causing compression and medial deviation of the spleen. A focus of high density within this hematoma represents active contrast extravasation.
- Angiogram of the splenic artery shows a blush of contrast near the inferior splenic pole



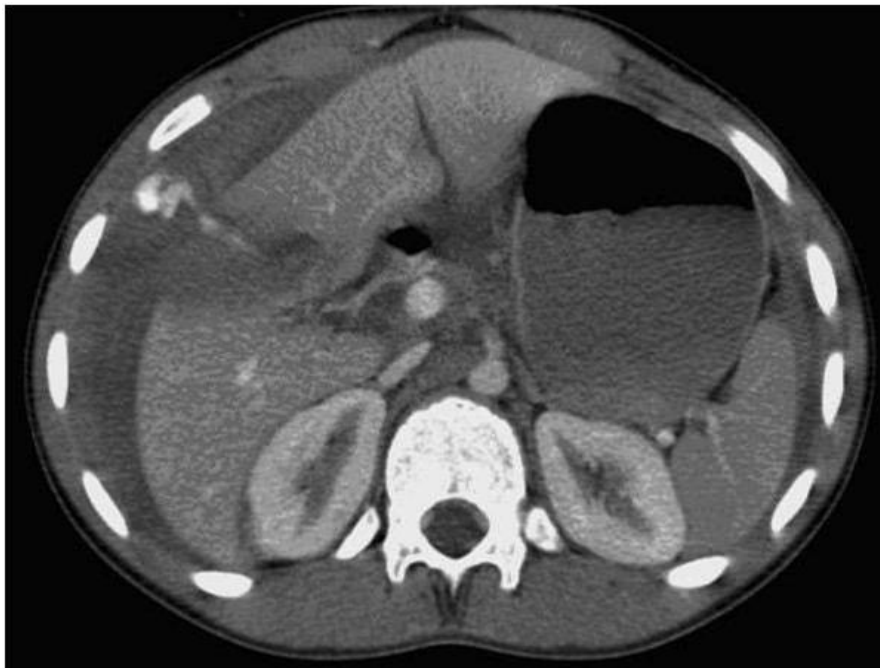- Image demonstrates small area of contrast extravasation from the lateral margin of abdominal aorta with retroperitoneal haemorrhage.



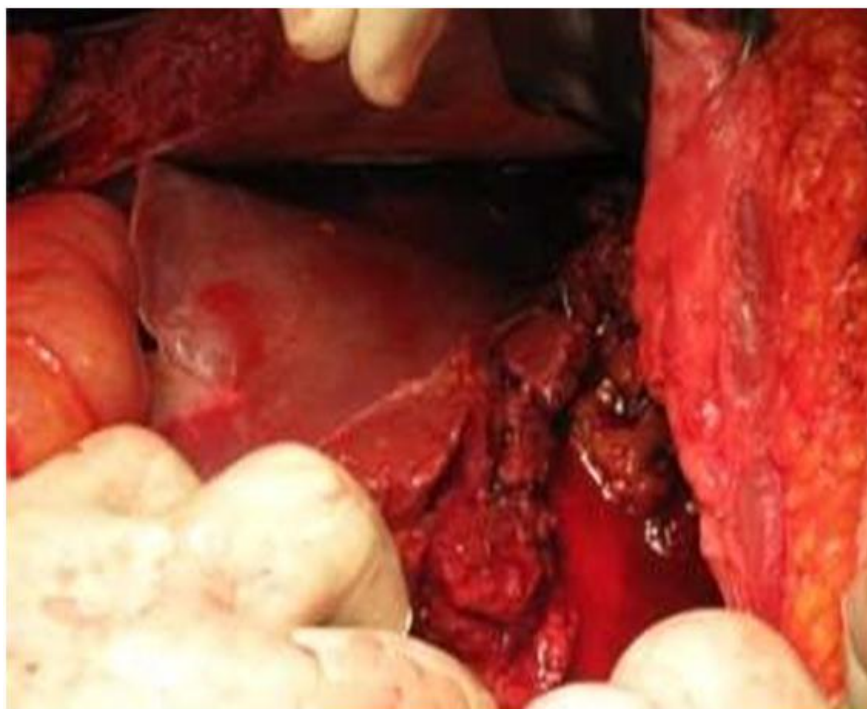
- Intra-operative photo showing retroperitoneal bleed.



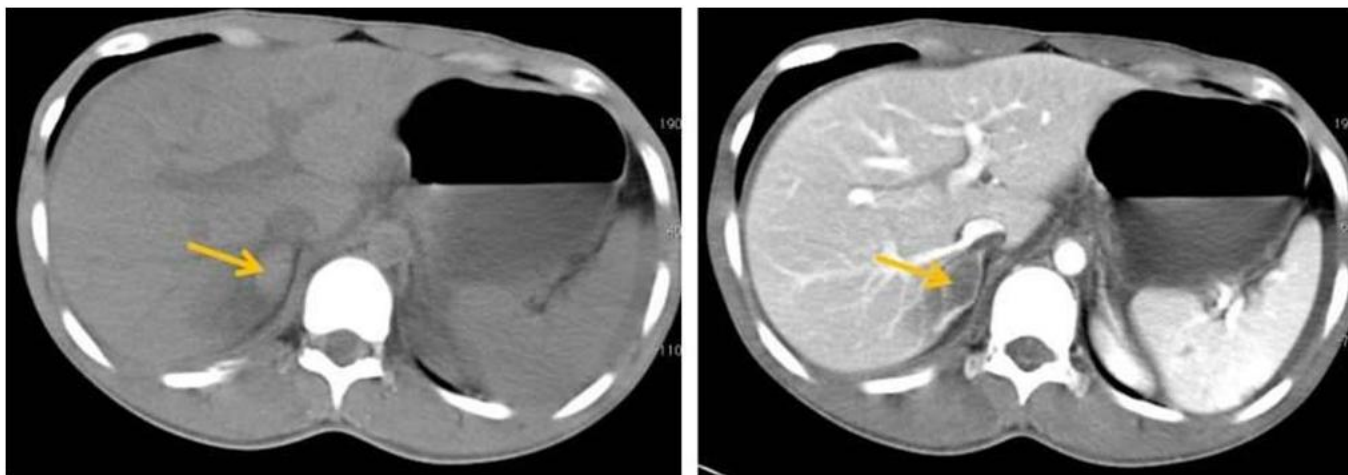
CECT Abdomen & Pelvis showing extravasation of contrast material in left peri-nephric region with renal laceration following blunt abdominal trauma.



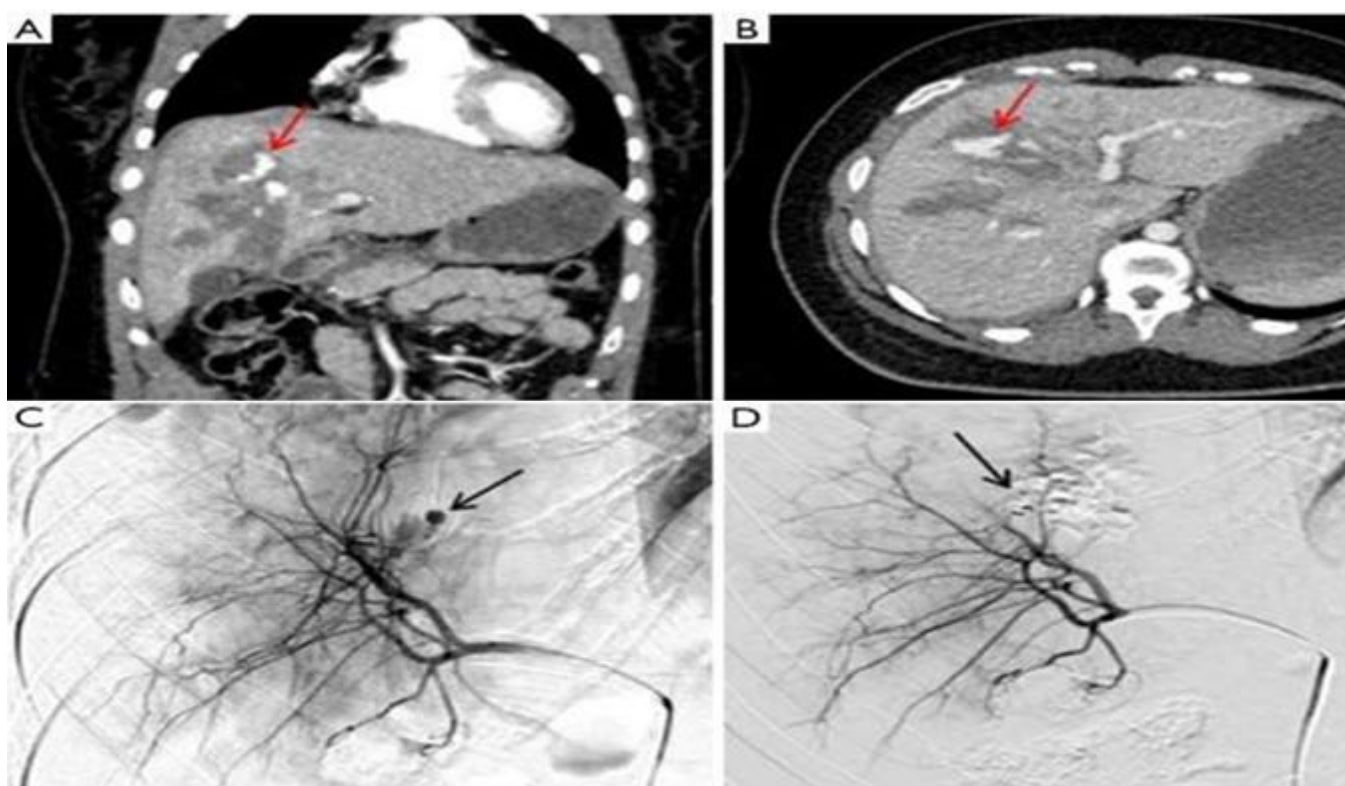
Liver injury with intraperitoneal contrast extravasation visible on computed tomography scan.



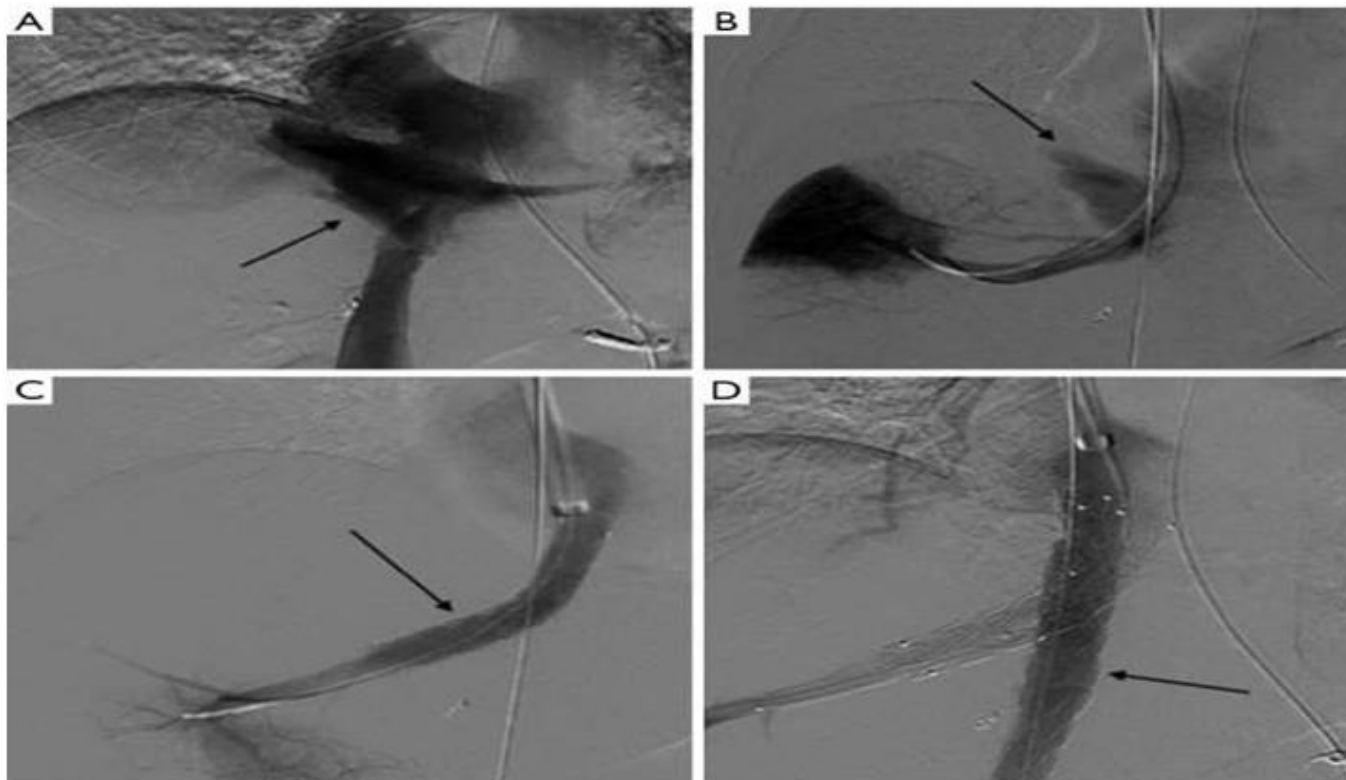
Intra-operative image showing hepatic injury in same patient.



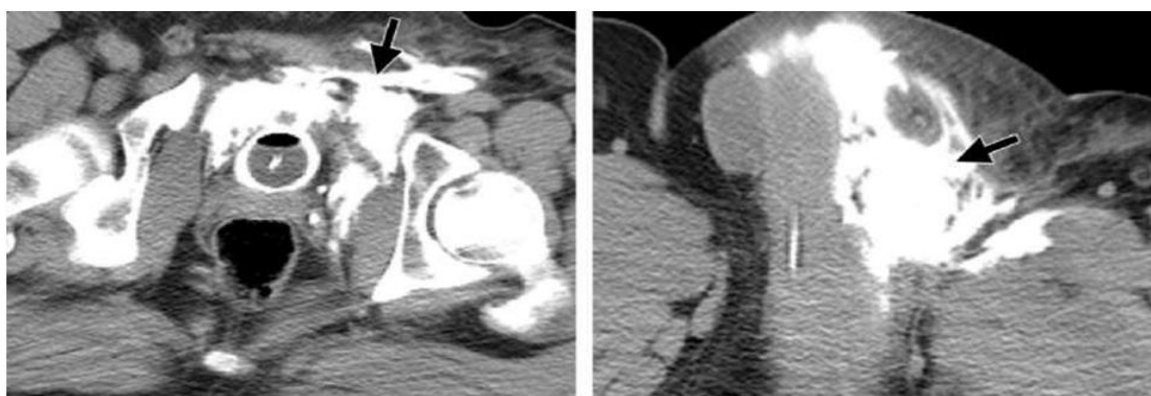
CT scan at the level of right adrenal gland in axial plane soft tissue window pre and post contrast that shows the right adrenal gland haemorrhage as hyperdense on post contrast and relatively hypodense on pre contrast image.



Axial (A) and coronal (B) images of the CT with contrast through the liver shows a large grade V laceration with active contrast extravasation/bleeding (red arrow); (C) selective angiogram of the right hepatic lobe demonstrates a pseudoaneurysm with active contrast extravasation/bleeding from an arterial branch (arrow); (D) post coiling shows satisfactory hemostasis (arrow).



(A) DSA images of a cavogram and (B) hepatic venogram show active extravasation of contrast from the junction of hepatic veins with IVC, consistent with traumatic disruption of hepatic vein from IVC (arrows); (C) subsequently, a covered stent was placed from the hepatic vein into the IVC (arrow); (D) a second covered stent was put in the IVC to maintain antegrade flow (arrow). DSA, digital subtraction angiography; IVC, inferior vena cava.



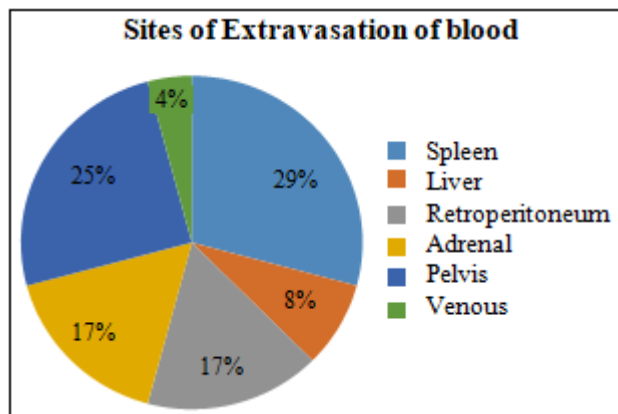
a. Axial whole-body CT angiographic image shows a complex extraperitoneal bladder rupture with extravasation of contrast material into the abdominal wall (arrow). An associated open-book pelvic fracture also was present.

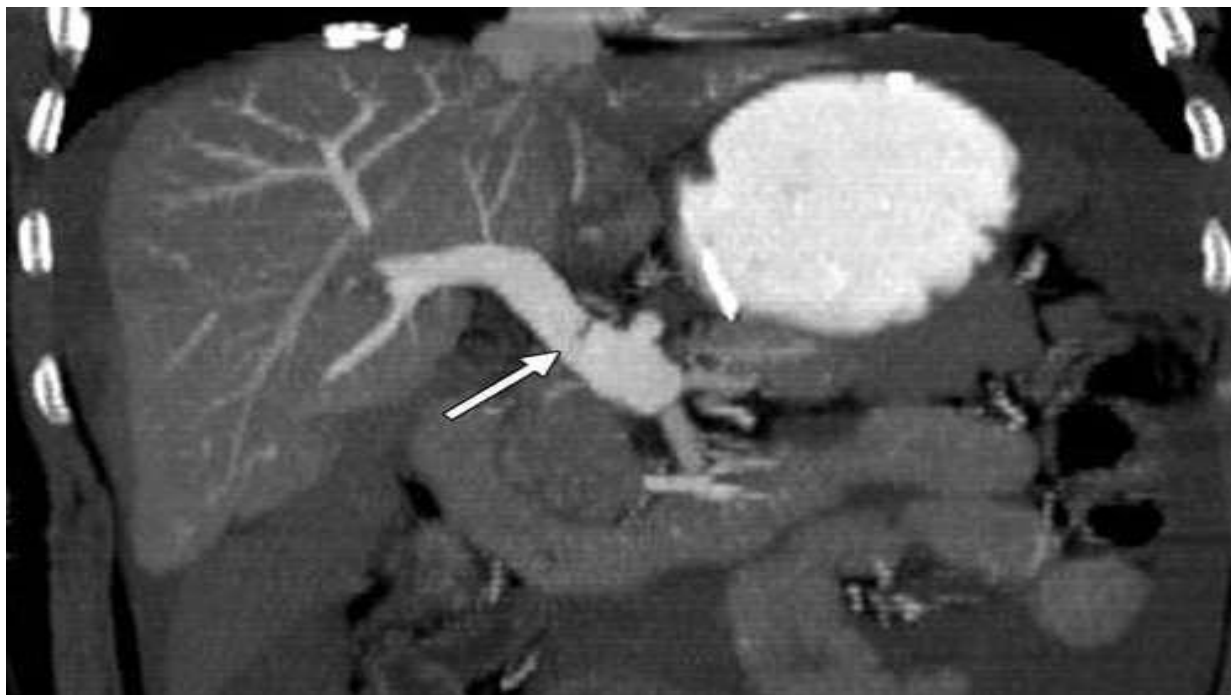

Image showing focal hypoattenuation within the main portal vein following blunt abdominal trauma, suggestive of venous injury.

4. Conclusion

- The location of extravasation of contrast material as seen on CT scan included the spleen (seven), pelvis (six), retroperitoneum (four), kidney (four), liver (two) and adrenal gland (one).
- One patient had venous extravasation.



- The origin of bleeding was confirmed in all cases to correspond to the anatomic region of extravasated contrast on CT.
- The CT attenuation of active haemorrhage ranged from 75 to 350 HU (Mean 144 HU).
- Clotted blood revealed CT attenuation range of 45 to 65 HU (Mean 55), significantly differing from values of active haemorrhage.