

Cervical Rib - A Nursing Case Study Approach

Renuga Devi M. Sc (N)

Fatima College of Health Sciences, Al Ain, Abu Dhabi, United Arab Emirates

Abstract: Cervical rib is a rare anatomical defect with an extra rib formation above the first rib. The incidence ranges about 1-3% and it is termed to be the main cause of Thoracic outlet Syndrome. Neurogenic Thoracic outlet syndrome is the most common and lead to more serious complications if left untreated⁶. Most often due to the exhibition of symptoms this disease is detected in the early adulthood and is diagnosed by radio graphical methods. The treatment includes drugs to manage the pain and surgical interventions. A case study with cervical rib leading to Thoracic outlet syndrome (TOS) has been discussed in nursing process approach.

Keywords: Cervical rib, Thoracic outlet syndrome, case study

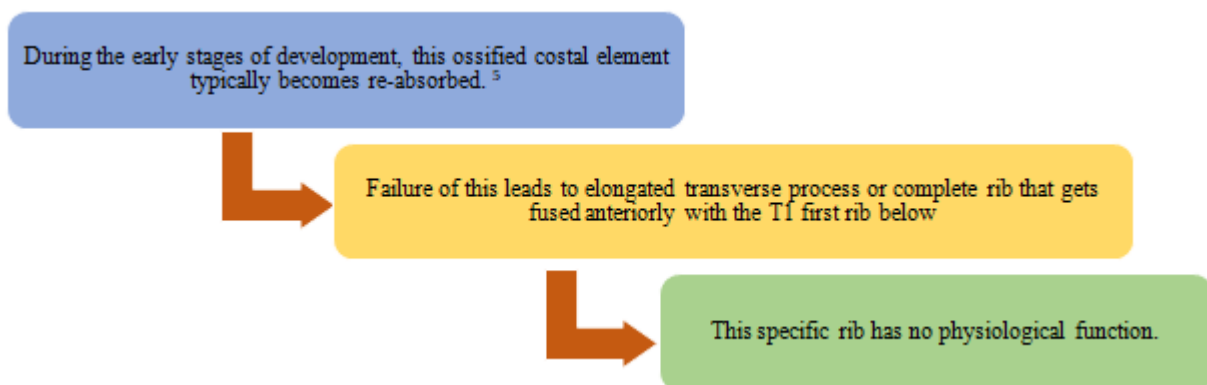
1. Introduction

Cervical rib a rare congenital overdevelopment of transverse process of the cervical spine vertebra³. It has other names such as “neck rib” or “supernumerary rib in the cervical region”⁴. It is an extra rib that forms above the first rib and grows from the base of the neck just above the collar bone. It may be on one side or both and may be floating without any connection². It may present as a fully formed bony rib or a thin strand of tissue fiber with varied size and shape.

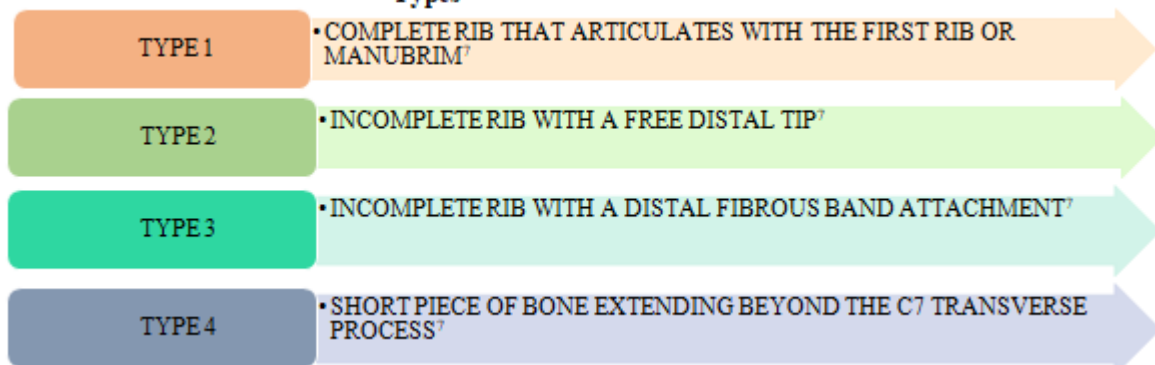
It is predicted that 1 in 10 person develop Thoracic Outlet Syndrome (TOS) which usually exhibits symptoms between the ages 20-50⁴. This occurs due to the pressure on the nerves that is caused by the presences of the cervical rib.

2. Pathophysiology

A cervical rib represents the persistent ossification of C7 lateral costal element.⁵



Types



Clinical Manifestations

The various symptoms of TOS due to cervical rib are as follows,⁸

- Fixed tender, hard and bony supraclavicular lump
- Tingling sensation in hands and fingers
- Radiating arm pain
- Atrophy of the muscles (palmar)
- Cold pale extremities
- Changes in skin color

- Feeble or absent radial pulse
- Risk of gangrene
- Loss of hand grip
- Edema of the extremities
- Prominent veins in the shoulder, neck and hands.

Diagnostic Tests

- History Taking

Volume 12 Issue 5, May 2023

www.ijsr.net

Licensed Under Creative Commons Attribution CC BY

- Physical examination- movements to provoke the symptoms
- Adson's test¹⁰
- Spurling's test¹⁰
- Radiographic imaging – X-ray and MRI¹⁰

X-ray can be incidental finding which may reveal transverse processes are infero laterally directed whereas normally thoracic spine are anterolaterally directed.

Management

Medical:

- Drugs – NSAIDS to relieve pain, anticoagulants⁹
- Botulinum toxin A injection – Temporary nerve block to reduce pain³
- Physiotherapy – Short wave Diathermy, Gripping exercises, Strengthening exercise, Posture correction, Endurance training, Progressive resistance exercise for shoulder girdle muscles.³

Surgical:

- Removal of extra segment¹
- Complete resection of the rib
- Scaleneotomy – dividing the scalene group of muscles³

3. Complications

If left untreated it may lead to ischemia, thrombosis, aneurysm formation and stroke.

4. Nursing Management

The nursing management of a patient with Cervical rib leading to TOS is discussed using a case report.

Mrs. X, a 24 year old non-smoker female came with the complaints of left shoulder pain for the past one year. She described that her pain was insidious in onset, compressing and radiating to the hand. Also verbalized that pain aggravates during elevation of the limb and during ADL's. Other symptoms expressed were paresthesia, cold extremities and swelling of the affected limb. She verbalized that she has breathing difficulty for the past couple of days. She was initially treated with analgesics but was of no use. No family history of Cervical rib. Since her symptoms kept aggravating she was referred to tertiary care center.

On examination she was afebrile, temperature was 36.8⁰ C, her BP was 100/74 mm Hg, PR= 100/min, SpO2 94% on room air, RR=30/min. Due to pain and compression she has shallow and rapid breathing. Chest auscultation was clear. She was positive for Adson's test. On examination her muscle power was 3/5. Her X-ray revealed extra rib on both sides but left rib was longer than the right. Her MRI revealed that she has B/L cervical rib with brachial plexus compression on the left side. She underwent complete excision of Left Cervical rib through anterior approach and also scaleneotomy.

Nursing Care of Mrs. X is discussed using the Nursing Process Approach

Pre-OP:

- 1) **Nursing Diagnosis:** Ineffective breathing pattern related to nerve compression as evidenced by rapid shallow breathing and increased respiratory rate.

Expected outcome: She maintains normal breathing pattern as evidenced by normal saturation levels, respiratory rate and verbalization of ease in breathing.

Interventions:

- Assessed the respiratory rate, pattern and use of accessory muscles. Respiration is rapid and shallow. Has Tachypnea.
- On auscultation, bilateral air entry was present.
- Administered oxygen 6L via face mask as per the physician order.
- Positioned her in Fowler's in-order to have adequate lung expansion.

Evaluation: She maintained normal breathing pattern as evidenced by normal respiratory rate and pattern. Maintains normal saturation in the room air.

- 2) **Nursing Diagnosis:** Chronic pain related to nerve compression as evidenced by verbalization of pain score 8/10 and facial grimaces.

Expected outcome: She is free from pain as evidenced by verbalization of decrease in pain and a score of 4/10 and relaxed facial grimaces.

Interventions:

- Assessed the level of pain and its characteristics.
- Administer analgesics as per the physician's order.
- Encourage and teach to perform relaxation techniques such as deep breathing exercises, music therapy and pet therapy.
- Educate the patient to limit the activities if pain is severe and has symptoms of paresthesia.
- Encourage adequate rest periods and appropriate positioning.

Evaluation: She was free from pain as evidenced by verbalization of decrease in pain and relaxed facial expressions.

- 3) **Nursing Diagnosis:** Impaired physical mobility (upper extremity) related to nerve compression and pain as evidenced by decreased range of motion.

Expected outcome: She maintains normal physical activity as evidenced by involvement in Activities of daily living without interruption.

Interventions:

- Assessed the range of motion and factors inhibiting the activity level.
- Assess for the presence of pulse, paresthesia and pain.

- Encourage her to perform ADL's within the limits.
- Administer analgesics before the activity period.
- Encourage her involve in self-care activities.
- Encourage her to perform active and passive ROM exercises if not contraindicated.
- Provide positive encouragement during activities and also provide alternate rest periods.

Evaluation: She maintained normal activity level as evidenced by partial involvement in self-care activities like combing and brushing.

- 4) **Nursing Diagnosis:** Anxiety related to inability to use the upper extremity as evidenced by crying and verbalization of depressed feeling and fear.

Expected outcome: She maintains normal breathing pattern as evidenced by normal saturation levels, respiratory rate and verbalization of ease in breathing.

Interventions:

- Assessed the level of anxiety and expression of fear
- Be available for their calls and clarify their queries within the nursing limits.
- Avoid using of jargons in-order to prevent confusion
- Converse to them in the language known.
- Introduce them to another patient with same problem and good prognosis. This will help them to gain positive feelings towards the prognosis.
- Provide spiritual support as per the institutional policies.

Evaluation: Her anxiety was reduced as evidenced by relaxed facial expression, cessation of crying spells, relaxed behavior and verbalization.

POST-OP:

- 5) **Nursing Diagnosis:** Readiness for enhanced self-care as evidenced by patient desire to begin mobility exercises to promote comfort.

Expected outcome: She involves in mobility exercise program as evidenced by verbalization of importance of exercises to prevent gangrene.

Interventions:

- Assessed the patient's willingness to involve in exercise regimen.
- Educate and involve her in the regimen planning.
- Allow her to perform the ROM exercises at her own pace. Do not rush up.
- Always provide positive encouragement and reinforce the positive outcomes as it occurs.

Evaluation: She participated in her exercise regimen enthusiastically and was able to involve in her ADL's.

References

- [1] Adson, A. W., & Coffey, J. R. (1927). Cervical rib: a method of anterior approach for relief of symptoms by division of the scalenus anticus. *Annals of surgery*, 85(6), 839.

<https://doi.org/10.1097%2F00000658-192785060-00005>

- [2] Chang, K. Z., Likes, K., Davis, K., Demos, J., & Freischlag, J. A. (2013). The significance of cervical ribs in thoracic outlet syndrome. *Journal of vascular surgery*, 57(3), 771-775. <https://doi.org/10.1016/j.jvs.2012.08.110>
- [3] Fugate, M. W., Rotellini-Coltvet, L., & Freischlag, J. A. (2009). Current management of thoracic outlet syndrome. *Current treatment options in cardiovascular medicine*, 11(2), 176-183.
- [4] Haroun, H. S. W. (2016). Cervical rib and thoracic outlet syndrome. *MOJ Anat Physiol*, 2(5), 138-43.
- [5] Huang, J. H., & Zager, E. L. (2004). Thoracic outlet syndrome. *Neurosurgery*, 55(4), 897-903.
- [6] Kuhn, J. E., Lebus, G. F., & Bible, J. E. (2015). Thoracic outlet syndrome. *JAAOS-Journal of the American Academy of Orthopaedic Surgeons*, 23(4), 222-232. DOI: 10.5435/JAAOS-D-13-00215
- [7] Nwadinigwe, C. U., Iyidobi, E. C., Ekwunife, R. T., & Onwuekwe, C. V. (2018). Thoracic outlet syndrome from bilateral cervical ribs-A clinical case report. *Journal of Orthopaedic Case Reports*, 8(2), 78. doi: 10.13107/jocr.2250-0685.1060
- [8] Roos, D. B., & Owens, J. C. (1966). Thoracic outlet syndrome. *Archives of Surgery*, 93(1), 71-74. doi:10.1001/archsurg.1966.01330010073010
- [9] Sanders, R. J., & Hammond, S. L. (2002). Management of cervical ribs and anomalous first ribs causing neurogenic thoracic outlet syndrome. *Journal of vascular surgery*, 36(1), 51-56. <https://doi.org/10.1067/mva.2002.123750>
- [10] Sanders, R. J., Hammond, S. L., & Rao, N. M. (2007). Diagnosis of thoracic outlet syndrome. *Journal of vascular surgery*, 46(3), 601-604. <https://doi.org/10.1016/j.jvs.2007.04.050>

Author Profile

Renugadevi (M.Sc Nursing), Lab Specialist, Medical Surgical Nursing, Fatima College of Health Sciences. Abu Dhabi, UAE. Mail ID: renis.rose@gmail.com

