

An Important Differential of Free Gas under Diaphragm - Chiladiti Syndrome: A Case Report

Dr. Zeel Sheth Agrawal¹, Dr. Shivendra Agrawal²

¹Consultant General & Laparoscopic Surgeon, Goodwiills Hospital Pvt Ltd, Raipur, Chhattisgarh, India

²Consultant General & Laparoscopic Surgeon, Goodwiills Hospital Pvt Ltd, Raipur, Chhattisgarh, India

Abstract: Chiladiti syndrome is a rare condition where there is an interposition of colon⁴ between liver and right hemi - diaphragm (Figure 1). The incidence of this syndrome ranges from 0.025% to 0.28% and seem to increase with age, having a male to female ratio of 4: 11. It is often asymptomatic and is known as CHILADITI SIGN but rarely may cause abdominal pain, nausea, vomiting, constipation. This rare syndrome need to be distinguished from the more frequently seen causes of air under the right hemi - diaphragm or else it leads to unnecessary surgical intervention³. Chiladiti syndrome may be permanent or sporadic and easily discernable on Abdominal Roentgenogram (AXR standing view) or Chest Roentgenogram (CXR PA view).

Keywords: Chiladiti syndrome, Pseudo pneumoperitoneum, Free gas under diaphragm, pneumoperitoneum

1. Case Report

A 55 year old male patient admitted to our hospital with chief complaint of upper abdominal pain¹ since last 3 days associated with vomiting. There was no history of fever, diarrhea, constipation, or abdominal distension. On clinical examination patient was found distressed without any evidence of dehydration. There was no guarding, rigidity, tenderness or rebound tenderness. On percussion, Tympanic note was elicited over the right hypochondrium region. Patient's bowel sound and per - rectal examination was found essentially normal. Patient's vital were normal. Patient's other systemic examination including respiratory, cardiovascular system were found normal.

Blood parameters were found within normal limits. Chest roentgenogram revealed gas under right hemi - diaphragm with haustral folds (Figure 2) ³. Ultrasonography of abdomen confirmed the hepato - diaphragmatic transposition of colon. Based on the clinical profile & imaging, a diagnosis of CHILADITI SYNDROME was entertained.

Patient was put on I/V fluids, I/V pantoprazole drip, nasogastric tube in situ and was kept nil by mouth. There was a dramatic improvement of symptoms over next 8 - 10 hours but the X - ray findings remained as before.

2. Discussion

Hepato - diaphragmatic interposition of large intestine (usually hepatic flexure of colon) is known as Chiladiti's sign/ syndrome⁴. It is a rare entity and generally present as asymptomatic anatomic variant. Chiladiti syndrome is often diagnosed as an incidental radiological finding.

It has been proposed that the term CHILADITI SIGN should be used in an asymptomatic individuals, while CHILADITI SYNDROME should refer to symptoms which includes abdominal pain, torsion of bowel (volvulus) ^{5, 6} and shortness of breath.

The exact cause is still not known but predisposing factors may include long mobile colon, laxity of falciform ligament, emphysema, cirrhosis and ascites.

Here we report a case of Chiladiti Syndrome in an elderly male, who presented with a short history of upper abdominal pain¹ and vomiting. Rarity of this condition and strikingly different treatment strategy as opposed to other serious causes of pneumoperitoneum unprompted us to report it. The various causes of Pseudo - pneumoperitoneum are listed below to avoid confusion with that of pneumoperitoneum (Table 1 & Table 2).

Colonic transposition can be diagnosed from Chest or abdominal roentgenogram revealing air under the right hemi - diaphragm with haustral folds³. It can also be confirmed by USG or CT scan of abdomen. However, if unaware, chiladiti syndrome has strong potential for confusion and may lead to error in diagnosis and unnecessary laparotomy in search of a perforated viscus. Presence of haustral folds help to distinguish it from free air under the diaphragm. Generally, the mainstay of therapy is conservative which consists of bed rest, intravenous fluids, nasogastric decompression, enema and stool softener. Thus it is imperative to differentiate this syndrome from the more serious simulating pathological condition like perforated viscus, subphrenic abscess to avoid unnecessary surgical exploration and proper disposition of cases. This case report will help to sensitise the physician and the surgeons to keep it as a differential diagnosis when faced with cases of free gas under the right hemi - diaphragm.

Causes of Pseudo - Pneumoperitoneum	Causes of Pneumoperitoneum
<ul style="list-style-type: none"> • Chiladiti Syndrome • Sub - diaphragmatic fat • Curvilinear pulmonary collapse • Uneven diaphragm • Distended viscus • Omental fat • Sub - phrenic abscess • Sub - pulmonary pneumothorax • Intramural gas 	<ul style="list-style-type: none"> • Hollow viscus perforation • Post laparotomy • Post laparoscopy • Peritoneal dialysis • Air from pneumatosisintestinalis • Perforated jejunal diverticulosis

Volume 12 Issue 5, May 2023

www.ijsr.net

Licensed Under Creative Commons Attribution CC BY

3. Conclusion

Chiladiti syndrome need to be distinguished from the more frequently seen causes of air under the right hemi - diaphragm or else it leads to unnecessary surgical intervention. This case report will help to sensitise the physician and the surgeons to keep it as a differential diagnosis when faced with cases of free gas under the right hemi - diaphragm.

References

- [1] Schubert S. - Chiladiti syndrome; an unusual cause of chest and abdominal pain. *Geriatrics*.53: 85 - 88, (s), 1998.
- [2] Saber A. A., Boros M. J. - "Chiladiti Syndrome, what should every surgeon know?" *Am Surg*.71 (3); 261 - 263, 2005.
- [3] Sanyal K., sabanathan K. - Air below the right diaphragm: Chiladiti's sign. *Emerg Med J*.25; 300, (s), 2008.
- [4] Murphy J. M., Maiburn A., Alaxender G., Dixon A. K. - Chiladiti's syndrome and obesity, *clinical anatomy*.13; 181 - 184 (s), 2000.
- [5] Matthews J., Beck G. W., Bowlay D. M., Kingsforth A. N. - Chiladiti syndrome and recurrent colonic volvulus: a case report. *JR Nav Med Serv*.87; 111 - 112 (s), 2001.
- [6] Field S., Morrison L. - The acute abdomen In; *textbook of radiology and imaging 7th edition; Vol - I; 663 - 667, 2003.*

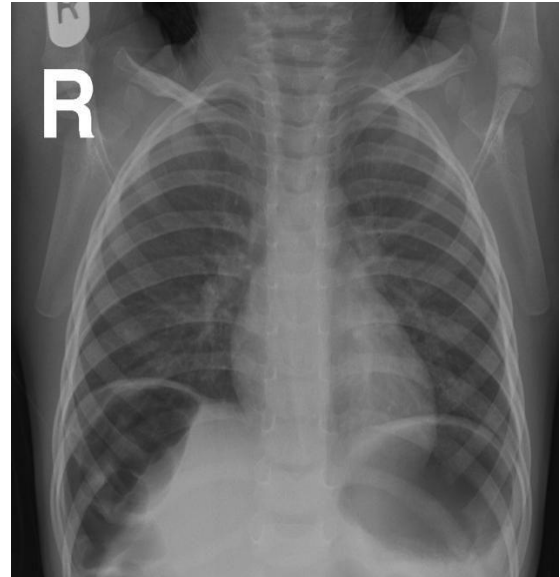


Figure 2

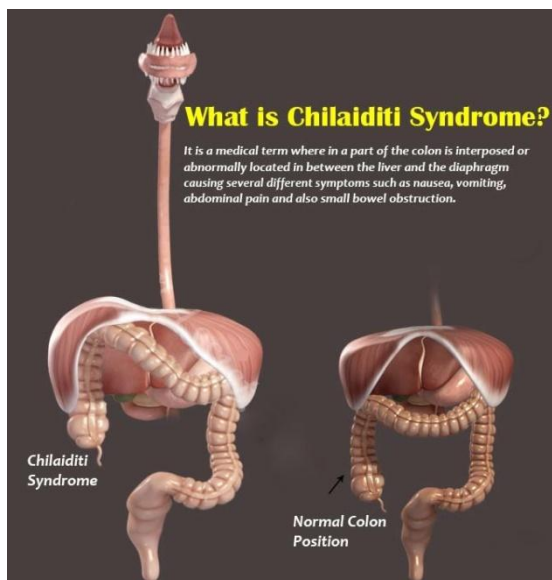


Figure 1