

An Interesting Case of Pleuropericardial Cyst

Dr. Tummidu Vineela¹, Dr. Raju S Iyer², Dr. Lella Nageswara Rao³, Dr. Satyanarayana⁴,
Dr. Ramakrishna Narra⁵

¹1st Year General Surgery PG, Katuri Medical College and Hospital, Chinakondrupadu, Guntur (District), Andhra Pradesh, India

²MS, MCh, F. C. C. P, F. I. A. C. S, (CTVS), Katuri Medical College and Hospital, Chinakondrupadu, Guntur (District), Andhra Pradesh, India

³MD Anaesthesia, Katuri Medical College and Hospital, Chinakondrupadu, Guntur (District), Andhra Pradesh, India

⁴MD Pathology, Katuri Medical College and Hospital, Chinakondrupadu, Guntur (District), Andhra Pradesh, India

⁵MD DNB Radiology, DM Neuroradiology, Katuri Medical College and Hospital, Chinakondrupadu, Guntur (District), Andhra Pradesh, India

Abstract: A 59 year old male presented with dyspnoea on exertion since four months. Clinical examination revealed decreased breath sounds over left side of the chest. Chest x - ray showed a cystic lesion in the left lung field with no mediastinal shift. Contrast CT Chest revealed approximately 12cm ×11cm loculated collection in left upper and middle hemithorax abutting the heart and adjacent pulmonary trunk with collapse of underlying lung suggesting a mediastinal cyst. Patient underwent left thoracotomy under one lung ventilation. The cyst was excised. The fluid was sent for cytology and the cyst wall for histopathological examination.

Keywords: Pleuropericardial cyst

1. Introduction

Pleuropericardial cyst is a type of mesothelial cyst of mediastinum which is essentially a unilocular cyst filled with slightly yellowish thin fluid¹. They usually manifest themselves as an asymptomatic disease in the case of well - limited lesions². Of the pericardial cysts, 70 - 80% is located in the right cardiophrenic angle of which the incidence is estimated to be 1/100, 0003. Pleuropericardial cysts are identified in the 4th or 5th decade of life and represent 7 - 18% of all the mediastinal tumors⁴. Stoller and colleagues reported that 50% to 70% of these cysts were located in the right cardiophrenic angle, 20% to 30% in the left and the remainder elsewhere in the visceral compartment. One of the more intriguing aspects of pericardial cysts is their origin. Lambert was the first to discuss the cause of pericardial cysts. He stated that the pericardium arises from a series of disconnected lacunae early in embryonic life. As the embryo enlarges, these lacunae merge to form the pericardial coelom. Failure of one of these lacunae to merge results in cyst formation. Differential diagnoses include foramen of Morgagni hernia, ventricular aneurysm, mediastinal tumor, enlarged pericardial fat pad, diaphragmatic tumor, diaphragmatic eventration, and pulmonic and pleural process. For most simple asymptomatic cysts, observation is alone recommended. Surgical resection or aspiration may be indicated for complex cysts or large symptomatic cysts⁵.

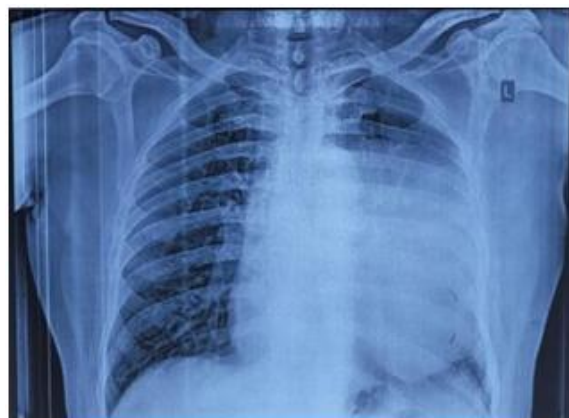

Figure1 (a): Image showing a cystic lesion in the left lung

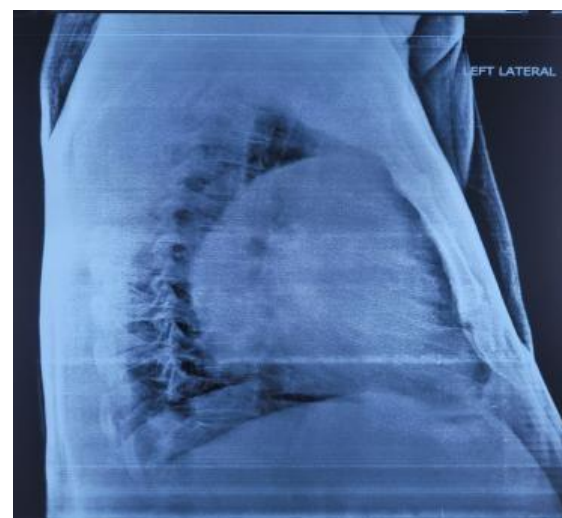

Figure1 (b): Left lateral view.

2. Case Report

A 59 year old male presented to the cardio thoracic vascular surgery outpatient department with dyspnoea on exertion

Volume 12 Issue 7, July 2023

www.ijsr.net

Licensed Under Creative Commons Attribution CC BY

and productive cough since 4 months. Patient was taken to a local hospital for the same complaints and a CECT Chest was done which revealed a cystic lesion with subsegmental collapse of lingula and left lower lobe. Pleural aspiration done and was negative for malignant cells. On intercostal drainage, approximately 800ml of serosanguinous fluid was obtained. Patient symptoms were subsided then. Despite the treatment at the local hospital patient again presented with the same complaints of breathlessness on exertion and productive cough in 4 months later.

Past medical history: Patient had a history of covid 3 years back. The patient is a known smoker and alcoholic since 10 years. He is hypertensive since two years. He had no history of diabetes, bronchial asthma, tuberculosis, coronary artery disease, cerebrovascular disease.

Clinical Examination: Inspection:

Rate of Respiration: Normal Chest Expansion: Normal

Movement of the Chest Wall: Normal Palpation:

Position of trachea: Normal

Percussion: Dull note present on left axilla and infra axillary region

Ascultation: Decreased breath sounds on left axillary, infra axillary and mammary region. Chest Xray:

Figure1 (a) Chest X - ray PA view. Figure1 (b) Chest X - ray left lateral view CECT Chest:

Approximately 12×11 cm loculated collection of HU (+5 to +30) noted in the left upper and middle hemithorax abutting the heart and adjacent pulmonary trunk with collapse of underlying lung suggesting a loculated pleural effusion/seroma/cyst. Figure 2 (a) and 2 (b)

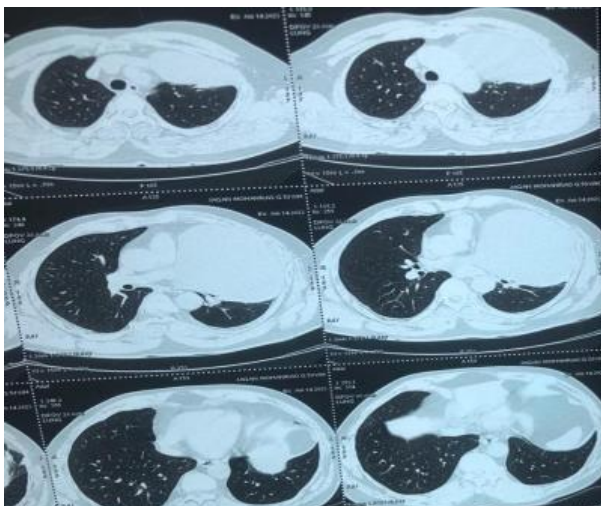


Figure 2 (a): axial view of the cyst

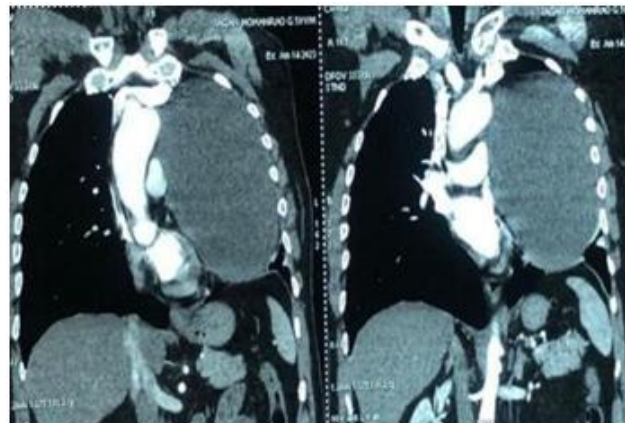


Figure 2 (b): coronal view of the cyst

Operative procedure

Patient was placed in right lateral decubitus position. Under single lung ventilation, chest was opened by left posterolateral thoracotomy through 7th intercostal space. A huge cyst measuring approximately 11 ×12×12cm was identified occupying the space between pericardium and hilum of left lung. There was difficulty in performing the single ventilation due to the huge size of the cyst causing drop in oxygen saturation and hypotension. Since it was difficult to remove the cyst intact, the cyst was aspirated and 3 litres of straw coloured fluid was evacuated. After the fluid was drained the compression over the right lung was relieved and single lung ventilation went on without any difficulty. The cyst wall was completely excised. Pleural cavity washed thoroughly with hydrogen peroxide, betadine and saline. Air leak was checked and haemostasis achieved. Two intercostal chest drains were placed. Thoracotomy wound closed in layers. The fluid was sent for cytology and cyst wall for histopathological examination.

Intra operative findings:

A large pleuropericardial cyst oval in shape measuring 11cm ×12×12 cm filled with 3 litres of serous fluid occupying the space between hilum of left lung and pericardium compressing the left lung. (Please see figure 3a, 3b, 3c, 3d)

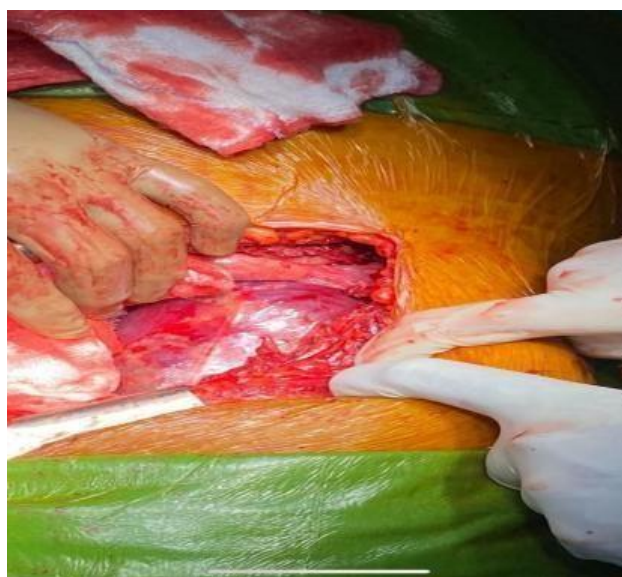

Figure 3 (a): showing the cyst

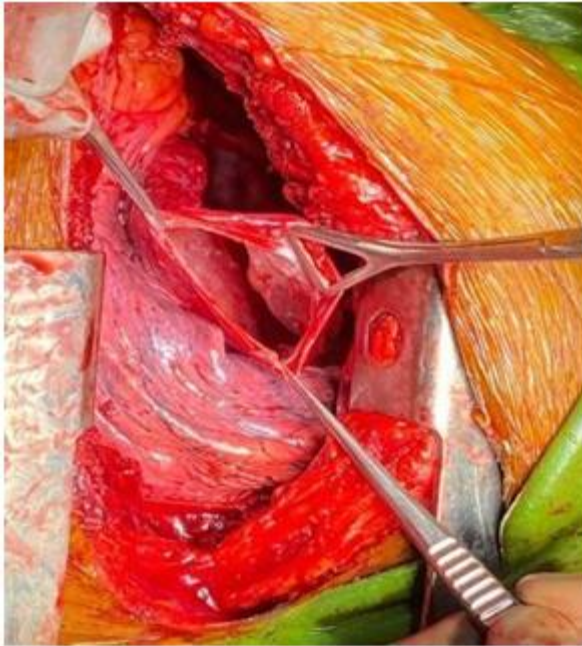

Figure 3 (b): showing the cyst wall after the fluid was drained.

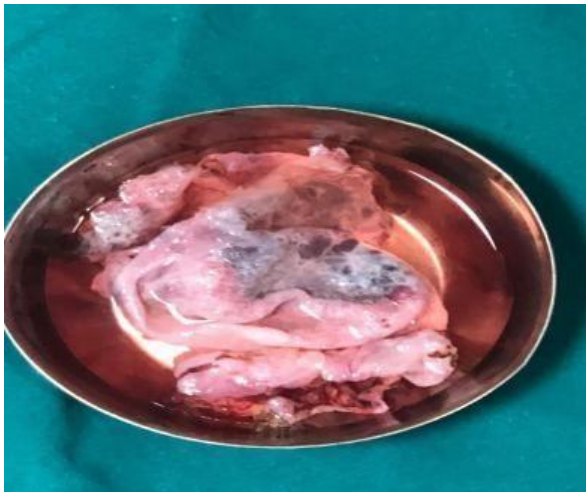

Figure 3 (c): showing the excised cyst wall.



Figure 3 (d): showing the serous fluid

Immediate postoperative Xray

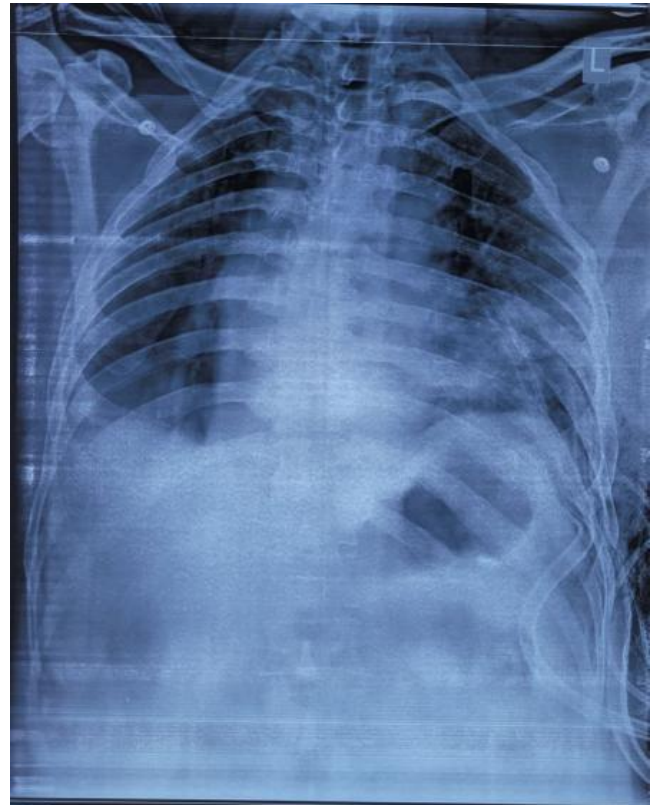


Figure 4

Course in Hospital:

His postoperative course in the hospital uneventful and drains were removed one by one over next few days. He was discharged on seventh postoperative day with improved breath sounds on the left side.

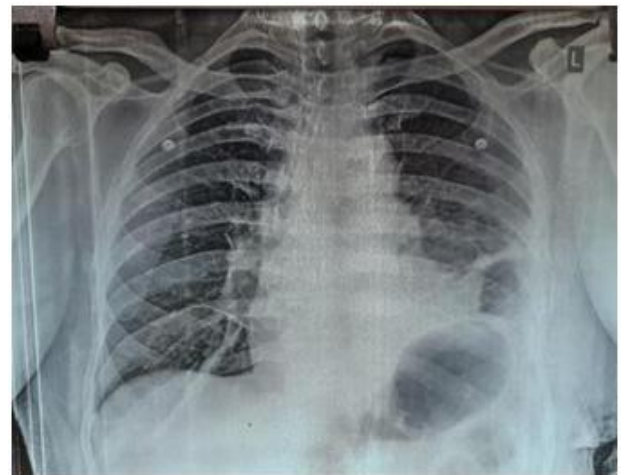


Figure 5: Showing chest x - ray on postoperative 5th day

Histopathological examination

Multiple sections studied from the cyst wall (mediastinal cyst) show histological features of mesothelial pleuropericardial cyst exhibiting cyst wall lined by flattened to cuboidal mesothelial lining and cyst wall with collagenised and loose connective tissue with subpleural lymphoid aggregates. (Figure 6a and 6b)

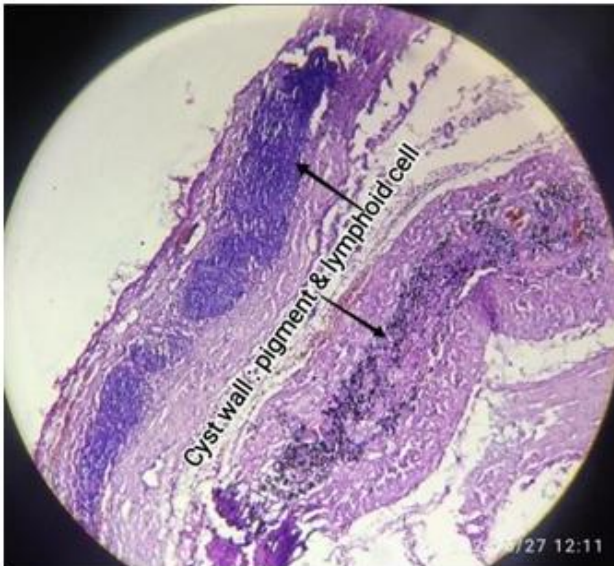


Figure 6 (a): showing microscopic view of cyst wall

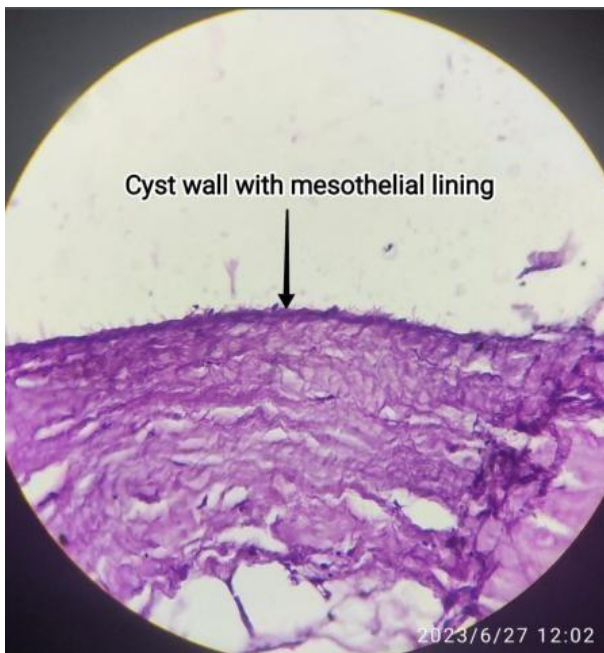


Figure 6 (b): showing mesothelial lining of cyst wall

3. Discussion

Primary cysts of the mediastinum account for approximately 20% of mediastinal masses in most collected series. Cysts are characterized from the organ of origin and may be bronchogenic, pericardial, enteric, or thymic, or may be of an unspecified nature. More than 75% of cases are asymptomatic, and these tumors rarely cause morbidity; however, with proximity to vital structures within the mediastinum and increasing size, the cyst may cause significant problems. Benign cysts may be resected with minimally invasive techniques⁶.

Bronchogenic cysts are foregut - derived cystic malformations of the respiratory tract⁷. They are usually located within the mediastinum at an early stage of gestation or in the lung at a later stage. However, their location can be anywhere along the developmental pathway of the foregut in an ectopic site⁸. Bronchogenic cysts characteristically

exhibit clinical and radiological polymorphism. They pose a differential diagnostic problem, mainly with hydatid disease in endemic countries. The treatment of all bronchogenic cysts has its basis as complete surgical excision, and their definitive diagnosis is established primarily by histopathological examination of the surgical specimen. Prognosis is excellent with no recurrences in case of complete resection⁹. Pericardial cysts are second in frequency to bronchogenic cysts and occur in the cardiophrenic angle mostly on the right side (70%). These cysts may or may not communicate with the pericardium. Typically, clear fluid is encountered. The characteristics of pericardial cysts include location in the cardiophrenic angle, characteristic appearance, smooth borders, and attenuation approximating water for the cyst fluid. Needle aspiration and routine surveillance may be all that is needed. Resection may be used for diagnosis and to exclude malignant tumors. Enteric cysts or duplication cysts arise from the primitive foregut, which develops into the upper division of the gastrointestinal tract. These cysts are usually attached to the esophagus. Symptoms occur as size increases with compression of the esophagus and dysphagia⁶. EDCs must have three characteristics: an epithelial lining containing the mucosa of the alimentary tract, an envelope of smooth muscle, and the cyst must be closely attached to the GT by sharing a common wall. The mucosal lining does not always correlate with the adjacent gastrointestinal tissue, but the duplications are named according to the part of the GT to which these are intimately attached¹⁰. Neuroenteric cysts are associated with anomalies of the vertebral column. Excision is recommended⁶.

4. Conclusion

This case has been sent for publication as the presentation to us was interesting. The patient had a covid infection in the pandemic during which he was accidentally diagnosed to have a mass in the thorax. However, after the covid treatment he was apparently well for a year, following which he developed symptoms of breathlessness and cough for which he had undergone pleural effusion and intercostal drain insertion thinking it to be an effusion or empyema which was not so. This misdiagnosis led to recurrence of the lesion following which he was referred to us and the necessary surgery was done as described.

The final histopathological diagnosis of pleuropericardial cyst with mesothelial lining is also a rare finding in a pleuropericardial cyst. The presence of the cyst on the left hemithorax also was a diagnostic conundrum as these are usually present on the right side. The mesothelial lining of the cyst showed that it had originated from the totipotent mesothelial cells of embryonic origin which presented in his 6th decade of life rather than being of congenital origin.

One should be aware of such possibilities of presentation of benign masses for early diagnosis and prompt treatment.

References

- [1] LoCicero J. Shields' general thoracic surgery. 8th ed. Philadelphia, PA: Lippincott Williams and Wilkins; 2018.

- [2] Hermens FHW, Visser FJ, Termeer A, Barendregt WB, Janssen JP. Video assisted thoracoscopic treatment of pleuropericardial cysts. *Diagn Ther Endosc* [Internet].2001; 7 (2): 47–53. Available from: <http://dx.doi.org/10.1155/dte.7.47>
- [3] Arghir O - C, Dantes E, Velescu L, Saon C, Galbenu P, Ciobotaru C. Giant left - sided pleuropericardial cyst, mimicking a heart disease. *Pneumologia*.2013; 62 (1): 34–6.
- [4] Nitu M, Calarasu C, Olteanu M, Grecu V, Golli AL, Popescu MR, et al. Jan - Mar; 43 (1): 83 - 86. Left Pleuropericardial Cyst *Curr Health Sci J* [Internet].2017; 43 (1): 83–6.
- [5] Townsend CM, Beauchamp RD, Evers BM, Mattox KL. *Sabiston textbook of surgery: The biological basis of modern surgical practice*.20th ed. Elsevier; 2016.
- [6] Reichelt O, Grieser T, Wunderlich H, Möller A, Schubert J. Bronchogenic cyst. *Urol Int* [Internet].2000; 64 (4): 216–9.
- [7] Limaïem F, Ayadi - Kaddour A, Djilani H, Kilani T, Mezni FE. Pulmonary and mediastinal bronchogenic cysts: A clinicopathologic study of 33 cases. *Lung* [Internet].2008; 186 (1): 55–61.
- [8] Limaïem F, Mlika M. *Bronchogenic Cyst*. StatPearls Publishing; 2023.
- [9] Sangüesa Nebot C, Llorens Salvador R, Carazo Palacios E, Picó Aliaga S, Ibañez Pradas
- [10] V. Enteric duplication cysts in children: varied presentations, varied imaging findings. *Insights Imaging* [Internet].2018; 9 (6): 1097–106.