

Perforated Peptic Ulcer in the Pediatric Population: A Rare Case Report

Dr. Alpesh M Rajput¹, Dr. Bhavesh V. Vaishnani²

¹Junior Resident, Department of General Surgery, P. D. U. Medical College and Civil Hospital Rajkot (Corresponding Author)

²Associate Professor, Department of General Surgery, P. D. U. Medical College and Civil Hospital Rajkot

Abstract: We present a rare occurrence in modern day, a case of a seven years old male with a perforated peptic ulcer. he presented with nausea, anorexia, and abdominal pain. On exam, he was febrile, tachycardic, with evidence of peritonitis. An CECT abdomen pelvis revealed pneumoperitoneum. The patient was taken to the operating room and underwent emergency exploratory laparotomy with primary repair of a perforated peptic ulcer with omentopexy.

Keywords: Paediatric peptic ulcer disease, Paediatricpeptic perforation

1. Case Report

The patient is a 7 years old, previously healthy male, who was brought to the emergency room by his parents with complaints of anorexia, nausea, and abdominal pain that began earlier that day. The child awoke in the morning with complaints initially of nausea, without emesis, though went to school as usual. In the afternoon, he noted a sudden onset of abdominal pain, particularly at his epigastrium. His pain was exacerbated by movement, there were no alleviating factors. His parents described a subjective fever, malaise, progressive discomfort and noted that he refused to eat thus prompting the concern for medical evaluation. Bowel movements were reported to be regular; there was no exposure to sick contacts or pets, or a history of recent travel, trauma, or medical procedure. There was no history of chronic abdominal pain or non steroidal anti-inflammatory drug use. Review of systems was otherwise negative. There was no known family history of inflammatory bowel disease, peptic ulcer disease or gastro-intestinal cancers in the family.

On examination, the patient appeared generally unwell, quiet, lying still on his stretcher. he was febrile to 101.9, and tachycardic to 136. Blood pressure and respiratory status on room air were normal. Chest and heart examinations were unremarkable. The patient's abdomen revealed soft, mild tenderness at epigastric region with no guarding and no rigidity.

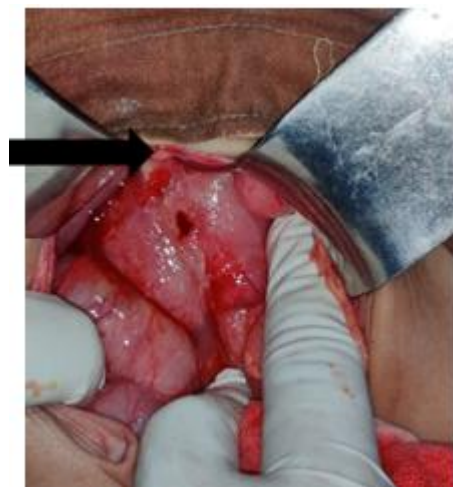

Figure 1: Pre - pyloric peptic Perforation

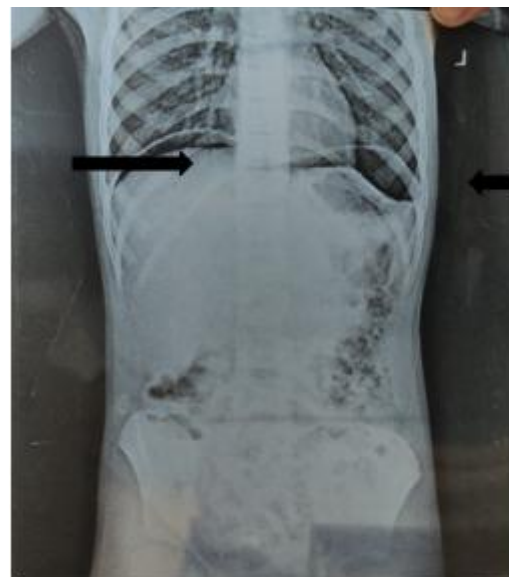


Figure 2: Free gas under both dome of diaphragm (AXR STANDING)

An ultrasound revealed mild ascites with echoes and air foci within suggestive of GI perforation, and an upright abdominal x-ray demonstrated free gas under both dome of diaphragm suggestive of pneumoperitoneum. The patient

was then taken to the operating room for an emergency exploratory laparotomy with the presumed diagnosis of GI perforation. After opening of abdomen 100CC pyoperitonitis was drained 5 x 5 mm peptic perforation found on anterior surface of pylorus. Rest of small bowel and appendix found to be normal. Perforation closed primarily with interrupted 3 - 0 silk sutures and buttressed with an omental patch with primary closure of abdomen. The patient's post - operative course was unremarkable. Immediately following the operation, IV antibiotics was given for 7 days. Sips started on 5th post operative day. Patient was discharged on post operative day 8th. Intraoperative pus collection was sent for culture and sensitivity report no bacterial pathogen was isolated.

2. Discussion

Pneumoperitoneum and peritonitis following the perforation of a peptic ulcer is a rare cause of an acute abdomen in children and often results in a significant delay in diagnosis and subsequent operative management. This increases the likelihood of developing complications post - operatively [1 - 8]. Hua et al., describes a series of 52 patients with perforated peptic ulcer disease in the paediatric population. 90% of such patients were adolescents, and 80% of involved patients were male [8]. Another series published in 1988, reviewed the management of 36 patients with peptic ulcer disease from ages 6 to 18. It was noted that in children under 10, all peptic ulcers were secondary in etiology; attributed to drug therapy or severe underlying illness, or increased intracranial pressure. Patients over 10 with primary duodenal pathology had a high incidence of recurrent symptoms (67%) [3].

Other described instances of perforation in Western countries implicate chronicsteroid administration, NSAIDs, severe underlying illness, trauma, iatrogenic perforations from EGD, and air enemas in the radiologic reduction of intussusception [9 - 14]. Countries such as Nepal, West Africa, and India have reported cases secondary to meningitis, malaria, lymphoma, and gastro - enteritis [4 - 7, 15]. A case series of two patients in Austria described the incidence of simultaneous acute appendicitis with a perforated ulcer [16]. In the Austrian case series, it is unclear if authors believe that the stress of the appendicitis in their patients may have been the triggering event for the perforation. This was, in fact, confirmed on the final pathology report, which diagnosed the inflammatory changes seen on the appendiceal viscera as acute fibrinopurulent serositis, rather than acute appendicitis.

Surgical management of children with perforated peptic ulcers has historically involved the use of open surgery. Laparoscopy has since been shown to be safe and effective in the treatment of children with complicated peptic ulcer disease [17, 18]. In a series by Wong et al., 17 pediatric patients with perforated peptic ulcers were taken for diagnostic laparoscopy and underwent primary repair; 4 were converted to open secondary to technical difficulties and extent of the ulcer. Only two patients had reoccurrence of ulcer disease in the form of bleeding and were managed without surgery [18].

In the adult population, there is some debate on the role of including an antacid procedure for a stable patient at the time of initial surgery for a perforated peptic ulcer. The role of acid lowering procedures in children has not been studied extensively. Edwards et al. reported a series of 29 pediatric patients with complicated peptic ulcer disease, 5 were managed with an antacid procedure at the time of initial operation. However, these were performed in instances of bleeding or gastric outlet obstruction, and may have been required to adequately treat the area of obstruction or bleeding. All patients in this series with perforation [16] were treated with simple repair with or without omental patch [11]. The consensus from review of the literature is consistent with our decision to treat the perforation with primary repair and mental buttress [17, 18].

The prevalence of *H. pylori* infection has declined in the United States and Europe. Despite this, the prevalence remains high in Asia and the developing world. Transmission is thought to occur most frequently from person - to - person, and children are believed most commonly to acquire infection from their mothers. [12, 19] Most published studies demonstrate household crowding, sharing a bed with children, and sharing plates, spoons, or tasting food before feeding a child are related to infection in children. *H. pylori* can be diagnosed via invasive and non - invasive means, which include endoscopy with biopsy, or a urease breath test, detection of antibodies in serum, urine, or saliva, or antigen in stool. To confirm a diagnosis of *H. pylori* infection, two tests are needed, one of which should be based on the results of biopsied tissue, either resulting in a culture, or histology or urease test. First line medical treatment includes a proton - pump inhibitor and two antibiotics for a period of 14 days, with the goal of eradicating 90% of the bacteria on the first course in order to prevent the development of resistant strains [19].

3. Conclusion

Even though peptic perforation is extremely rare in the pediatric population, it must be suspected in children who present with acute abdominal pain and peritoneal signs, as Peptic perforation is a surgical emergency and is associated with up to 30% mortality. Early diagnosis is essential to a timely treatment and lower morbidity. Perforation from peptic ulcer disease is adequately treated with primary closure with omentopexy, and medical management of the underlying Etiology

Conflict of interest: Nil declared

References

- [1] Azarow K, Kim P, Shandling B, Ein SA. 45 - year experience with surgical treatment of peptic ulcer disease in children. *J Pediatr Surg* 1996; 31 (6): 750e3.
- [2] Deckelbaum RJ, Roy CC, Lussier - Lazaroff J, Morin CL. Peptic ulcer disease: a clinical study in 73 children. *Can Med Assoc J* 1974; 111 (3): 225e8.
- [3] Drumm B, Rhoads JM, Stringer DA, Sherman PM, Ellis LE, Durie PR. Peptic ulcer disease in children:

- etiology, clinical findings, and clinical course. *Pediatrics* 1988; 82 (3 Pt 2): 410e4.
- [4] Goldman N, Punguyire D, Osei - Kwakye K, Baiden F. Duodenal perforation in a 12 - month old child with severe malaria. *Pan Afr Med J* 2012; 12: 1.
- [5] Tanzer F, Baskin E, Icli F, Toksoy H, Gokalp A. Perforated duodenal ulcer: an unusual complication of meningitis. *Turk J Pediatr* 1994; 36 (1): 67e70.
- [6] Wilson JM, Darby CR. Perforated duodenal ulcer: an unusual complication of gastroenteritis. *Arch Dis Child* 1990; 65 (9): 990e1.
- [7] Yadav RP, Agrawal CS, Gupta RK, Rajbansi S, Bajracharya A, Adhikary S. Perforated duodenal ulcer in a young child: an uncommon condition. *JNMA J Nepal Med Assoc* 2009; 48 (174): 165e7.
- [8] Hua MC, Kong MS, Lai MW, Luo CC. Perforated peptic ulcer in children: a 20 - year experience. *J Pediatr Gastroenterol Nutr* 2007; 45 (1): 71e4. <http://dx.doi.org/10.1097/MPG.0b013e31804069cc>.
- [9] Bickler SW, Harrison MW, Campbell JR. Perforated peptic ulcer disease in children: association of corticosteroid therapy. *J PediatrSurg* 1993; 28 (6): 785e7.
- [10] Dohil R, Hassall E. Peptic ulcer disease in children. *Baillieres Best Pract Res Clin Gastroenterol* 2000; 14 (1): 53e73.
- [11] Edwards MJ, Kollenberg SJ, Brandt ML, Wesson DE, Nuchtern JG, Minifee PK, et al. Surgery for peptic ulcer disease in children in the post - histamine2 - blocker era. *J PediatrSurg* 2005; 40 (5): 850e4. <http://dx.doi.org/10.1016/j.jpedsurg.2005.01.056>.
- [12] Ertem D. Clinical practice: Helicobacter pylori infection in childhood. *Eur J Pediatr* 2012. <http://dx.doi.org/10.1007/s00431-012-1823-4>.
- [13] Schwartz S, Edden Y, Orkin B, Erlichman M. Perforated peptic ulcer in an adolescent girl. *Pediatr Emerg Care* 2012; 28 (7): 709e11. <http://dx.doi.org/10.1097/PEC.0b013e31825d21c3>.
- [14] Sherman PM. Peptic ulcer disease in children. diagnosis, treatment, and the implication of helicobacter pylori. *Gastroenterol Clin North Am* 1994; 23 (4): 707e25.
- [15] Nuhu A, Kassama Y. Experience with acute perforated duodenal ulcer in a West African population. *Niger J Med* 2008; 17 (4): 403e6.
- [16] Toubanakis G. Perforated chronic duodenal ulcer in children with coexistence of acute appendicitis. *AustPaediatr J* 1988; 24 (6): 371e2.
- [17] Sanabria AE, Morales CH, Villegas MI. Laparoscopic repair for perforated peptic ulcer disease. *Cochrane Database Syst Rev* 2005; (4). <http://dx.doi.org/10.1002/14651858.CD004778.pub2>. CD004778.
- [18] Wong BP, Chao NS, Leung MW, Chung KW, Kwok WK, Liu KK. Complications of peptic ulcer disease in children and adolescents: minimally invasive treatments offer feasible surgical options. *J PediatrSurg* 2006; 41 (12): 2073e5. <http://dx.doi.org/10.1016/j.jpedsurg.2006.08.009>.
- [19] Ford AC, Axon AT. Epidemiology of Helicobacter pylori infection and public health implications. *Helicobacter* 2010; 15 (Suppl.1): 1e6.