

# Case Report: Pediatric Ocular Pyogenic Granuloma

Dr. Pankaj Baruah<sup>1</sup>, Dr. Semim Sultana<sup>2</sup>, Dr. Srijandeep Kumar<sup>3</sup>, Dr. Ipsita Das<sup>4</sup>,  
Dr. Baharul Hoque<sup>5</sup>, Dr. Anusa Gupta<sup>6</sup>

**Abstract:** *Pyogenic granuloma is a misnomer as it is a benign vascular tumour of skin and mucous membranes but not associated with pus formation and histologically the lesion is composed of granulation tissue. A 10 - year - old boy presented with lid mass in left upper eyelid margin for last 2 weeks. It was insidious in onset but rapidly progressive in nature. On examination it was a smooth surfaced, red - purple coloured, sessile painless soft lobulated mass of 4 mm in diameter, present in the middle of upper eyelid margin. Excision of the swelling was done and the sample was sent for histopathological examination. Histopathology report shows features of capillary hemangioma.*

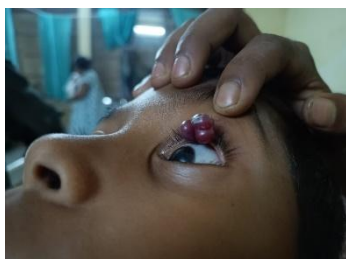**Keywords:** Pyogenic granuloma, Benign vascular tumor, Histopathology, Capillary hemangioma, Eyelid mass

## 1. Introduction

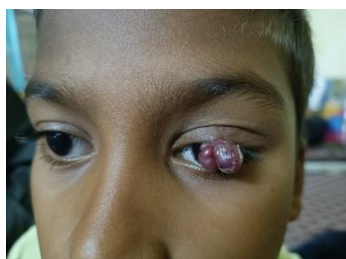Pyogenic granuloma is a misnomer as the lesion is not associated with pus formation and histologically the lesion is composed of granulation tissue. It is a benign vascular tumor characterized by rapid growth and a tendency to bleed. It predominantly affects the skin and mucous membranes, but ocular involvement is relatively uncommon. The pathogenesis is not fully understood, but it is believed to be related to an exaggerated inflammatory response to minor trauma or irritation. It is better known as lobular capillary hemangioma. Here, we present a case of pyogenic granuloma in a patient presenting to our ophthalmology clinic.

## 2. Case Presentation

A 10 - year - old otherwise healthy male child presented with a complaint of redness and discomfort in her left eye for the past two weeks. He reported no history of trauma or prior ocular conditions. On examination, there was a raised, multi - lobulated, red - purple mass measuring approximately 4 mm in diameter, located in the middle of the left upper eyelid margin (Figure 1 and Figure 2).



**Figure 1:** Red - purple raised multi - lobulated mass measuring 4 mm in diameter, side view.

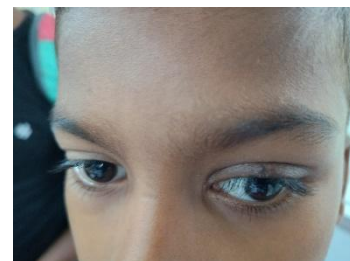

**Figure 2:** Red - purple raised multilobulated mass measuring 4 mm in diameter, front view.

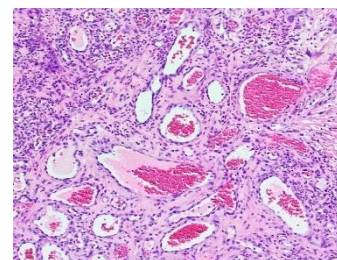
Clinical evaluation included visual acuity assessment, slit - lamp biomicroscopy, and anterior segment photography. The lesion's characteristics, location, and tendency to bleed were consistent with the diagnosis of pyogenic granuloma. Differential diagnoses considered included squamous papilloma and juvenile xanthogranuloma.

## 3. Results

Anterior segment photography and slit - lamp examination revealed a pedunculated, vascular mass arising from the left upper eyelid margin. Given the typical appearance and history of rapid growth, a clinical diagnosis of pyogenic granuloma was made. The mass excised and sent for biopsy. Biopsy report shows histopathological features (Figure 4) of pyogenic granuloma.



**Figure 3:** Post - operative picture



**Figure 4:** Picture of histopathology slide of the lesion

## 4. Discussion

Pyogenic granuloma is often managed through surgical excision. The excised tissue is sent for histopathological examination to confirm the diagnosis and rule out malignancy. In this case, the patient underwent excisional biopsy under local anesthesia. The histopathological examination revealed proliferation of capillaries with a

lobular architecture, confirming the diagnosis of pyogenic granuloma.

Fatima et al. reported a giant proliferative pyogenic granuloma. Norman et al. reported a case of infarcted tarsal pyogenic granuloma

## **5. Conclusion**

Although rare in the ocular region, pyogenic granuloma should be considered in the differential diagnosis of conjunctival lesions, especially when presenting with rapid growth, friability, and a tendency to bleed. Prompt diagnosis and surgical excision can alleviate discomfort and aid in confirming the benign nature of the lesion. Ophthalmologists should be aware of this entity to ensure timely and appropriate management.

Conflicts of interest: none

Financial support and sponsorship: none