

Prosthodontic Management of a Young Patient with X-Linked Hypohidrotic Ectodermal Dysplasia, A Case Report

Nadeem Nasir Kanaan¹, Nader Naif Al Rawabdeh², Fadi Kamel Obeidat³,
Abdullah Mohammad Alhawari⁴, Abeer Abed alaziz Al Rawabdeh⁵

¹BDS, JB, Prothodontics, Prothodontics, Prince Rashid Bin Al-Hassan Hospital
Corresponding Author E-mail address: nadeemkanaan[at]yahoo.com
Phone number: 962777928489

²BDS, JB, Periodontics, Periodontics, Prince Rashid Bin Al-Hassan Hospital

³BDS, JB, Prothodontics, Pediatric Dentistry, Prince Rashid Bin Al-Hassan Hospital

⁴BDS, JB, Pediatric Dentistry, Pediatric Dentistry, Prince Rashid Bin Al-Hassan Hospital

⁵BDS, JB, Pediatric Dentistry, Pediatric Dentistry, Prince Rashid Bin Al-Hassan Hospital

Abstract: *Hypohidrotic ectodermal dysplasia is a group of malformative disorders characterized by the lack or failure of development of ectodermal derivative organs, including skin, mouth lining, anus, nostrils, sweat glands, hair, nails, and teeth. The impact on teeth may range from oligodontia to the more severe forms of anodontia, leading to significant psychological and functional challenges for the patient. As dentists, our role is crucial in replacing their missing teeth. Dental treatment options vary based on factors such as the patient's age, the number and shape of present teeth, and dentoalveolar growth. The case was for a 15-year patient with hypohidrotic ectodermal dysplasia treated with upper removable partial and lower complete dentures because of extremely missing teeth and the low quality and quantity of bone available achieving good esthetic and functional results.*

Keywords: Anodontia, oligodontia, hypohidrotic ectodermal dysplasia, removable appliance

1. Introduction

During embryonic development, the pluripotent stem cells differentiate into three germ layers: endoderm, mesoderm, and ectoderm in a process called gastrulation, which is the beginning of the morphogenesis of human organs.¹

The endoderm forms the internal organs such as the liver and pancreas, and the endothelial lining of the digestive and respiratory systems. On the other hand, the mesoderm differentiates into the bone, muscles, connective tissues, and most of the cardiovascular system. The ectoderm which is the layer we are concerned about in this case gives rise to various structures such as skin, nails, sweat glands, internal ears, the lens of the eye, the nervous system, and including the teeth².

The group of disorders that affect the ectodermal layer called ectodermal dysplasia, first described by Thurnam in 1848, accounting for about more than 154 different groups according to the tissues affected.³

The prevalence of ectodermal dysplasia is about 7 per 10,000 births with the commonest type being x-linked hypohidrotic ED which represents about 95% of the cases with the full expression of the manifestations and abnormalities in males and autosomal dominant and recessive which represents the other 5% where is a mutational change in some genes including EDAR and EDARADD.^{4, 5, 6}

Ectodermal dysplasia is classified according to affected structures into four main groups, the first is the hypohidrotic in which the teeth, nails, hair, and sweat glands are affected and it is usually X-linked.

The second type is the hydrotic (Clouston syndrome) affecting the hair and nails with normal teeth and sweat glands, the third is the Wiktop tooth and nail with abnormalities affecting the teeth and nails.

The fourth type is called Ankyloblepharon –ectodermal defects-cleft lip/palate syndrome, in addition to the classical ectodermal dysplasia manifestations, there are recurrent skin infections that may be fatal, cleft palate with or without a cleft lip, limb abnormalities, and gastroesophageal reflux causing failure to thrive.^{5, 7}

The dental manifestations of hypohidrotic ectodermal dysplasia include hypodontia, oligodontia, or even anodontia, failure of dentoalveolar development, delayed eruption, and dental impaction.

2. Clinical Case

A 15-year-old male was seen in prince Rashid Bin Al Hassan military hospital with his parents complaining of missing teeth, this was his first dental visit even though they didn't have any primary teeth as they stated in the history, and after clinical examination, there were only five

permanent teeth, canines and first molars in the maxilla, and only lower left canine in the mandible.

Other clinical manifestations of ectodermal dysplasia were exactly as it is in the literature including smooth dry skin,

frontal bossing, protuberant lips, depressed nasal bridge, retruded maxilla, forward displacement of mandible, sparse hair, and absence of eyelashes as illustrated in figure 1. From the history, the patient declared that he has heat intolerance and decreased lacrimation.

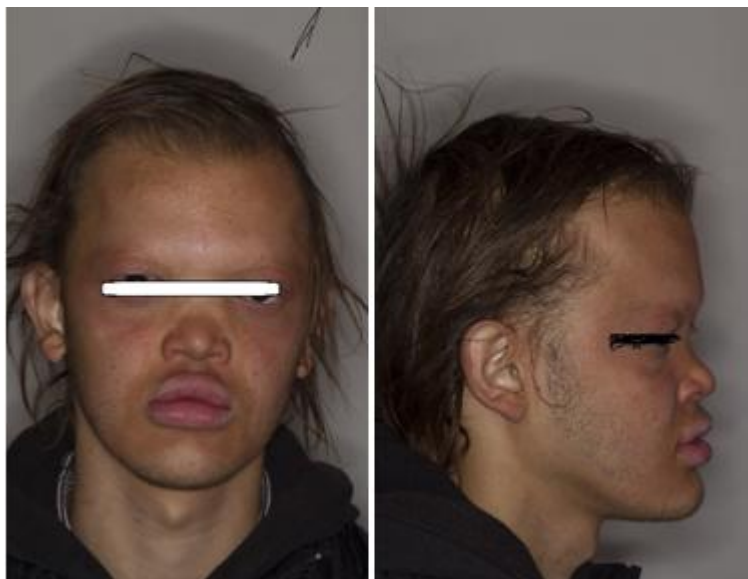

Figure 1

The family history revealed that are no previous cases with the same picture, the patient has one sister and one brother without any of these manifestations.

Clinical examination and ortho-pantographic x-ray displayed numerous missing teeth with deficient dentoalveolar growth and atrophied ridges, the erupted teeth were small with conical roots as seen in Figures 2, 3.

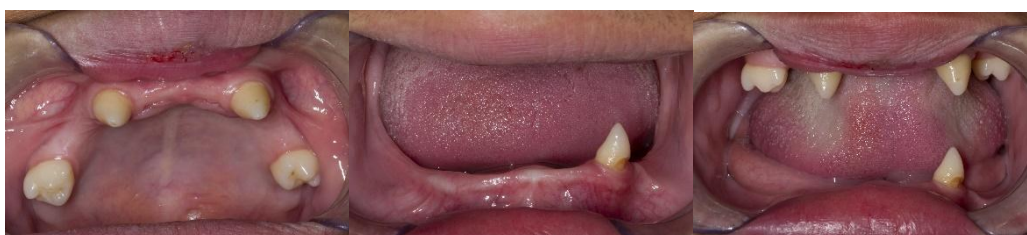

Figure 2

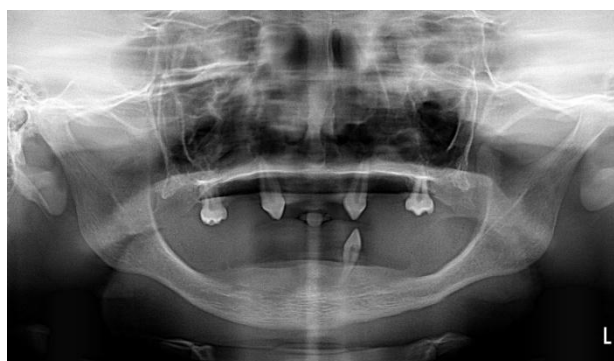


Figure 3: OPG of the patient

Thus, the clinical diagnosis was confirmed it as a case of x-linked hypohidrotic ectodermal dysplasia. The easiest and simplest possible treatment was to construct an upper removable partial denture and a lower removable complete denture.

The difficulties encountered during the treatment were the unwillingness of the patient to cooperate, he was forced by his parents to seek treatment, reduced dentoalveolar

development, knife-edge ridges, short teeth, and low level of the occlusal plane.

Clinical procedures involved upper and lower alginate impressions, poured and custom trays were constructed to make the final impressions using additional silicone rubber materials. On the final casts, upper and lower base plates and wax rims were constructed to register the patient's bite.

We decided to cover the lower canine to reestablish the correct vertical dimension and optimum level of the occlusal plane leading to a better esthetic and functional result.

The final teeth setting was approved by the patient and his parents during the try-in visit, the final prostheses were inserted, representing an upper removable acrylic partial denture with four conventional clasps on the canines and molars, and a lower removable acrylic complete denture. (Clinical procedures illustrated in figures 4-8).

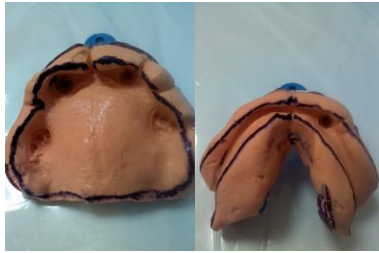

Figure 4: Primary impressions

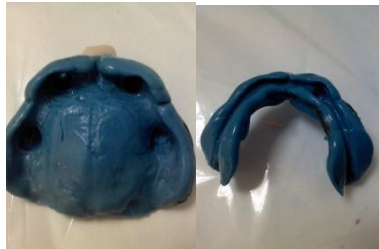

Figure 5: Secondary impressions

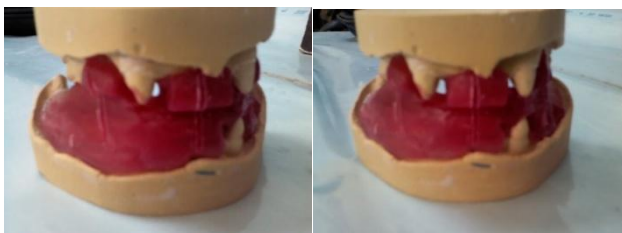

Figure 6: Bite registration

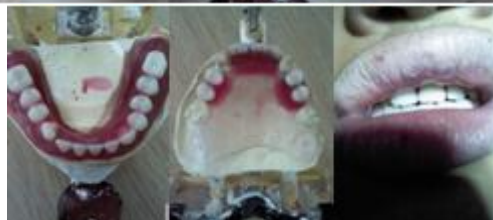
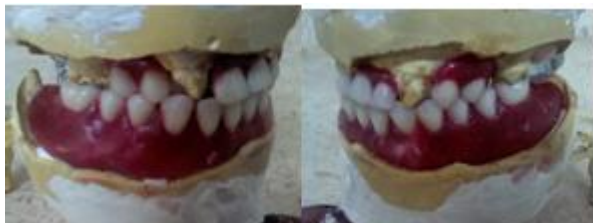
Figure 7: Try in stage

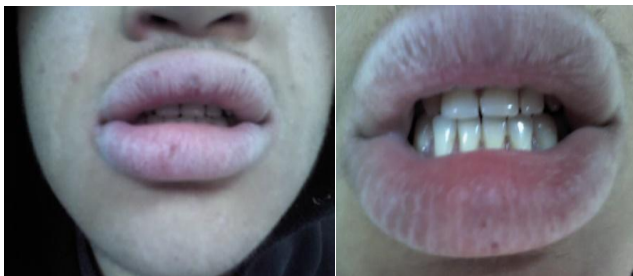

Figure 8: Final prostheses

Instructions about function, limitations of the prostheses, the need for frequent adjustments, and establishing good oral hygiene were given. The patient was scheduled for periodic recall visits and he is happy with them.

3. Discussion

Oligodontia or anodontia is a manifestation of more than 150 conditions, ectodermal dysplasia accounts for about 85% of cases and should be differentiated from them.⁸

The differential diagnosis includes many medical conditions such as Down, ADULT, limb mammary, Ehlers danlos, incontinent pigmentation, Reiger, Werner, and Rothmund Thompson syndromes.

In addition to the history and clinical judgment, the diagnosis of the disease is usually confirmed by doing a skin biopsy, hair study, pantographic X-ray, and undergoing molecular biological analysis focusing and looking for the mutated genes such as EDA, EDAR, and NEMO.⁹

For the best possible functional and psychological well-being of the patient, prosthodontics rehabilitation is considered a major part of the treatment plan, which usually varies according to the patient's age and the severity of the condition.

The removable appliance option is considered the simplest and easiest; it is regarded as the first line of treatment, especially during the early stages of growth¹⁰, but it needs good patient cooperation, compliance, and acceptance.

Natural teeth and implants supported prostheses are other options that can be used and are not entirely contraindicated in young patients, with difficulties that may be encountered due to the large pulp, short clinical crowns, and the need for good oral hygiene^{11, 12}, on the other hand, the need for bone grafting, sinus lifting, and zygomatic implants due to the deficiency of alveolar bone growth^{13, 14}.

In this case, we opted for removable partial and complete dentures as they were the simplest and easiest, and most economical option to provide the patient with a reasonable esthetic and functional state, reducing the detrimental effect of not having teeth compared to his siblings. In the future, we may think about fixed more durable treatment if the medical and economical status of the patient allows.

4. Conclusion

For this 15-year-old patient with X-linked hypohidrotic ectodermal dysplasia, upper removable partial dentures and lower removable complete dentures were selected as the simplest, easiest, and most economical treatment option to achieve reasonable esthetic and functional outcomes. In the future, fixed and more durable treatment options may be considered if the patient's medical and economic status allows.

Declaration of Patient Consent:

The authors confirm that appropriate and necessary patient consent forms have been obtained. The patient's father provided consent for the use of clinical information and images related to his son in the journal, with assurance of maintaining patient anonymity.

Conflict of Interest

None

References

- [1] Muhr J, Ackerman KM. Embryology, Gastrulation. [Updated 2022 Apr 13]. In: StatPearls [Internet]. Treasure Island (FL): StatPearls Publishing; 2022 Jan-.
- [2] Keith L. Moore. Before we are born: essential of embryology and birth defects/-5th edition.1998.
- [3] Campuzano S, Santos-Juanes J, Medina A, Sanchez J, Displasiaectodermicahipohidrotica. A pediatric 2005; 62:393-4.
- [4] S.DALL'OCA, E.CEPPI, G.POMPA, A.POLIMENI.X-Linked hypohidrotic ectodermal dysplasia: A ten-year case report and clinical consideration. Supplement to European Journal of PeadiatricDentistry. Vol. 9/4-2008.
- [5] Majmundar V. Baxi K. Ectodermal Dysplasia. [Updated 2022].In: stat pearls [Internet]. Treasure Island (FL): Stat pearls publishing; 2022.
- [6] SeemaDeshmukh, Prashanth. Ectodermal dysplasia: A genetic review. International journal of clinical pediatric dentistry 2012; 5(3):197-202.
- [7] Julapalli MR, Seher RK, Sybert VP, Siegfried EC, Bree AF. Dermatological findings of ankyloblepharon-ectodermal defects –cleft lip/palate (AEC) syndrome. Am J Med Genet A. 2009; 149 A (9):1900-6.
- [8] Lexner M, Bardow A, Junker I, Jensen L, Almer L, Kreiborg S, Hertz JM. X-Llinkedhypohidrotic ectodermal dysplasia. Genetic and dental findings in 67 Danish patients from 19 families. Clin Genet 2008:74252-259.
- [9] Wright JT, Fete M, Schneider H, Zinser M, Koster MI, Clarke AJ, Hadj-Rabia S, Tadini G, Pagnan N, Visinoni AF, Bergendal B, Abbott B, Fete T, Stanford C, Butcher C, D'Souza RN, Sybert VP, Morasso MI. Ectodermal dysplasias: Classification and organization by phenotype, genotype, and molecular pathway. Am J Med Genet A. 2019 Mar; 179(3):442-447. doi: 10.1002/ajmg.a.61045. Epub 2019 Jan 31. PMID: 30703280; PMCID: PMC6421567.
- [10] Bhavesh T, Rupinder B. Complete and removable partial prosthesis for a child with hypohidrotic ectodermal dysplasia. International Journal of Clinical Pediatric Dentistry 2013; 6(1):71-74.
- [11] Steven L. Singer, Patrick J. Henry, Glen Liddelow, Ian Rosenberg. Long-term follow-up of implant treatment for oligodontia in an actively growing individual: A clinical report. (J Prosthet Dent 2012; 108:279-285).
- [12] Anuroopa A, Abdulla J, Lovely M. Oral rehabilitation of ayoung patient with hypohidrotic ectodermal dysplasia: Aclinical report. ContempClin Dent 2012; 3:533-6.
- [13] Miguel D, Roberto O, Javier F, Juan C. Fixed rehabilitation of apatient with hypohidrotic ectodermal dysplasia using zygomatic implants. Oral SurgRadiolEndod 2004; 98:161-5.
- [14] Afsaneh Rad, Hakimeh S, Abbas M, Amir M. Full mouth rehabilitation of a Hypohidrotic Ectodermal Dysplasia Patient with Dental Implants:A Clinical Report. J Prosthodont 2007; 16: 209-213.