

# Effective Physiotherapy Intervention for Restoring Temporomandibular Joint Function in a Post-Buccal Mucosa Carcinoma Patient: A Case Report

Vyoma Fultariya<sup>1</sup>, Dr. Brinda Joshi<sup>2</sup>

<sup>1</sup>Student of 1<sup>st</sup> MPT in C.U. Shah Physiotherapy College

<sup>2</sup>Assistant Professor of C.U. Shah Physiotherapy College

**Abstract:** *This case report describes a case of a 45-year-old adult male who sought help because of difficulty in mouth opening for the period of 1 month. The patient also reported difficulty in eating and pain on the right side temporomandibular joint region along with history of carcinoma of buccal mucosa on the right-side. Excision surgery of carcinoma was done and chemotherapy taken for the same. Following this, the patient was on a liquid diet. Clinical examination revealed restriction in the active range of temporomandibular joint depression, protrusion. Abnormal tissue stretch end feel was found for all the movement of the temporomandibular joint. Palpation of the lateral pole of the right condyle discovered no crepitus. The KNUCKLE test is positive. There is no "gold standard" treatment for the management of temporomandibular dysfunctions, but for temporomandibular dysfunction treatment has to be based on precise indications related to the presence of pain, limitation in function of the lower jaw. Temporomandibular joint mobilization, range of motion exercise and stretching using tongue blades and in addition, facilitatory exercise in the form of resisted neck flexion was given. After 2-months, follow-up was taken, which showed improvement in range of motion of temporomandibular joint and now the patient is able to chew food. This case report's finding shows the importance of effective physiotherapy intervention in enabling patients to carry out the basic most ADL eating.*

**Keywords:** Temporomandibular joint dysfunction, squamous cell carcinoma, physical therapy, facilitatory exercises

## 1. Introduction

The temporomandibular joint (TMJ) is the articulation between the mandible, the articular disc, and temporal bone of the skull. These joints perform tasks such as chewing, talking and yawning. The function of TMJ is closely related to the function of the upper cervical spine and posture.<sup>1</sup> One of the less common causes of pain in the area of the temporomandibular joint are oral cancers. The most common oral cancer is squamous cell carcinoma.<sup>2</sup> These cancers often present in the later stages of the disease where the treatment is more complicated and survival less likely.

Squamous cell carcinoma is caused by an uncontrolled growth of abnormal squamous cells. Oral cancer is a disease with very poor prognosis because it is not recognized and treated when small and early. It can occur anywhere in the mouth but certain sites are more common such as lower lip, anterior floor of the mouth and buccal mucosa. Carcinoma of Buccal Mucosa is the 5th most common carcinoma of the oral cavity. Oral squamous cell carcinoma is a disease of environmental factors, the greatest of which is tobacco. These tumours usually arise adjacent to the lower molars along the occlusal line of the teeth. Buccal mucosa is the inner lining of the lips & cheeks.

## 2. Case Presentation

A 45 year male patient, who is a barber by occupation, had a small ulcer present in the right side of the mouth. Initially the ulcer was not taken seriously by the patient. But after some time, the patient realized that the ulcer was not healing and so he consulted a dentist. The dentist gave medications for it, but they did not work. After that, the patient consulted

many doctors, but did not find satisfactory results. Then the patient consulted a doctor who specializes in oral and maxillofacial surgery. According to the doctor's suggestion, the patient went for a biopsy. Biopsy reports showed squamous cell carcinoma of buccal mucosa on the right side which is in stage pT1N2b. This suggested that the primary tumour's depth is less than or equal to 2 cm and metastases in multiple lymph nodes. Patient had undergone surgery. Lower Alveotomy, BFP [Buccal Flap Pad] Grafting & EXT [Extraction] of tooth were done for removal of tumour. After the surgery, the patient took chemotherapy sessions. Patient had habit of tobacco chewing for 12 years and after the condition patient stopped tobacco chewing.

The individual was now facing difficulty with opening his mouth and with eating. This restricted him to just consuming a liquid diet. The patient experienced an increase in pain during mouth opening with time. Weight loss was present after the surgery. On examination, we observed the patient's mouth deviated slightly towards the right side [fig.-1] and also swelling. Orthognathic facial profile [fig.-2], overjet and overbite were normal.<sup>3</sup> Muscle atrophy was seen at the right side cervical region. Scar was present on the anterior neck region [fig.-3]. Patient's posture was forward headed. We also observed tenderness present over right-side cheek region grade-2 on palpation. Range of motion for depression of mandible [mouth opening] was around 8 mm and mandible protrusion was around 2 mm. Both were reduced. Range of motion for lateral excursion of mandible right and left side were normal.<sup>4</sup> Cervical side flexion of left side was reduced due to tightness of upper trapezius muscle on right side. Rest of all cervical motion and shoulder joint motion followed normal range. End-feel of all temporomandibular joint movements were abnormal tissue stretch. In Manual

Muscle Testing, muscles of jaw opening, jaw protrusion & left deviation, and right orbicularis oris were weak functional along with non-functional right buccinator.<sup>4</sup> Rest of all TMJ and Facial muscles were functional. Resisted Isometrics of TMJ left deviation is strong and painful. Resisted isometrics of rest of all TMJ and all cervical spine's movements were strong and pain-free. All testable Cranial Nerves were intact. Jaw jerk was normal grade 2+. All sensations over the C2 and C3 dermatomal region were intact grade 4. Scar was mobile, healed and pain-free. Special test for functional mouth opening – KNUCKLE Test was positive. Auscultation of TMJ was found to have no abnormal sounds. Mandibular measurement for each side was 14.5 cm. TMD Disability Index Questionnaire was taken for functional assessment. 41.67% Disability was found in the scale.

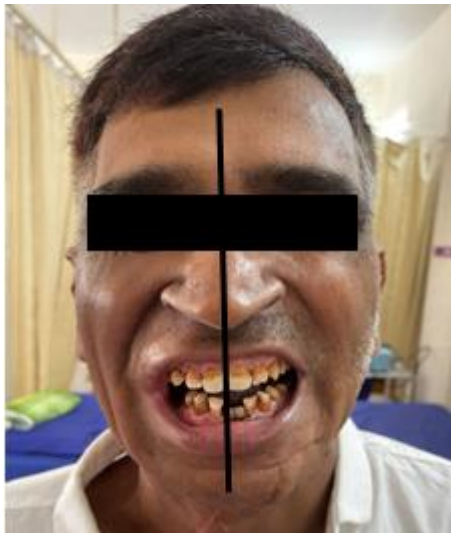

Figure 1

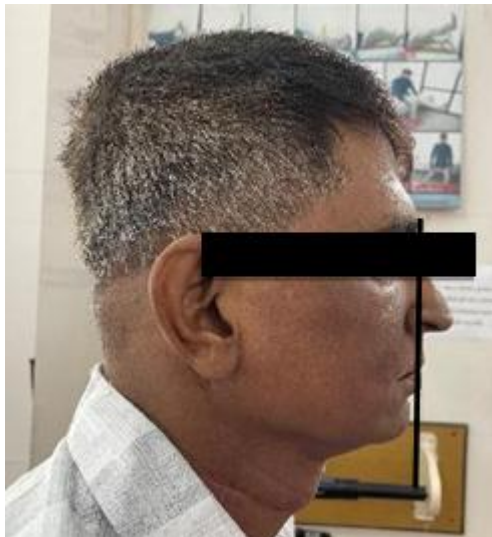

Figure 2

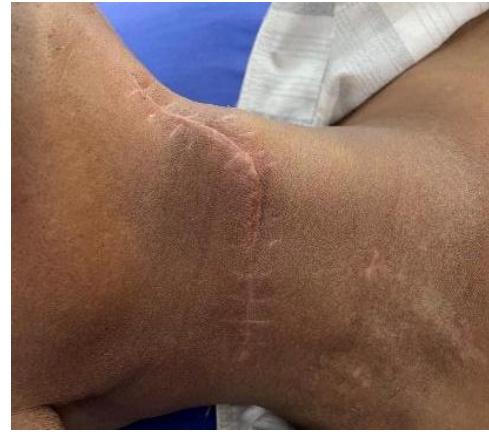

Figure 3

### 3. Treatment

The patient was instructed to emphasize diet and be careful use of the jaw. Because of the presence of an emotional overlay, counseling on how emotional conflicts are translated into muscle tension and pain is usually an important consideration. Point out that methods to achieve muscle relaxation and abolish well-established patterns of inappropriate muscular activity and methods to acquire new ones are important means of eliminating symptoms. The treatment protocol consisted of – Active ROM exercise with mirror biofeedback, TMJ Mobilization, passive stretch, relaxation exercise and additionally facilitatory exercise. In AROM exercise, the patient actively opens the mouth as wide as possible several times following a series of warm-up exercises. Tell the patient to open the mouth slowly and rhythmically within this limited range 10 times.<sup>5</sup> Also perform Lateral excursion and mandibular protrusion exercises. TMJ mobilization was given to the patient to maintain and improve ROM. Caudal traction and ventral glide were given to the patient. Passive prolonged static stretch is often advantageous and may be accomplished by using a series of tongue blades. Dosage: Following TMJ surgery, no more than 1 or 2 minutes of stretching is recommended.<sup>5</sup>

Fig-4 showed use of the tongue blade in passive stretching. Relaxation technique with using a modification of Jacobson's approach. This technique includes strong contraction against the therapist's hand, hold for 10 sec and then completely relax the muscles. In Facilitatory exercise, resisted neck motion may facilitate tongue motions as well as mandibular motions. In general, facial and mandibular motions that require depression or downward motions are facilitated by neck flexion.<sup>5</sup> For pain and swelling reduction, ice massage was given over the painful area for 10 mins.

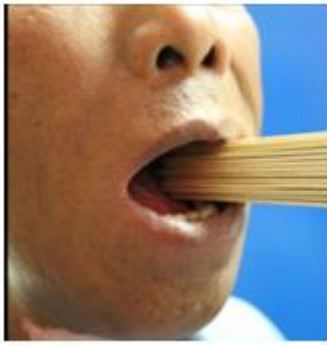

Figure 4

#### 4. Outcome & Follow-Up

During the pre-treatment period, the patient was only consuming a liquid diet as mentioned before. After 2 months follow up, functional tasks evaluation was taken. At this time, it was reported that the patient was able to eat soft,

semisolid food. Also, the patient was able to perform some activities such as cleaning his teeth and yawning. Pre-treatment mandible depression ROM was 8 mm and TMD disability questionnaire's score was 41.67%. After 2 months follow up mandibular depression ROM was 18 mm and TMD disability questionnaire's score was 22.22%. Table 1 shows pre and post evaluation of ROM and Disability score. Fig.-5 shows results of pre and post treatment evaluation. Chart showed that Range of mandible depression [mouth opening] was increased and the disability score was reduced.

Table 1

Outcome-Measures	Initial Evaluation	After 2-month Evaluation
Range of motion	8 mm	18 mm
TMD Disability Index Que.	41.67%	22.22%

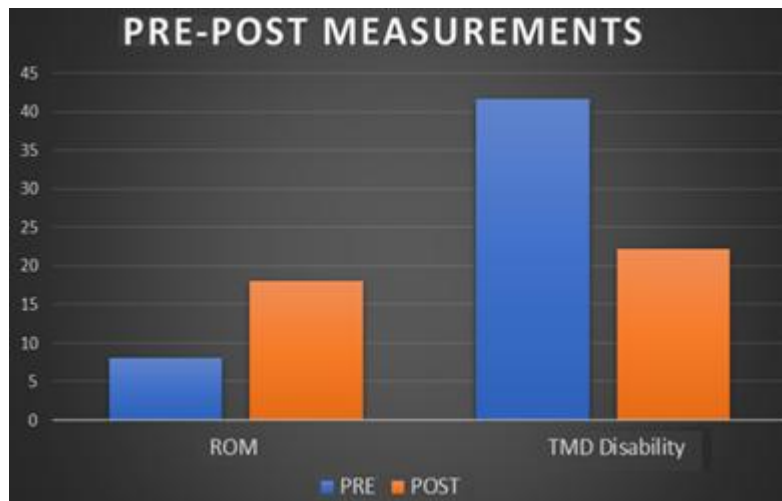


Figure 5

#### 5. Discussion

One of the less common causes of pain in the area of the temporomandibular joint are oral cancers. The most common oral cancer is squamous cell carcinoma.<sup>7</sup> These cancers often present in the later stages of the disease where the treatment is more complicated and survival is less likely. Squamous cell carcinoma (SCC) of the buccal mucosa is a common malignant tumour in India.<sup>8</sup> Risk factors associated with SCC include betel quid chewing, tobacco and alcohol consumption.<sup>9-11</sup> Conservative management of physical therapy, consisting of multifaceted treatment strategies, including manual techniques, exercise instruction, and patient education was successful in this case. In this work, we presented a case of a young patient with severe pain and limited mouth opening that emerged after surgical removal of carcinoma. The primary therapeutic goal was to resolve the pain by icing and to increase the range of motion by physical therapy. At 2 months follow up, the patient reported improvement of symptoms. Awareness of physiotherapy in this type of case is very rare. Thus with this work, we show the importance and effectiveness of physiotherapy treatment in Temporomandibular Joint Dysfunction after surgery.

#### 6. Conclusion

##### Implications for Clinical Practice:

A patient with the diagnosis of right side temporomandibular joint dysfunction and who were on liquid diet could benefit from isometrics, passive stretches & facilitation exercises to improve ROM. The use of relaxation techniques may improve patient's function & with increased movement patient reports decrease in pain.

##### Implications for Future Research:

Further case reports exemplifying the most effective physical therapy treatment for TM Joint Dysfunction are still needed.

##### Acknowledgement

I acknowledge my guide for assistance with case report conceptualization and with patient treatment and the patient for compliance and co-operation and participation with the case report.

## References

- [1] Pamela K. Levangie, Cynthia C. Norkin, Joint structure and function, 5<sup>TH</sup> Edition, chapter 6, page no. 215.
- [2] Scully S, Porter S. Clinical review, ABC of oral health, Oral cancer. BMJ 2000; 321:97–100.
- [3] David J Magee; orthopaedic physical assessment
- [4] Cynthia C. Norkin, D. Joyce White; measurement of joint motion, a guide to goniometry, 5<sup>TH</sup> Edition, chapter 13, page no. 522-529
- [5] Denials and Whigham's muscle testing
- [6] Randolph M. Kessler, Management of common musculoskeletal disorders, Physical therapy principles & method, 4<sup>th</sup> edition
- [7] Scully S, Porter S. Clinical review, ABC of oral health, Oral cancer. BMJ 2000; 321:97–100
- [8] Fang QG, Shi S, Li ZN, Zhang X, Liua FY, Xu ZF, Sun CF. Squamous cell carcinoma of the buccal mucosa: Analysis of clinical presentation, outcome and prognostic factors. Mol Clin Oncol. 2013 May;1(3):531-534.
- [9] Huang CH, Chu ST, Ger LP, Hou YY and Sun CP: Clinicopathologic evaluation of prognostic factors for squamous cell carcinoma of the buccal mucosa. J Chin Med Assoc 70: 164-170, 2007. 2.
- [10] Ghoshal S, Mallick I, Panda N and Sharma SC: Carcinoma of the buccal mucosa: analysis of clinical presentation, outcome and prognostic factors. Oral Oncol 42: 533-539, 2006. 3.
- [11] Freedman ND, Abnet CC, Leitzmann MF, Hollenbeck AR and Schatzkin A: Prognostic investigation of the cigarette smoking-head and neck cancer association by sex. Cancer 110: 1593-1601, 2007