

A Rare Case of Haemangioma around Common Carotid Artery

Dr. Anismita Das^{1*}, Dr. Ajay Dayma², Dr. Ashwini Kumar Seelam³

^{1,3}Resident Doctor

²Assistant professor Department of General surgery, National Institute of Medical Science, Jaipur, Rajasthan, India

Abstract: **Background:** Haemangioma are benign neoplasms derived from blood vessels which multiply at an abnormal rate and form a mass or lump. Most Haemangioma common in infant and also common in female than male. They can occur throughout the body, including in skin, muscle, bone, and internal organs. It mostly occurs on the surface of the skin or just beneath it. They often develop on the face and neck, and can vary greatly in colour, shape, and size. Deep Haemangioma tends to grow later and longer than superficial ones. Patients often remain asymptomatic or present with nonspecific symptoms, such as headache. This is the first Haemangioma to be reported as encircled the common carotid artery. Carotid sheath Haemangioma may be easily misdiagnosed as arterial aneurysms, neurogenic tumors, paragangliomas, or lymphatic masses. **Method:** We report a case of Haemangioma in a 33 years female, who presented with gradually progressive swelling at lateral side of left neck for 7 years. She also complained of pain in the left side of face, neck and hand for 15 days. Mass presented from the carotid bifurcation to superior mediastinum. The diagnosis couldn't be stated on the basis of history, clinical and radiological examination findings. **Results:** Successful surgical excision of the Haemangioma is performed with precise dissection which engulfed common carotid artery. Histopathological examination confirms the diagnosis of haemangioma. **Conclusion:** A rare case of haemangioma presented with circumferentially encased common carotid artery from carotid bifurcation to superior mediastinum. Haemangioma was successfully excised without any surgical complication.

Keywords: case, haemangioma, common carotid, arterial, tumor, surgical

1.Introduction

Haemangioma is benign neoplasm derived from blood vessels which multiply at an abnormal rate and form a mass or lump. They can occur throughout the body, including in skin, muscle, bone, and internal organs. Most haemangioma occur on the surface of the skin or just beneath it. They often develop on the face and neck, and can vary greatly in colour, shape, and size. Haemangioma is more common in infant and also common in female than male.

There are several types of Haemangiomias. Some of them are described below:

- Capillary Haemangioma-This is the most common type of Haemangioma. It is made up of small capillaries that are normal in size and diameter, but high in number. It develops in the skin and often superficial. They are typically bright red in colour. They can be small or large in size and may be flat to the skin, raised, or protrude out as a nodule.
- Cavernous Haemangioma - It made up of larger blood vessels that are dilated. When they develop in the skin, cavernous Haemangioma is often referred to as deep, and sometimes first appear as a bluish swelling underneath the skin. This type also varies greatly in size and can occur throughout the body.
- Compound Haemangioma-Some Haemangioma is a mix of the capillary and cavernous types.
- Lobular capillary Haemangioma - They are small, red often appear on the hands, face, and arms. Because they contain so many blood vessels, they bleed easily with trauma. This type of Haemangioma is also sometimes referred to as a pregnancy tumour because they often appear during pregnancy, typically in the nose and mouth.

Deep Haemangioma tends to grows later and larger than superficial ones. Patients often remain asymptomatic. This is the first case of Haemangioma to be reported as encircled the common carotid artery. Carotid sheath Haemangioma may be easily misdiagnosed as arterial aneurysms, neurogenic tumours, paragangliomas, or lymphatic masses.

2.Case Summary

A 33 years female presented to the surgery OPD with a chief complaint of a painless swelling in the left side of the neck.

- The swelling had been present for the past 7 years and had a gradual progressive course.
- Over the past 2 months, the patient complained of numbness over the neck, face, and radiating to the hand.
- The patient experienced pain over the neck while sleeping on the left side of the face.
- There was no history of trauma, difficulty in breathing, facial puffiness, flushing of face, difficulty in deglutition, hoarseness of voice, or palpitations.
- In the patient's past history, she had tuberculosis during her first pregnancy in 2009 and received anti-tuberculosis therapy (ATT) for 12 months.
- There was no history of hypertension, diabetes, asthma, or any other comorbid illness.
- The patient had a history of tubal ligation performed in 2015 under spinal anesthesia.
- Menstrual cycle was regular, with the last menstrual period (LMP) on 18/5/2023.

Physical Examination Findings:

- General examination revealed the patient is normal build, weighing 39 kg, with a height of 156 cm.
- No pallor, icterus, lymphadenopathy, edema, or clubbing was noted.

Vital signs:

- Pulse rate: 98/min, regular rhythm on left radial artery.
- Blood pressure: 110/80 mm Hg. On left upper limb.
- Respiratory rate: 16/min. thoraco-abdominal.
- Oxygen saturation (SpO₂): 98% on room air.

Systemic examination:

- Chest examination revealed bilaterally equal air entry with no added sounds.
- Cardiovascular examination detected the presence of normal S1 and S2 heart sounds.

Physical examination:

Presence of a single non-pulsatile, non-tender mass on the left side of the neck from carotid bifurcation to supra sternal notch, which is 7×4 cm² cylindrical shaped with regular margins and firm in consistency without associated tenderness or skin changes. There is no engorged veins or tracheal deviation. No Fluctuation and trans-illumination.

These physical examination findings provide valuable information for further evaluation. Additional investigations done to determine the nature of the neck swelling and establish an appropriate diagnosis and treatment.



The arrow shows a single swelling in the left side of the neck

Preoperative Investigations:

-Present the results of relevant preoperative investigations, including:

1. Haemogram:

- Hemoglobin: 12.3 g/dl
- Total leukocyte count (TLC): $5.65 \times 10^3/\mu\text{l}$
- Platelets: $206 \times 10^3/\mu\text{l}$

2. PT/INR:

- Prothrombin time (PT): 12.8 seconds
- International normalized ratio (INR): 0.94

3. Random blood sugar: 86 mg/dl

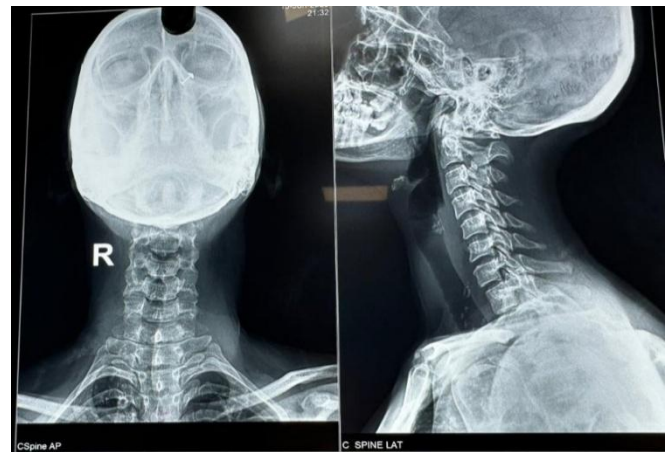4. T3 - 1.5

T4 - 8.6

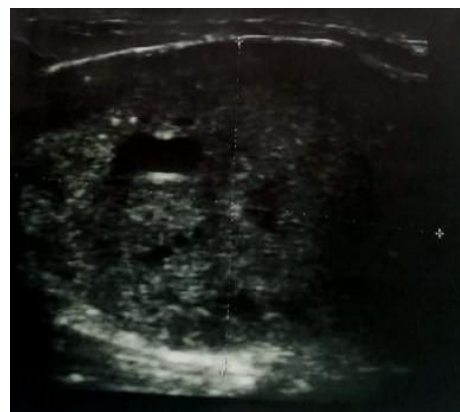TSH - 3.4

Special Investigation:

- X-ray Neck



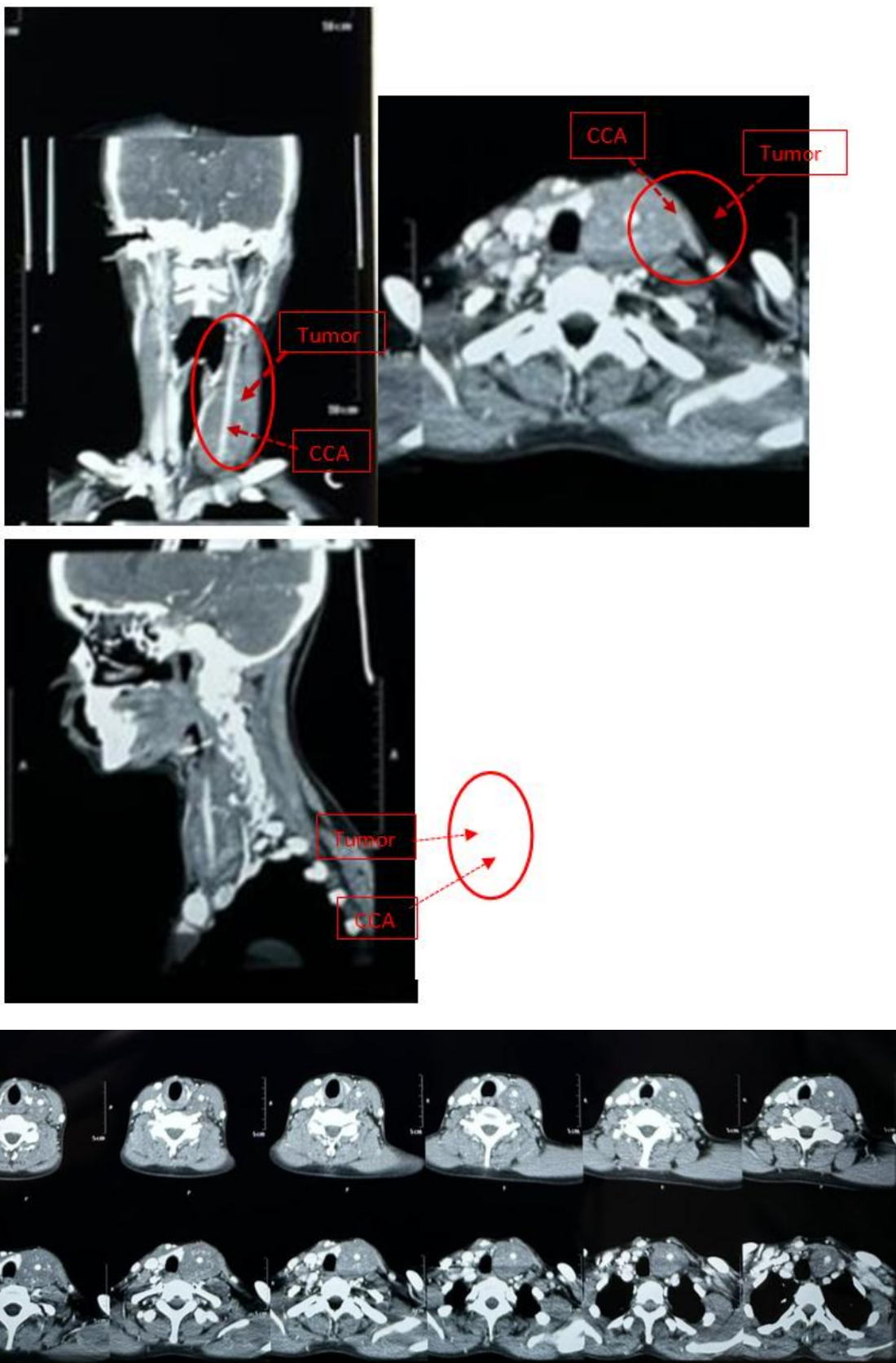
- USG neck suggestive of Large well defined heteroechoic lesion measuring approx. 4.3×2.7×3.2 cm seen on the left side of neck. Peripheral and internal vascularity is seen. The lesion encased the left common carotid artery within it in entire extent. The lower extent of lesion inviscualized, retrosternal extent could not be ruled out suggestive of ?carotid body tumor, ?schwanoma



- Colour Doppler of carotid Arteries study, showing Aheterogeneously lesion with internal vascularity and cystic areas measuring 80×33×38 mm noted along the length of left common carotid artery, encircling it upto the bifurcation. Suggestive of carotid body tumor, paraganglioma.

- CECT neck, revealing

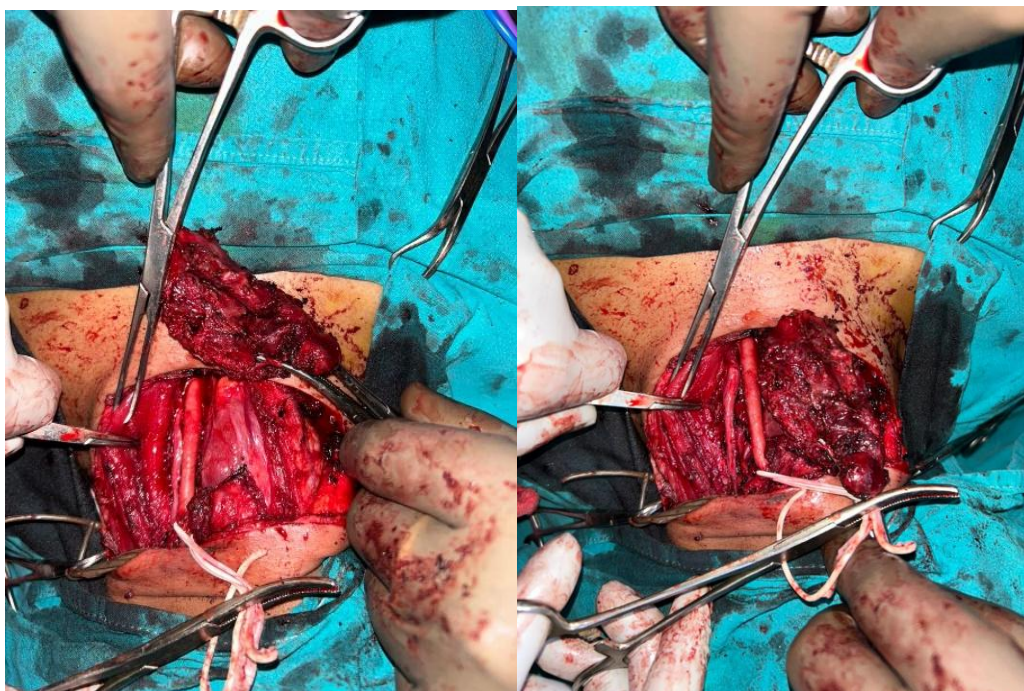
A large vascular mass in the left side of the neck with encasement of the left common carotid artery, consistent with a carotid body tumor.



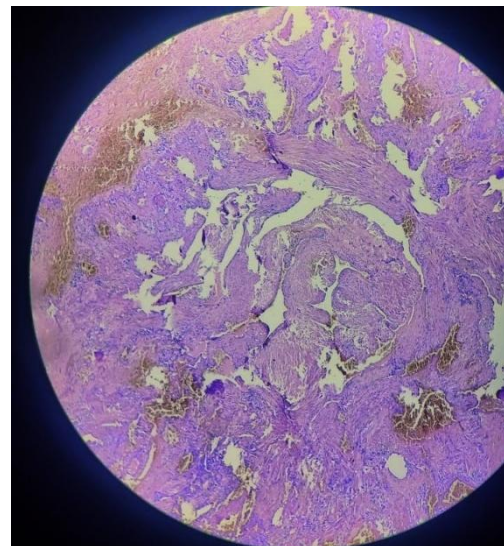
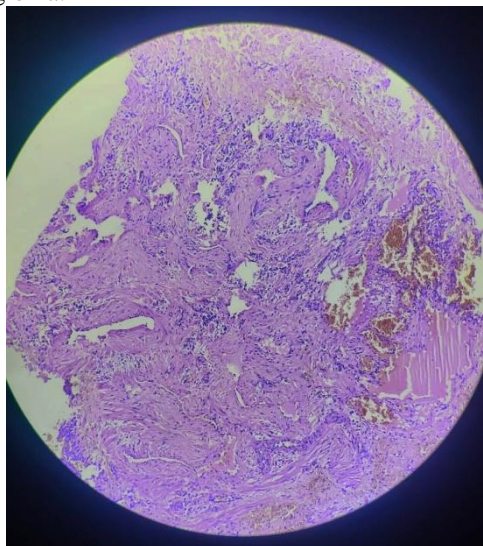
- USG guided FNAC done which suggestive of Hemangiomas vascular tumor.

Operative finding:

- A horizontal incision of 10 cm made above the swelling and deepened through the platysma.
- 7 cm vascular, firm mass present encircling the common carotid artery from sternal notch up to bifurcation of it.
- Took the proximal and distal control of common carotid artery below and above the tumor.
- Then we have created the plane between hemangioma and common carotid artery.
- Cut the tumor above to downwards anterior side with the help of ligasior.
- Once the whole of the tumor dissected and separated from common carotid artery then separate from the other part.
- Rest of the tumor separate from posterior tissues and send for histopathy.
- Romovac placed and closed layer by layer.
- Postoperative care and follow-up continued for the patient's recovery and monitoring of any potential complications.



Histopathology report of the specimen suggestive of Hemangioma.

**3. Discussion**

The data that examines Haemangioma which localized encircled the common carotid artery are extremely rare. They are very often asymptomatic and incidentally discovered. Cavernous Haemangioma is a congenital venous malformation that occurs throughout the entire body

but it is rarely localized in the common carotid artery. Histologically, Haemangioma originates from residual embryonic vascular cells and is caused by abnormal vascular development at the embryonic stage. So far, to the best of our knowledge, our case is the first case of cavernous haemangioma encircled common carotid artery reported in the literature. Haemangioma grow by endothelial cell hyperplasia and should be differentiated

Volume 12 Issue 9, September 2023

www.ijsr.net

Licensed Under Creative Commons Attribution CC BY

from vascular malformations, which are not true neoplasms but are localized defects of vascular morphogenesis. Their confirmation always needs a surgical approach followed by histologic evaluations. In our case, neither the ultrasound nor the scanner made the diagnosis. The choice of treatment is dependent on the related organ and can include sclerotherapy, embolization, and surgical resection. Reviewing previously reported cases in the literature and complete surgical resection is generally accepted as the definitive and effective treatment of choice.

4. Conclusion

In conclusion, the case presented a 33 years female with a painless swelling in the left side of the neck, which had been progressively growing over a period of 7 years. The patient also reported numbness in the neck, face, and hand, along with pain while sleeping on the left side of the face. Physical examination revealed a non-pulsatile mass on the left side of the neck, measuring approximately 7x3 cm.

Preoperative investigations, including hemogram, PT/INR, random blood sugar, Doppler study, and CECT neck, USG guided FNAC confirmed the presence of a Hemangioma. The tumor was found to be encircling the left common carotid artery, indicating its involvement with the vasculature.

Surgical intervention was performed with the patient under general anesthesia. A horizontal incision was made above the swelling, and the tumour was meticulously dissected, separating its margins from the surrounding tissues and preserving vital structures such as the common carotid artery, internal jugular vein, and vagus nerve. Complete tumor excision was achieved, and hemostasis was ensured. A Romovac drain was placed below the sternocleidomastoid plane for postoperative drainage.

The successful excision of the Hemangioma not only provided relief from symptoms but also addressed the potential risks associated with the tumor's growth and its encasement of the common carotid artery. Postoperative care and regular follow-up will be crucial for monitoring the patient's recovery and evaluating any potential complications.

Overall, the surgical intervention aimed to eliminate the Haemangioma, restore normal vascular flow, and improve the patient's quality of life. The successful management of this case highlights the importance of prompt diagnosis, careful surgical planning, and skilled execution in the field of general surgery.

References

- [1] Anajar S, Nawal B, Amal H, Fouad B. Internal jugular vein cavernous hemangioma occurring as lateral neck mass: Case report. *International Journal of Surgery Case Reports*.2021 Aug 1; 85: 106205.
- [2] Murphy T, Ramai D, Lai J, Sullivan K, Grimes C. Adult neck hemangiolympangioma: a case and review of its etiology, diagnosis and management. *Journal of Surgical Case Reports*.2017 Aug; 2017 (8): rjx168.

- [3] Abraham MJ, Gregory ND, Chennupati SK. Epithelioidhemangioma of the internal carotid artery: a case report supporting the reactive pathogenesis hypothesis of this vascular tumor. *International Journal of Pediatric Otorhinolaryngology*.2014 Jul 1; 78 (7): 1186-9.
- [4] Al-Muharraqi MA, Faqi MK, Uddin F, Ladak K, Darwish A. Angiolymphoid hyperplasia with eosinophilia (epithelioidhemangioma) of the face: an unusual presentation. *International Journal of Surgery Case Reports*.2011 Jan 1; 2 (8): 258-60.
- [5] Buckmiller LM, Richter GT, Suen JY. Diagnosis and management of hemangiomas and vascular malformations of the head and neck. *Oral diseases*.2010 Jul; 16 (5): 405-18.
- [6] Kiymaz N, Yilmaz N, Suleyman OZ, Demir I, Gudu BO, Kozan A. Cavernous hemangioma presenting as a giant cervical mass: a case report. *Turkish Neurosurgery*.2010 Jan 1; 20 (1).
- [7] Antonopoulos C, Karagianni M, Zolindaki C, Anagnostou E, Vagianos C. Cavernous hemangioma of infrahyoid carotid sheath and review of the literature on carotid sheath tumors. *Head & Neck: Journal for the Sciences and Specialties of the Head and Neck*.2009 Oct; 31 (10): 1381-6.
- [8] Zagzag J, Morris LG, DeLacure MD. Cavernous hemangioma of the carotid sheath. *Otolaryngology—Head and Neck Surgery*.2009 Apr; 140 (4): 608-9