

Twin - Twin Transfusion Syndrome - Case Series

Dr. Shainaz Tabassum¹, Dr. H. E Ramaraju², Dr. Anagha Shyam Prasad³

¹Junior Resident, Vijayanagar Institute of Medical Sciences, Ballari

²Associate Professor VIMS, Ballari

³Junior Resident, Vijayanagar Institute of Medical Sciences, Ballari

Abstract: *Twin to twin transfusion syndrome (TTTS) is a rare but serious complication of monochorionic twin pregnancy. It is characterized by development of abnormal placental vascular communication from one foetus (donor) to other foetus (recipient). TTTS has high rate of mortality and morbidity, affects 8–15% MCDA pregnancies, the severity is categorised using Quintero Stages I–V. The aims of this paper are to describe the characteristics and outcomes of TTTS cases treated at our hospital. The primary outcome was survival of one or both twins at delivery. Secondary outcomes were GA & ultrasound findings at diagnosis of TTTS & mode of delivery.*

Keywords: Twin pregnancy, twin to twin transfusion syndrome, vascular anastomoses, monochorionicity, placenta, oligohydraminos, polyhydraminos, Discordant, Donor, recipient

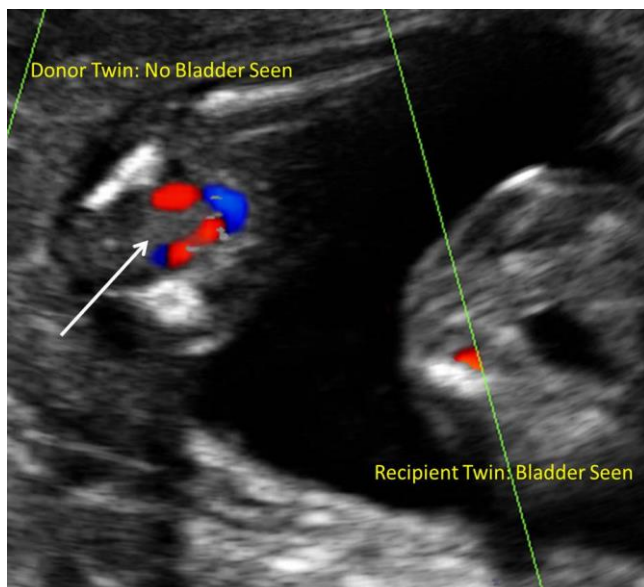
1. Introduction

Twin - twin transfusion syndrome occurs in multiple gestations and involves a chronic flow of blood from one twin to another twin and is a rare entity. The basis of the syndrome is a placental vascular anomaly. Placental anastomoses linking the two foeto - placental circulations produce an uncompensated net transfusion of blood from the donor to the recipient twin.

2. Methods

The pregnancy data was collected from VIMS, Ballari over a period of 6 months. This study included all cases irrespective of gestational age with ultrasound scan features suggestive of TTTS.

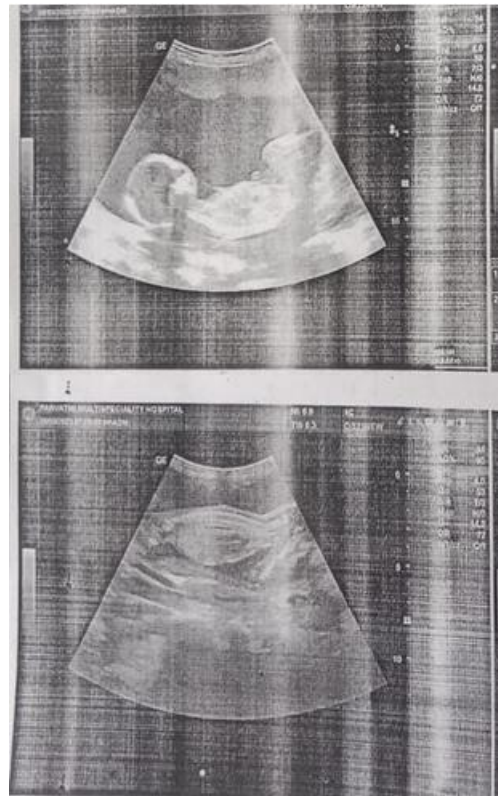
Case 1



- A 28y old, G3P2L2 with 30 weeks 1 day with MCDA type of twin gestation came with USG suggestive of TTTS type 3.

- USG - Poly - Oli syndrome, 33% weight discrepancy with CPR abnormality in 1 twin.
- COURSE - Patient underwent emergency LSCS, Twin 1 of BW - 1.9 kg and twin 2 - 1.1 kg were extracted.
- Twin 2 was referred to NICU and died on 6th post natal day.

Case 2



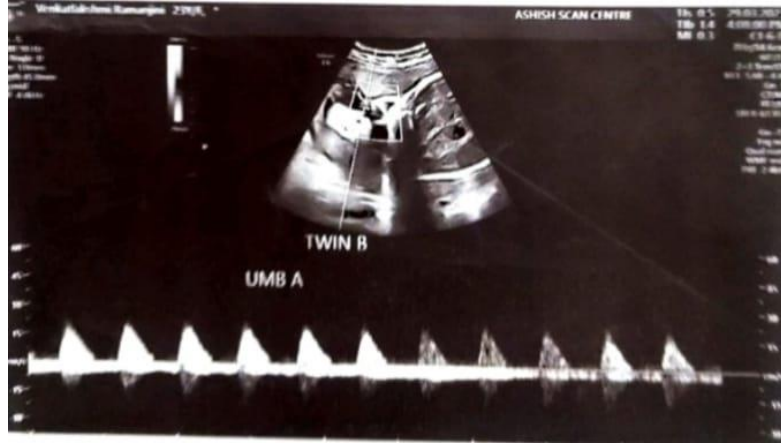
- A 22y old G2P1L1 with 18 weeks 3 days with previous LSCS with MCDA type of twin gestation with scans suggestive of TTTS Type 2, came with complains of bleed PV.
- USG - Twin 1 - AFI of 16cms, with twin AFI - 2cms, with EFW - 12% discrepancy with features suggestive of TTTS.

Volume 13 Issue 5, May 2024

Fully Refereed | Open Access | Double Blind Peer Reviewed Journal

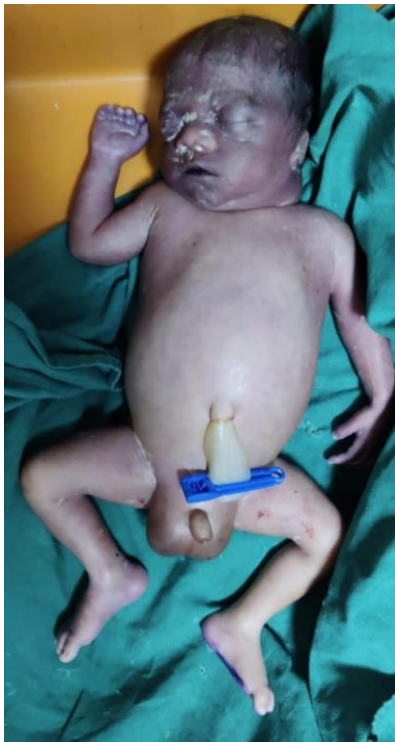www.ijsr.net

- COURSE - Patient underwent spontaneous expulsion of products of conception. **Case 3**



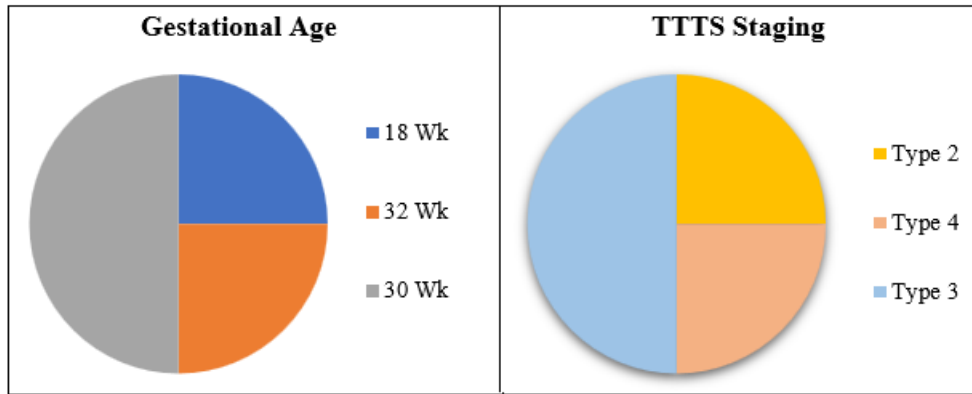
- A 23y old, Primigravida with 32 weeks 5 days with imminent eclampsia with MCDA type of twin gestation came with USG suggestive of TTTS type 3.
- USG - EFW - 26% weight discrepancy, AEDF in umbilical artery and raised MCA PI in twin 2.
- COURSE - Patient underwent emergency LSCS, Twin 1 of BW - 1.7 kg and twin 2 - 1.2 kg were extracted.
- Both twins were referred to NICU and survived early neonatal period.
- A 30y old, G3P2L2 with 30 weeks 2 days with MCDA type of twin gestation came with USG suggestive of TTTS type 4.
- USG - EFW - 35% weight discrepancy, changes of hydrops in twin 1, with anhydraminos in twin 2.
- COURSE - Patient delivered vaginally, Twin 1 of BW - 2.1 kg (stillbirth) and twin 2 - 1 kg.
- Twin 2 was referred to NICU and died on 3rd post natal day.

Case 4



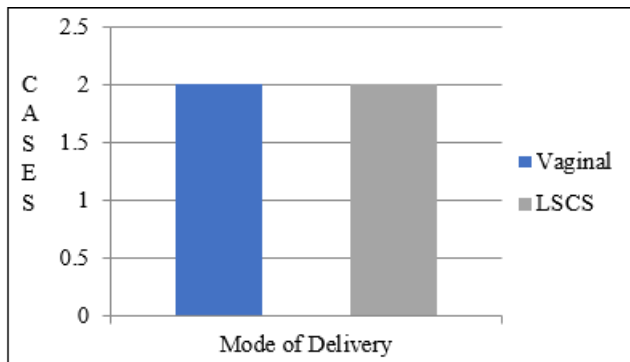
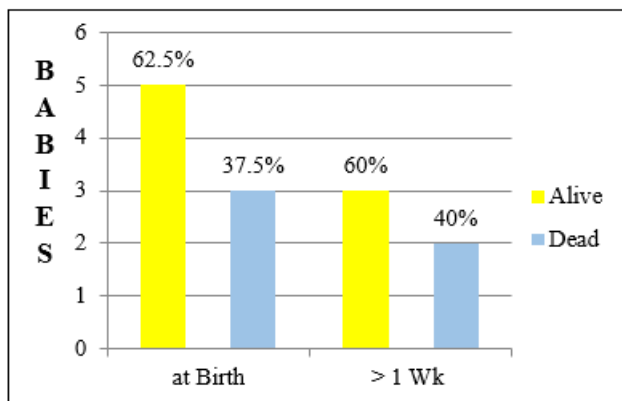
3. Results

There were 4 MCDA - TTTS pregnancies assessed



Mean GA was 30 weeks with TTTS Stage III being the most common stage at diagnosis 2/ 4 (50%). Quintero staging was applied to all 4 (100%) cases.

AFI discrepancy - mean DVP in donor is 12cms, recipient - 1.75cms with mean EFW discordance of 26.5%. 2 cases (50%) underwent caesarean while 2 (50%) delivered vaginally.



The median time from diagnosis TTTS (all stages) to termination was 1.5days. The rate of pre - term birth before 32 weeks (75%).

Overall survival - 3 (75%) of 4 cases had atleast one livebirth i. e, 5/8 twins (62.5%), 3 (37.5%) babies were stillborn, while 2 (25%) died within 1 week of delivery.

There were no cases of amnioreduction

4. Conclusion

The limitations are that case series included relatively small numbers. TTTS is difficult and threatening diagnosis. Successful management of TTTS depends on multidisciplinary care team with family-centered approach to optimize the best outcome. It is concern regarding these complications that constrains when treatments can be offered. Treatment includes conservative management, fetoscopic laser photocoagulation, amnioreduction, septostomy, selective reduction by radiofrequency ablation (RFA) or cord occlusion, or termination of pregnancy due to grim prognosis.

References

- [1] Mylrea-Foley B, Shaw CJ, Harikumar N, Legg S, Meher S, Lees CC. Early-onset twin-twin transfusion syndrome: Case series and systematic review. *Australasian Journal of Ultrasound in Medicine*.2019 Nov; 22 (4): 286 - 94.
- [2] Kim MJ, Kim HM, Cha HH, Kim H, Kim HS, Seong WJ. Acute twin - to - twin transfusion syndrome resulting in fetal bradycardia and neonatal death: a case report. *Medicina*.2022 Dec 9; 58 (12): 1813.
- [3] Bansal R, Kaur J. Twin - Twin transfusion syndrome: a case report. *International Journal of Reproduction, Contraception, Obstetrics and Gynecology*.2020 Mar 1; 9 (3): 1282 - 5. .
- [4] Agrawal P, Vaidya A, Vaidya A, Phuyal S, Pandey A. Twin to Twin Transfusion Syndrome: A Case Report. *JNMA: Journal of the Nepal Medical Association*.2022 Dec; 60 (256): 1056.
- [5] Zondervan HA, van Gemert MJ, Nikkels PJ, Omtzigt A, Offringa M, Deprest J, Bleker OP. Twin - to - twin transfusion syndrome: a case report. Antepartum prediction of underlying placental vascular pattern in monochorionic twin pregnancies may be possible. *Twin Research and Human Genetics*.1999 Aug; 2 (4): 286 - 9.
- [6] Squires LS. A Case Study of Recipient Twin Surviving Complications of Twin-to-Twin Transfusion Syndrome. *Nursing for Women's Health*.2013 Oct 1; 17 (5): 390 - 8.