

# Ophthalmic Artery Doppler as a Reliable Tool for Screening and Diagnosing Preeclampsia in a Rural South Indian Population

Shreya Shetty<sup>1</sup>, Mohan Siddappa<sup>2</sup>, Praveen Ramegowda<sup>3</sup>, Anand S. H.<sup>4</sup>

**Abstract:** Preeclampsia (PE), a hypertensive disorder manifesting after 20 weeks of gestation, poses significant risks to both maternal and fetal health. This prospective case - control study, conducted from January to September 2023, aimed to evaluate the predictive potential of ophthalmic artery Doppler waveform analysis for PE outcomes. Thirty pre - eclamptic cases and 30 matched pregnant controls were included, with Doppler parameters recorded using a GE Voluson S8 Ultrasound machine. The study found that various Doppler parameters, including mean peak systolic velocity, pulsatility index, resistivity index, and peak ratio, significantly differed between pre - eclamptic cases and controls ( $p$  - value  $< 0.001$ ). Notably, resistivity index and peak ratio effectively distinguished between mild and severe PE, exhibiting high sensitivity and specificity. A Doppler cut - off of 23.3 cm/s demonstrated modest sensitivity (78.2%) and specificity (83.9%) for early - onset PE prediction. Discussion highlights the higher mean age of mothers with PE and the significance of lower impedance in the ophthalmic artery, indicating abnormal hemodynamics beyond normal vasodilatation. Unlike healthy pregnancies, PE - related impedance indices decrease alongside lower peak systolic velocity. In conclusion, ophthalmic artery Doppler emerges as a valuable, non - invasive tool for diagnosing both overall and severe preeclampsia. Parameters like resistivity index, peak ratio, and pulsatility index exhibit high sensitivity and specificity, making ophthalmic artery Doppler a potential screening method for early detection of hemodynamic changes associated with preeclampsia in high - risk cases.

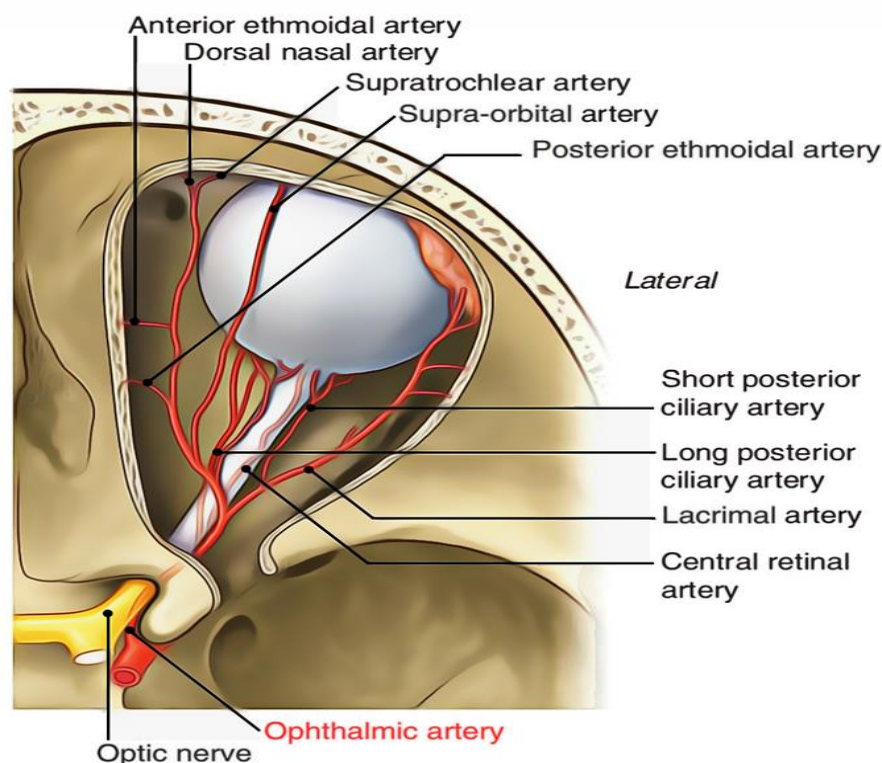
**Keywords:** Preeclampsia, hypertensive disorder, gestation, fetal health

## 1. Introduction

Preeclampsia (PE), a hypertensive disorder emerging after the 20th week of gestation, presents a formidable health challenge during pregnancy. Left untreated, it can escalate into eclampsia, a severe complication associated with life - threatening complications. The pathophysiology of PE involves significant hemodynamic alterations, impacting blood circulation in critical vessels such as the internal carotid

and ophthalmic artery, leading to consequential neuro - ophthalmic manifestations.

Recognizing the embryological similarities shared between the ophthalmic artery and less accessible intra - cranial circulation, we turn to the ophthalmic artery as a promising avenue for non - invasive exploration. Its accessibility within the orbit makes it an ideal candidate for Doppler scanning, offering a unique insight into the intricate hemodynamic changes associated with PE.



Volume 13 Issue 5, May 2024

Fully Refereed | Open Access | Double Blind Peer Reviewed Journal

[www.ijsr.net](http://www.ijsr.net)

In light of these considerations, our research endeavors are strategically directed towards identifying non - invasive, safe, and reliable screening markers for PE. The ophthalmic artery's role becomes particularly pivotal in this quest, given its potential to serve as a window into the broader complexities of PE - induced circulatory changes. This study explores a novel approach to predict the onset and progression of PE by scrutinizing the Ophthalmic artery Doppler waveform. This method gains significance as PE is known to cause visual impairment in a substantial percentage of affected individuals, ranging from 30% to 100%.<sup>(1)</sup>

## 2. Methodology

A prospective case - control study was conducted at the Department of Radiology from January to September 2023, encompassing 30 consenting cases with pre - eclampsia and 30 carefully matched pregnant controls.

### Inclusion Criteria:

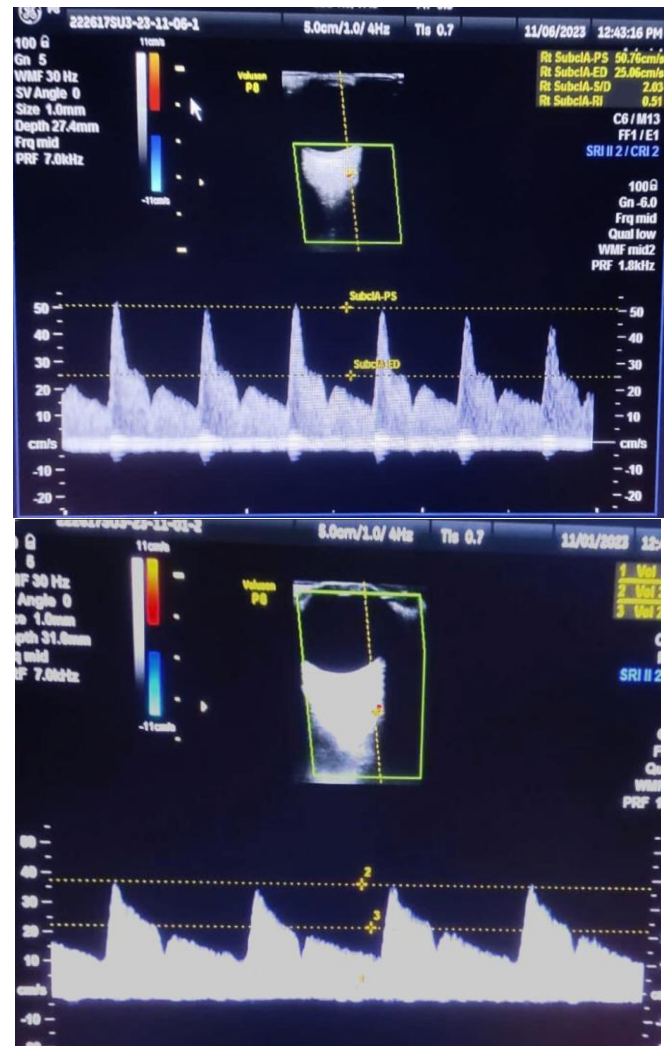
All pregnant women, 20 weeks gestational age and beyond, presenting for routine ultrasound scans at the daily Out - patient Department, were eligible for inclusion upon obtaining their informed consent.

### Exclusion Criteria:

- Exclusions comprised women with multiple gestations, a history of anti - hypertensive medication or corticosteroid use, and a previous ocular disease. Non - consenting participants were also excluded. Cases meeting inclusion criteria were designated as pre - eclamptic, while normotensive pregnant women were selected as controls.
- Both groups were meticulously matched for maternal age, gestational age, and parity. Gestational age was calculated based on the first - trimester scan or, in the absence of prior data, from the Last Menstrual Period. Blood pressure was measured following a 15 - minute rest, utilizing a sphygmomanometer and estimating mean arterial pressure.
- The study employed a GE Voluson S8 Ultrasound machine. Subjects rested in the supine position for 5 minutes. A 7.5 MHz linear transducer sequentially scanned both eyes. The transducer, placed gently over the closed upper eyelid in the axial position, facilitated Colour Flow Doppler identification of the ophthalmic artery superomedial to the Optic nerve.

### Doppler Assessment:

Pulsed wave Doppler, with an insonation angle <20°, recorded 3 to 5 waveforms per eye. The sample gate (1 mm) covered the entire vessel at a depth of 3.0 to 4.5 cm. The characteristic ophthalmic artery waveform, featuring two systolic peaks, was analyzed using four indices for each eye: first peak systolic velocity (PSV), resistive index (RI), pulsatility index (PI), and the ratio of second to first PSV (PSV2/PSV1). While the machine automatically obtained the first PSV, RI, and PI, the second PSV was manually measured, and PSV2/PSV1 was individually calculated for each eye



## 3. Results

In our comprehensive study involving 30 pre - eclamptic cases and matched normotensive pregnant controls, noteworthy findings emerged that underscore the clinical significance of ophthalmic artery Doppler assessment.

Characteristic	Control	Cases	Inference
Age	27	27.87	Increased
GA	28.2	29.2	Increased
SBP	115.46	141.67	Increased
DBP	75.13	94.67	Increased
MAP	88.6	110.2	Increased
PI RT EYE	1.77	1.2	Decreased
PSV 1 RT EYE	31.8	20.6	Decreased
PSV RATIO RT EYE	1.79	1.32	Decreased
EDV RT EYE	7.46	7.9	Increased
RI RT EYE	0.76	0.64	Decreased
PI LT EYE	1.7	1.1	Decreased
PSV 1 LT EYE	31.75	29.13	Decreased
PSV RATIO LT EYE	1.85	1.31	Decreased
EDV LT EYE	8.4	12.71	Increased
RI LT EYE	0.74	0.6	Decreased

### Clinical Profile:

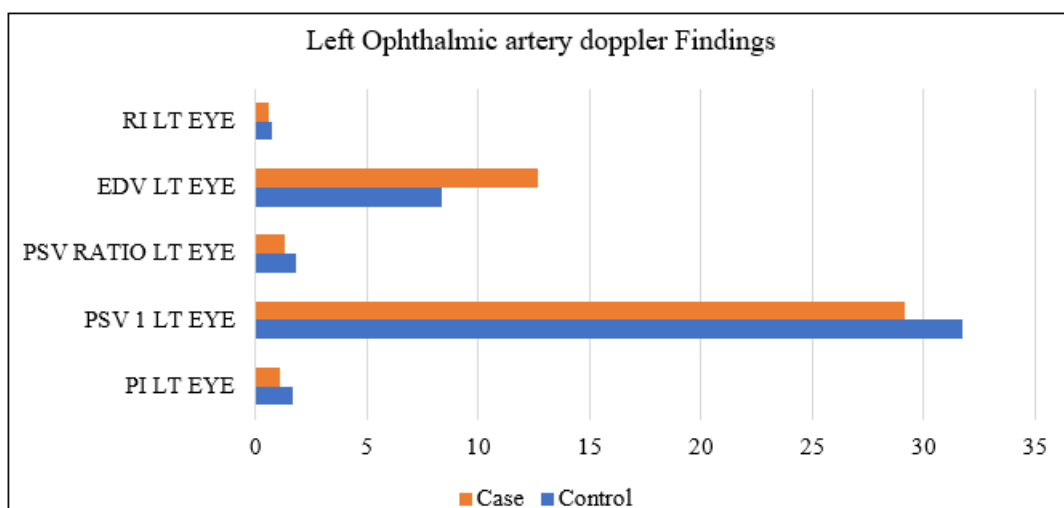
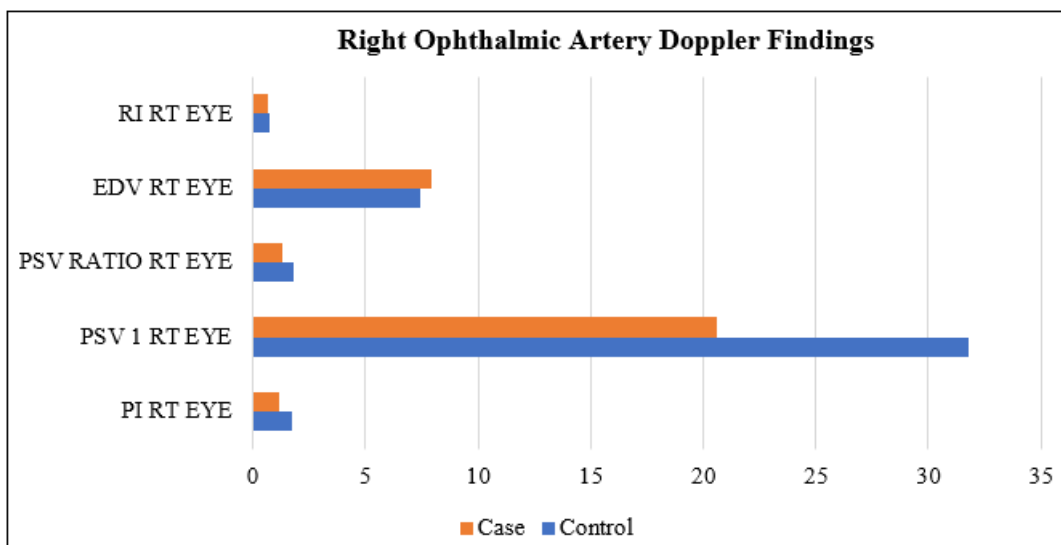
Thirty cases presented with pre - eclampsia (PE), featuring a detailed examination of 12 patients (40%) diagnosed with severe PE (MAP ≥125 mmHg) and 18 patients (60%) exhibiting mild PE (MAP <125 mmHg). The mean maternal

age was 30.9±4.2 years (range: 23–40), predominantly encompassing nulliparous women.

**Doppler Parameters:**

Our investigation meticulously analyzed various Doppler parameters, including mean peak systolic velocity, pulsatility

index, resistivity index, and peak ratio. Statistically significant differences were observed between pre - eclamptic cases and controls (p value <0.001), substantiating the potential of ophthalmic artery Doppler waveform analysis as a discriminatory tool.



**End Diastolic Velocity:**

The mean end diastolic velocity demonstrated a noteworthy elevation in pre - eclamptic cases, further establishing the association between altered hemodynamics and PE (p value 0.032).

**Predictive Power:**

Receiver Operating Characteristic (ROC) curve analysis highlighted the exceptional discriminatory ability of resistivity index and peak ratio in distinguishing between mild and severe PE, showcasing both high sensitivity and specificity.

**Modest Sensitivity and Specificity:**

A Doppler cut - off of 23.3 cm/s exhibited commendable performance, with a modest yet clinically relevant sensitivity of 78.2% (95% CI) and specificity of 83.9% (95% CI) for predicting early - onset PE.

These compelling findings not only shed light on the nuanced hemodynamic changes associated with PE but also underscore the potential of ophthalmic artery Doppler waveform analysis as a valuable clinical tool for risk stratification and early detection in pregnant individuals at risk of developing this complex hypertensive disorder.

**4. Discussion**

Our study delves into the nuanced aspects of ophthalmic artery Doppler waveform analysis in pre - eclampsia (PE), yielding findings that contribute significantly to the existing literature on this clinically relevant topic.

**Maternal Age and PE Prevalence:**

An intriguing observation was the higher mean age of mothers with PE, surpassing the majority reported in existing studies. This distinct demographic profile may partially elucidate the elevated burden of PE in our locality. This aligns with Ananth et al's study, indicating an increased incidence of

PE among women aged 30–34 in the USA. Our findings underscore the importance of considering maternal age as a potential risk factor in the context of PE prevalence.

#### Hemodynamic Implications:

The lower mean values for resistivity index (RI) and pulsatility index (PI) in the ophthalmic artery of PE patients signify diminished impedance to blood flow. This deviation surpasses the anticipated peripheral vasodilatation associated with advancing gestational age (GA) in healthy pregnancies. The novel contribution of our study lies in the identification of altered impedance indices, a phenomenon not solely attributable to physiological vasodilatory changes.

#### PSV as a Marker of Aberrant Hemodynamics:

Furthermore, our investigation revealed lower peak systolic velocity (PSV) values in the pre - eclamptic group compared to the control group. This distinctive pattern counters the expected increase in PSV values seen in normal pregnancies. Unlike the typical hemodynamic progression in healthy pregnancies, where decreased impedance indices (RI and PI) are coupled with rising PSV values, PE complicates this paradigm by correlating with a decrease in PSV values. This intriguing finding underscores the unique hemodynamic alterations within the ophthalmic artery in the context of PE.

#### Clinical Implications:

These distinctive hemodynamic patterns identified in our study have significant clinical implications. They offer valuable insights into the pathophysiology of PE, emphasizing the importance of not only examining impedance indices but also considering PSV values. Understanding these deviations contributes to refining the predictive power of ophthalmic artery Doppler waveform analysis in identifying high - risk pregnancies.

In conclusion, our study not only enhances the understanding of PE - related hemodynamic changes but also underscores the potential of ophthalmic artery Doppler analysis as a valuable tool for unraveling the intricacies of this hypertensive disorder. These insights contribute meaningfully to the existing body of knowledge and pave the way for further investigations into the clinical utility of Doppler waveform analysis in predicting and managing PE.

## 5. Conclusion

In summary, our study establishes Ophthalmic artery Doppler as an invaluable adjunctive tool for the diagnostic armamentarium in both overall and severe preeclampsia. The meticulously examined parameters, including resistivity index, peak ratio, and pulsatility index, showcase not only remarkable sensitivity but also noteworthy specificity. The robust performance of these Doppler indices positions them as reliable indicators, underscoring their potential clinical utility in identifying and characterizing preeclampsia.

The discerning capabilities of Ophthalmic artery Doppler, elucidated in this study, emphasize its role as an effective screening tool for high - risk cases. By capturing early changes in hemodynamic derangement associated with preeclampsia, this non - invasive and accessible methodology holds promise in preemptive risk stratification and timely

intervention. This strategic use of Ophthalmic artery Doppler has the potential to revolutionize clinical practices, fostering proactive management and improved outcomes in pregnant individuals at risk of preeclampsia.

As we conclude, the findings presented herein not only contribute to advancing our understanding of preeclampsia but also underscore the transformative impact that Ophthalmic artery Doppler can exert in enhancing diagnostic precision and clinical decision - making in the complex landscape of hypertensive disorders during pregnancy.

## References

- [1] Hata T, Hata K, Moritake K. Maternal ophthalmic artery Doppler velocimetry in normotensive pregnancies and pregnancies complicated by hypertensive disorders. *Am J Obstet Gynecol.*1997 Jul; 177 (1): 174 - 8. doi: 10.1016/s0002 - 9378 (97) 70458 - 7. PMID: 9240603.
- [2] Olatunji RB, Adekanmi AJ, Obajimi MO, Roberts OA, Ojo TO. Maternal ophthalmic artery Doppler velocimetry in pre - eclampsia in Southwestern Nigeria. *Int J Womens Health.*2015 Jul 20; 7: 723 - 34. doi: 10.2147/IJWH. S86314. PMID: 26229508; PMCID: PMC4514353
- [3] Nicolaidis KH, Sarno M, Wright A. Ophthalmic artery Doppler in the prediction of preeclampsia. *Am J Obstet Gynecol.*2022 Feb; 226 (2S): S1098 - S1101. doi: 10.1016/j. ajog.2020.11.039. Epub 2021 Apr 24. PMID: 34292158
- [4] Ananth CV, Keyes KM, Wapner RJ. Pre - eclampsia rates in the United States, 1980–2010: age - period - cohort analysis. *BMJ.*2013; 347: f6546.