

# Socket Shield Technique

Saket Asamwar<sup>1</sup>, Dr. Bhushan Mundada<sup>2</sup>, Dr. Rozina Vishnani<sup>3</sup>

<sup>1</sup>BDS (intern) Sharad Pawar Dental College and Hospital, Datta Meghe Institute of Medical Sciences (Deemed to be University) Sawangi Meghe, Wardha

Corresponding Author Email: [saketritzz24\[at\]gmail.com](mailto:saketritzz24[at]gmail.com)

Mobile no. - 7507075123

<sup>2</sup>BDS, MDS, Associate Professor, Department of Oral Maxillofacial Surgery, Sharad Pawar Dental College and Hospital, Datta Meghe Institute of Medical Sciences (Deemed to be University), Sawangi Meghe, Wardha

<sup>3</sup>BDS, MDS, Reader, Department of Oral Maxillofacial Surgery, Sharad Pawar Dental College and Hospital, Sawangi Meghe, Wardha

**Abstract:** *Extraction of teeth triggers a chain of proceedings that includes buccal plate bone which is not supported, reduced blood flow, resorption due to the plate's thinness. To avoid this categorization and generate a natural developing profile surrounding dental implant prostheses, a variety of therapies were tried. To do so, a novel treatment called socket preservation operations was created, in which the root was intersected and the buccal two - thirds of the root was kept in the socket, preserving the periodontium, bundle bone, and buccal bone. In addition, based on the position of the shield in the socket, categorization for the SST technique is supplied. This classification helps with a better knowledge of the preparation design. When a tooth is extracted, a fragmented root is left, particularly in the vestibular region of the root's most coronal portion. The ridge undergoes a dimensional shift after a tooth is pulled, which has been well described partial extraction treatment, root membrane method, and partial root preservation are all terms used to describe this surgery [1]. Unightly black triangles grow between teeth as a result of loss of bone, soft tissues are migrated apically. This is a tough problem for a dentist in terms of replacing the missing tooth while preserving acceptable aesthetics, particularly in the frontal area.*

**Keywords:** Socket Shield Technique, implants, bone resorption

## 1. Introduction

The development and maintenance of a balance amongst the pink & white zones, particularly in the aesthetic parts, is one of the main purposes of prosthetic restoration is to improve mobility. Vertical and horizontal loss of buccal occurs after atraumatic removal of a tooth with rapid implant implantation, destruction of scalloping interproximal bony, resulting in a difficult restoration [2]. Hürzeler et al. was the first to introduce and describe the SST [3]. To compensate for this loss, many preventive operations have been employed in the past, like post - ridge breakdown measures and ridge conservation procedures, like bone growth, soft - tissue growth, or both the procedures together [4]. The SST is a predictable procedure that requires less surgery, takes less time overall, and has the best aesthetic outcome. Because the periodontal ligament remnants are linked to the dentin and cementum of the root portion, the SST attempts to compensate for the damage of vestibular capacity by "misleading" the bundle bone [5, 6, 7].

Hermann et al. stated that two - piece implants have much more crestal bone loss than single - piece implants, resulting in a significantly higher apical gingival margin, employed a one - piece implant in his investigation. Furthermore, inflammation in the peri - implant tissues around single - piece implants is lower than inflammation in the peri - implant tissues around two - piece implants. After a five - month wait, he found that keeping the buccal section of the root while

placing quickly is a realistic technique for attaining three - dimensional implant placement, this necessitates sufficient hard and soft structure support and stability.

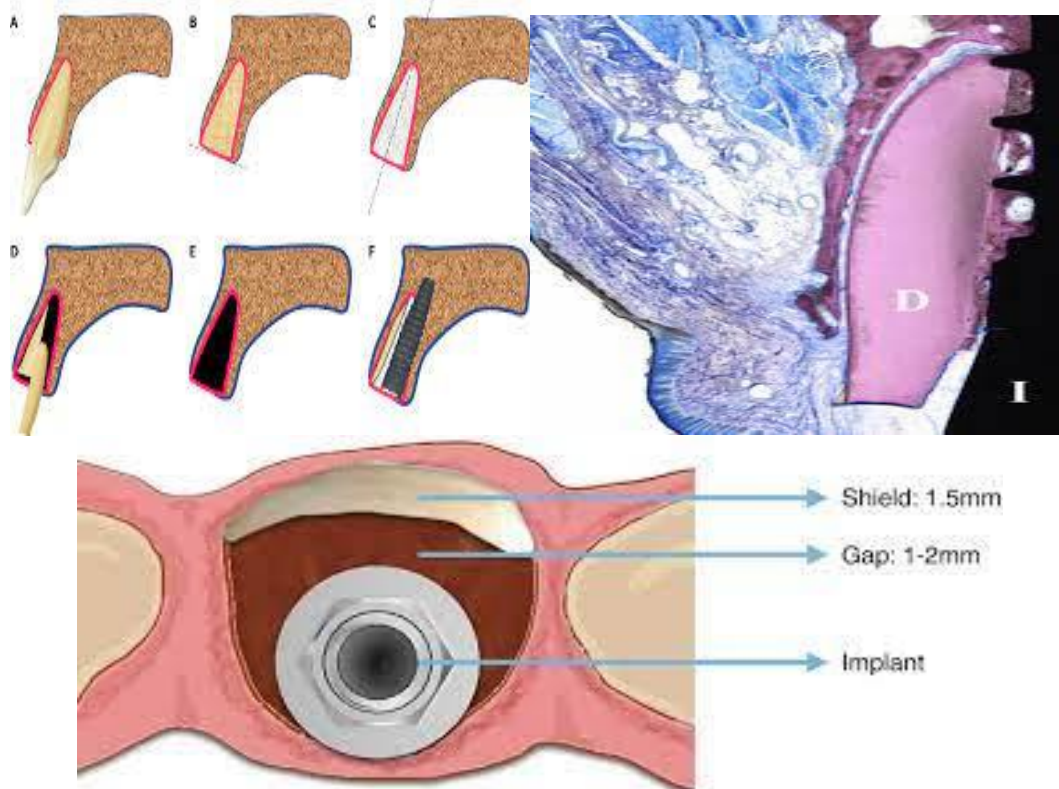
## 2. Technique

The SST steps for instant implant insertion are as follows: -

Stage 1: Dissect the crown parallel at the gingival approximation; cut the crown parallel at the gingival equal in the second step.

Step 2: Bisect the root vertically, removing both the palatal half and the apex. The shield should be two - thirds of the root's extent. This stage takes a lot of practice, endurance, and perseverance. The buccal section of the shield is then cut to a width of 1.5–2 mm. The shield should be shaved to the equal to the bone. The inside side of the shield has a bevel or S - shaped design to fit the restorative components.

Step 3: The implant is positioned correctly in three dimensions (3D). A space of 1.5 mm or more between the shield and the implant is desirable. If the gap is more than 3 mm, a bone graft is recommended. To protect the soft - tissue contours, a temporary crown or a tailored therapeutic abutment will be placed soon after the implant is placed. The final restoration might be either a screw - retained crown or a cement - retained crown with a restorative margin that can be easily reached for cement clean - up.



### Classification

**Type I:** A solitary edentulous site with both mesial and distal teeth is a pointer. Buccal safeguard (the safeguard sits solely in the buccal portion of the attachment, between proximal line points of the tooth).

**Type II:** Buccal shield (full C)

- 1) An implant already exists on either side of the planned location.
- 2) Tooth loss on both sides of the mouth that cannot be replaced with an implant.
- 3) One side of the mouth has an implant, while the other has a missing tooth.

**Type III:** Buccal half - shield When one side has a tooth and the other has an implant or a missing tooth, this is an indication.

**Type IV:** Interproximal shield is a term used to describe a barrier between two points that are separated by a distance. This treatment is done when buccal bone loss necessitates grafting when there is a lost tooth or implant on the other side.

**Type V:** The palatal shield is advised for Maxillary molars.

**Type VI:** Multiple buccal shields, this is an indication if there are two or more shields in the socket. When there is a vertical root fracture, it is used. Between the shattered roots, there are signs of bone formation, which may help to keep the two fragments together. The following classification is a theory that must be supported by clinical research to verify the safety of such modifications to the original technique, as well as the assurances that the papilla and bone height will be preserved.

### Benefits and Limitations

By preserving a section of the root, this minimally invasive surgical method aids in the preservation of hard and soft tissue types. It does away with the necessity for soft and hard tissue grafting, resulting in a faster recovery time. The interdental papilla can be retained even when surrounding implants are present by creating an interdental socket shield. It helps to keep the pink and white aesthetics alive. For patients with a high lip line or a maxillary anterior, this is also an intriguing alternative. This method not only saves the hard and soft tissues but also helps to maintain them.

### 3. Discussion

To avoid tissue changes & reduce the influence of tooth removal on the resorption process, various root retention hypotheses have been developed and clinically tested. The Root Submerge Technique (RST) was demonstrated by Salama and colleagues to protect the natural periodontium and prevent bone resorption. The attachment safeguard strategy was presented in 2010 by Hürzeler et al. for the third and fourth mandibular premolars of beagle canines. He utilized a coarse - grained precious stone blemish to decoronate the distal finish of the premolar and protected a halfway root piece encompassing a promptly embedded embed to limit tissue changes after tooth extraction. The clinical case showed great buccal tissue protection and clinically fruitful osseointegration following four months.

A histological examination revealed that the root fragment had not resorbed and that new cementum had developed on the implant surface.

Assuming the embed is put in contact with this regular tooth part, he found that leaving the coronal buccal root piece unblemished assists with guaranteeing the physiological

support of labial and buccal bone parts. These procedures, however, come with some dangers, including the establishment of a preimplant periodontal film and the risk of pre-implant infection. These emerge when the held tooth part is impacted by a prior or creating periodontal or endodontic contamination or aggravation. Filippi et al. presented that de-coronation of a tooth that is ankylosed, protected by the alveolar bone before implant insertion by maintaining the root of living or non-vital teeth to prevent tissue & the effects of tooth extraction [8].

Malmgren and his colleagues Keeping the roots in the alveolar process which is decoronated protects remaining bone volume while also allowing for upright bone growth observable coronally to the decoronated root, according to Malmgren and his colleagues Andersson, et al. conducted study that revealed the possibility of regeneration! Six times, Bjorn imaged the alveolar bone around endodontically treated teeth [9, 10, 11, 12]. In their research, O'Neal et al. the coronal surface of submerged roots develops new cementum and blood vessels, isolating the dentine from the developing bone [13]. De-crowned root fragments are left, Von Arx et al. established a way for retaining the ridge [14]. During a two-year follow-up period, Davarpanah & Szmukler published a case study of 5 people, indicating that implants positioned quickly with the implant contact directly with tooth which is ankylosed tooth pieces were retained with no evidence of any pathological problems [15].

According to Al-Dary H.'s case report, the root was hemisected in a mesiodistal direction with a fissure bur, the lingual (without trauma) component of the root was removed, followed by a surgical bur reduction of the buccal piece, leaving a small layer of the root aspect of the bone intact on the buccal plate [16].

Because Hermann et al. discovered that two-piece implants have much more crestal bone loss than single-piece implants, resulting in a significantly higher apical gingival margin, the author employed a one-piece implant in this investigation. Furthermore, inflammation in the peri-implant tissues surrounding single-piece implants is lower than inflammation in the peri-implant tissues around two-piece implants. After a five-month delay, he determined that preserving the buccal section of the root while implanting fast is a viable method for achieving three-dimensional implant placement, which necessitates sufficient support and firmness of the neighboring hard and soft components. A bone trephine was utilized to remove the residual root in another case report by the same author, leaving a rounded piece of the palatal/lingual extraction site with a semilunar inner form of the buccal aspect root that would receive an implant. He concluded that a trephine would be far preferable to a pressure bur in terms of shield preparation.

#### 4. Case Report

This procedure was employed for a failing upper right second premolar in an event report by Chen & Pan and clinical examination after four months revealed strong peri-implant soft tissue and a well-preserved ridge [17]. On the buccal lateral, there remained 0.72mm of horizontal resorption. Abadzhiev M, et al. conducted a human comparative analysis

[18]. Radiographs taken immediately after implantation and every six months for the next two years, according to the author, show the considerable bone loss in routine implantation. Up to 12%, or up to 5mm, can be expected in the first two years. Bone loss in the socket-shield operation is 2%, or 0.8mm, over the two-year follow-up period.

Soft tissue volume is calculated using the amount of linked gingiva. The socket-shield approach earned 18% of the vote, whereas the socket-shield technique only received 2%. The absence of soft tissue support caused by high bone resorption is a requirement for mucogingival surgery to improve the associated soft tissue volume. The aesthetic evaluation found that socket shield treated teeth appeared more natural than teeth that had not been treated. In a pilot investigation with beagle dogs before immediate implant insertion, the efficacy of splitting the remaining buccal root segment into two halves was tested histologically, clinically, and volumetrically. The tissues were tested for histological identification four months later, with the following results: a. There were no negative effects or symptoms of inflammation in any of the experimental regions. b. An apical tooth fragment in touch with implant threads but still involved in the buccal bone plate via periodontal ligaments. c. There was no osteoclastic remodeling on the buccal alveolar crest. d. The cemento-enamel junction displayed junctional epithelium at a higher magnification. Although the exact degree of marginal bone loss in the SST has yet to be identified, current clinical experiences suggest that bone loss during extraction is minimal, negligible, or possibly non-existent. As a result, soft tissue grafting is not necessary for the vast majority of patients treated with this method. The scientists discovered a substantial difference in visual impact when comparing the socket shield to the standard approach in a case-control study published in 2014. Without a doubt, if horizontal bone loss is not corrected for cosmetic reasons, the treatment turns out to be more understanding cordial, with less length and grimness.

Nonetheless, the socket shield technique is a method that necessitates extra care from the operator, is delicate to do, and can be challenging at times. Uneven healing has been recorded in sockets with root pieces.

To forestall inordinate resorption of the leftover edge, both essential teeth, it has been proposed that endodontically treated roots be maintained and submerged. One of the most important aspects of the socket shield technique's success is that the root fragment does not come into contact with anything that could aid infection. Continue with the conventional instantaneous implant placement method if the shield moves during the implant insertion [19].

Socket healing using root pieces has been thoroughly demonstrated. Both fundamental tooth maintenance and submergence of endodontically treated roots have been educated to restrict extreme resorption concerning the lingering edge. The fact that the root fragment does not come into contact with anything that could aid infection is one of the most crucial components of the SST's success [20]. If the shield moves during implant placement, follow the standard immediate implant insertion approach.



## 5. Conclusion

Before the treatment may be widely recommended, practitioners must contribute to the implant's long-term achievement in the aesthetics zone by expanding their knowledge base. Although the technique is cost-effective, it is still technique-dependent, and it necessitates a specific case selection to get the desired outcomes. A minimum of 1 mm of cortical bone was shown to be required for enhancing success rates in the maxilla and mandible when cortical width was measured. Furthermore, while performing quick implant placement, competent surgical therapy, restorative procedures, and clinical experience are required. SST is becoming increasingly popular among therapists throughout the world. In circumstances where implants are inserted shortly after extraction, the approach has a lot of potential for preserving hard and soft tissues. Thanks to the proposed classification, clinicians will be able to obtain the shield based on the clinical situation and produce the best potential cosmetic results, particularly in urgent implant instances.

## References

- [1] Gluckman H, Du Toit J, Salama M. The pontic shield: Partial extraction therapy for ridge preservation and pontic site development. *Int J Periodontics Restorative Dent.* 2016; 36: 417–23.
- [2] Kumar PR, Kher U. Shield the socket: Procedure, case report, and classification. *J Indian Soc Periodontol*; 22: 266 - 72.
- [3] Salama H, Salama MA, Garber D, Adar P Practitioner Periodontics Aesthetic Dent. 1998 NovDec; 10 (9): 1131 - 41; quiz 1142.
- [4] M. B. Hürzeler, O. Zuhr, P. Schupbach, S. F. Rebele, N. Emmanouilidis, and S. Fickl, "The socket - shield technique: a proof - of - principle report," *Journal of Clinical Periodontology*, vol.37, no.9, pp.855–862, 2010.
- [5] Bäumer D, Zuhr O, Rebele S, Schneider D, Schupbach P, Hürzeler M *Clin Implant Dent Related Res.* 2015 Feb; 17 (1): 71 - 82.
- [6] M. G. Araújo and J. Lindhe, "Dimensional ridge alterations following tooth extraction. An experimental study in the dog," *Journal of Clinical Periodontology*, vol.32, no.2, pp.212–218, 2005.
- [7] S. T. Chen and D. Buser, "Esthetic outcomes following immediate and early implant placement in the anterior maxilla—a systematic review," *The International Journal of Oral & Maxillofacial Implants*, vol.29, pp.186–215, 2014.
- [8] Filippi A, Pohl Y, von Arx T (2001) Decoration of an ankylosed tooth for the preservation of alveolar bone prior to implant placement. *Dent Traumatol* 17 (2): 93 - 95.
- [9] Malmgren B, Cvek M, Lundberg M, Frykholm A (1984) Surgical treatment of ankylosed and infrapositioned reimplanted incisors in adolescents. *Scand J Dent Res* 92 (5): 391 - 399.
- [10] Malmgren O, Malmgren B, Goldson L (1994) Orthodontic management of the traumatized dentition. In: Andreasen JO & Andreasen FM (Eds.), *Textbook and Color Atlas of Traumatic Injuries to the Teeth*. Munksgaard, Copenhagen pp: 587 - 633.
- [11] Andersson L, Emami - Kristiansen Z, Högström J (2003) Single - tooth implant treatment in the anterior region of the maxilla for treatment of tooth loss after trauma: a retrospective clinical and interview study. *Dent Traumatol* 19 (3): 126 - 131.
- [12] Bjorn H (1963) Free transplantation of gingiva propria. *Sven Tandlak Tidskr* 22: 684.
- [13] O'Neal RB, Gound T, Levin MP, del Rio CE (1978) Submergence of roots for alveolar bone preservation. I Endodontically treated roots. *Oral Surg Oral Med Oral Pathol* 45 (5): 803 - 810.
- [14] Von Arx T, Brägger U, Scheuber S, Bosshardt D (2013) Implantattherapie nach Frontzahntrauma. *Schweiz Monatsschr Zahnmed* 123 (5): 417 - 427.
- [15] Davarpanah M, Szmukler - Moncler S (2009) Unconventional implant treatment: Implant placement in contact with ankylosed root fragments, A series of five cases. *Clin Oral Implant Res* 20 (8): 851 - 856.
- [16] Al Dary H (2013) The Socket Shield Technique: A Case Report. *Smile Dental Journal* 8 (1): 32 - 36.
- [17] Chen CL, Pan YH (2013) Socket Shield Technique for Ridge Preservation: A Case Report. *J Prosthodont Implantology* 2 (2): 16 - 21.
- [18] Abadzhiev M, Nenkov P, Velcheva P (2014) Conventional Immediate Implant Placement and Immediate Placement with Socket - Shield Technique – Which is Better. *International Journal of Clinical Medicine Research* 1 (5): 176 - 180.
- [19] Dubey, A., Dangorekhasbage, S., Bhowate, R., 2019. Assessment of Maxillo - Mandibular Implant Sites by Digitized Volumetric Tomography. *JOURNAL OF EVOLUTION OF MEDICAL AND DENTAL SCIENCES - JEMDS* 8, 3780–3784. <https://doi.org/10.14260/jemds/2019/819>
- [20] Ghudale, G., Ambad, R. S., Bankar, N., 2021. Effects of Relationship between Gestational Diabetes Mellitus and Children's Obesity. *JOURNAL OF PHARMACEUTICAL RESEARCH INTERNATIONAL* 33, 53–58. <https://doi.org/10.9734/JPRI/2021/v33i39B32179>