

# Case Report of Unusual Polyembolokoilamania: A Bottle Gourd

Dr Shivalika Sharma MS<sup>1</sup>, Dr Middela Muni Siva Teja<sup>2</sup>, Dr Ratna Chopra MS<sup>3</sup>,  
Dr Ankit Garg MS<sup>4</sup>, Dr. Nampally Gattu Swamy<sup>5</sup>

<sup>1</sup>General Surgery, Senior Resident, Hindu Rao Hospital & NDMC Medical College, New Delhi.

<sup>2</sup>DNB General Surgery Resident, Hindu Rao Hospital & NDMC Medical College, New Delhi.

<sup>3</sup>HOD, Department of General Surgery, Hindu Rao Hospital & NDMC Medical College, New Delhi.

<sup>4</sup>General Surgery, Assistant professor, Department of General Surgery, Hindu Rao Hospital & NDMC Medical College, New Delhi.

<sup>5</sup>DNB General Surgery Resident, Hindu Rao Hospital & NDMC Medical College, New Delhi.

**Abstract:** *Rectal foreign bodies represent a challenging and unique field of colorectal trauma. Approach to such patients encompassed medico legal, psycho social domains. A high index of suspicion of perforation must be kept in mind and looked for in imaging. Retrieval of foreign body may be spontaneous, trans anal extraction, endoscopic extraction or by laparotomy. Trans anal retrieval of a large gourd makes our case unique in terms of nature of foreign body and technique of retrieval.*

**Keywords:** rectal foreign body, psycho - social aspects, imaging for perforation, trans anal retrieval, recto - anal inhibitory reflex, colorectal trauma, Abdominal X - ray.

## 1. Case Report

A 26 years gentleman presented to surgical emergency with complaints of pain abdomen, urinary retention. 800ml of clear urine was drained after foley's catheterization. After bladder was emptied, an elongated lump was still palpable in hypogastric region. lower margin could not be reached, hard in consistency, well defined margins, smooth surface and immobile, size equivalent to 16 weeks [10 cm above pubic symphysis]. Rest of the abdomen was unremarkable.

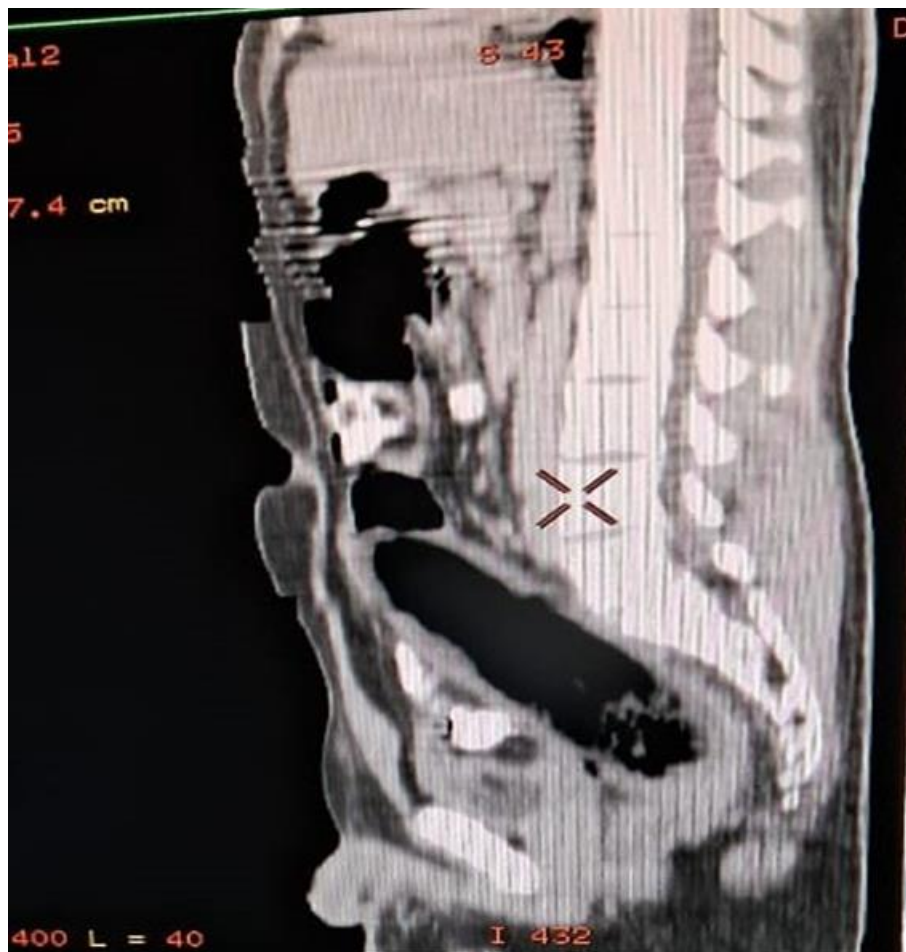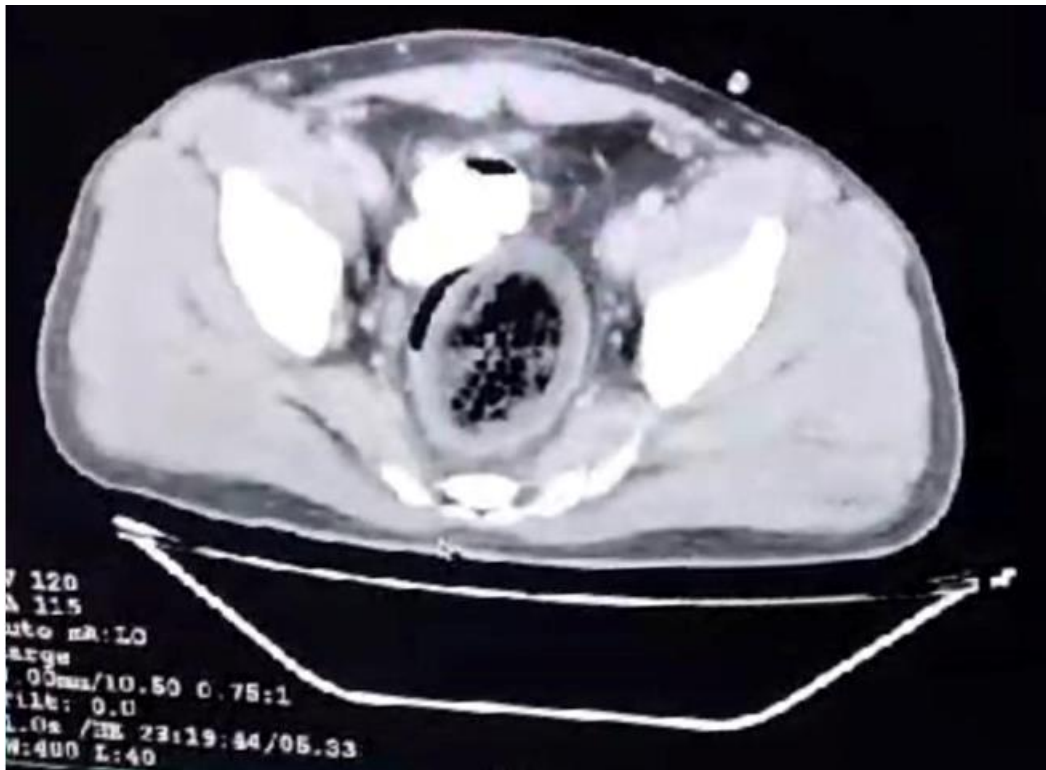
Digital rectal examination revealed a patulous anal verge allowing insertion of 3 fingers without anaesthesia. A palpable foreign body with attached stem, bimanually palpable on digital per rectal and abdominal palpation, continuous with the palpable lump. It was free on all sides

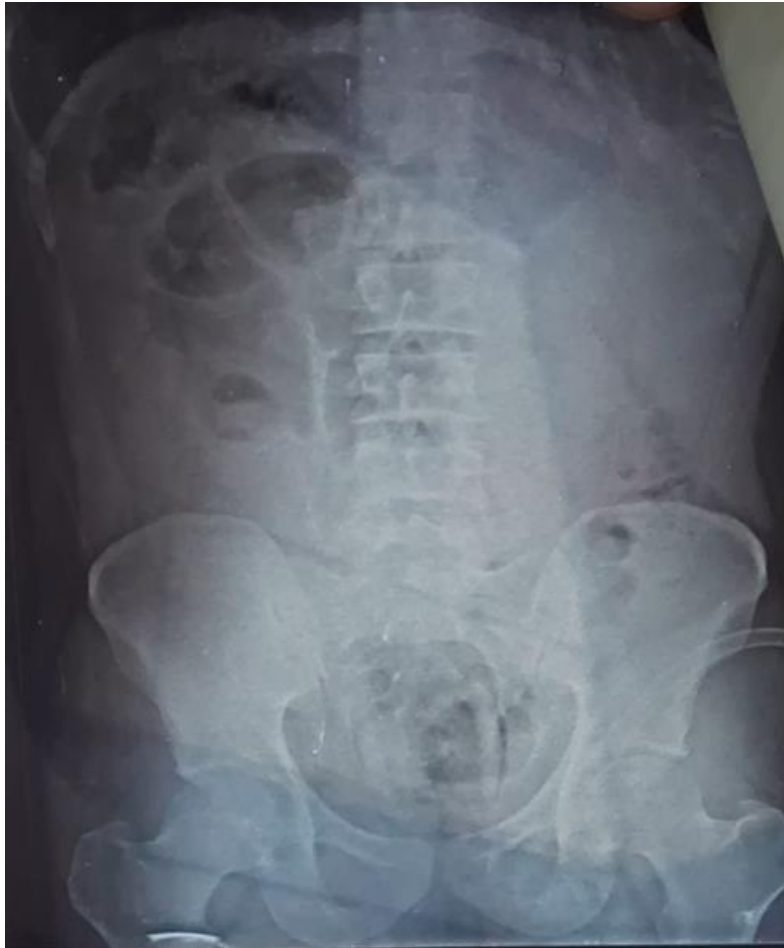from bowel mucosa was palpable 10cm from anal verge. Finger stall revealed vegetable seeds.

A provisional diagnosis of per rectal foreign body was made (probably an elongated vegetable with stem)

X ray pelvis revealed a soft tissue shadow with a relatively radiolucent center in pelvic area.

CECT Whole abdomen with oral and i/v contrast was done and revealed a diffuse long segment circumferential wall thickening measuring approximately 8 - 9 mm in thickness & extending for a length of 175 - 180 mm is noted involving the sigmoid, rectum and anal canal, few linear air foci are seen along the walls of involved segment and mild adjacent fat stranding is noted.





Under spinal anaesthesia and lithotomy position, trial of Trans anal extraction of foreign body was made. Stem of Foreign body was held with Babcocks and by giving pressure from per abdomen, foreign body was extracted gently by rotating hand movements.

Foreign body extracted Bottle gourd 16 cm length & 6 cm in diameter.

Post foreign body removal, patient was able to pass flatus and stools. No anal incontinence noted.

Post operative DRE –

- External hemorrhoids at 3 and 7 o clock position.
- Recto Anal Inhibitory Reflex corrected.
- Anal tone normal.

Post operative period was uneventful.

- Post op X ray did not reveal any soft tissue shadow.
- Subsequent to foreign body extraction, on direct questioning patient revealed history of abnormal indulgence with foreign bodies trans anally under the affect of deep alcohol.
- Counselling sessions were organized for the patient.

## 2. Discussion

Anorectal foreign objects are rare cases in emergency services. The first described report on the management of retained rectal foreign bodies dates back to the 16<sup>th</sup> century. They mostly appear to involve 30–40 - years - old patients,

with two - thirds being males. The management of this intriguing problem has evolved with the edition of laparoscopic, endoscopic and minimally invasive surgical options.

Anorectal foreign objects are generally things made from plastic, aluminium or glass bottles, eggplant, carrot or wood of different sizes. The common complaints with which the patients present include rectal or abdominal pain, constipation or obstruction or even incontinence. Usually the patients does not offer concern to an inserted rectal foreign body as chief complaint. A thorough history will often provide the diagnosis; however concern for the possibility of assault or nonvoluntary placement of object should remain high.

Evaluation should include a thorough clinical examination to look for any signs of peritonitis such as tachycardia, fever and hypotension, per abdominal findings such as guarding/rigidity, absence of bowel sounds and abdominal radiography, if shows gas under right dome of diaphragm indicates perforation for which urgent laparotomy is required or to locate the foreign object relative to the pelvic floor. A careful digital rectal examination is the most informative component of the evaluation process as it indicates the proximity of the object to pelvic floor, true nature of the object and functional states of the sphincter complex also can be made out. If not palpable on per rectal examination, rigid or flexible proctosigmoidoscopes can be used.

**Extraction techniques**

If signs of peritonitis are present then no per rectal extraction should be attempted.

Transanal Extraction

Endoscopic Extraction

Operative Extraction

**Transanal Extraction**

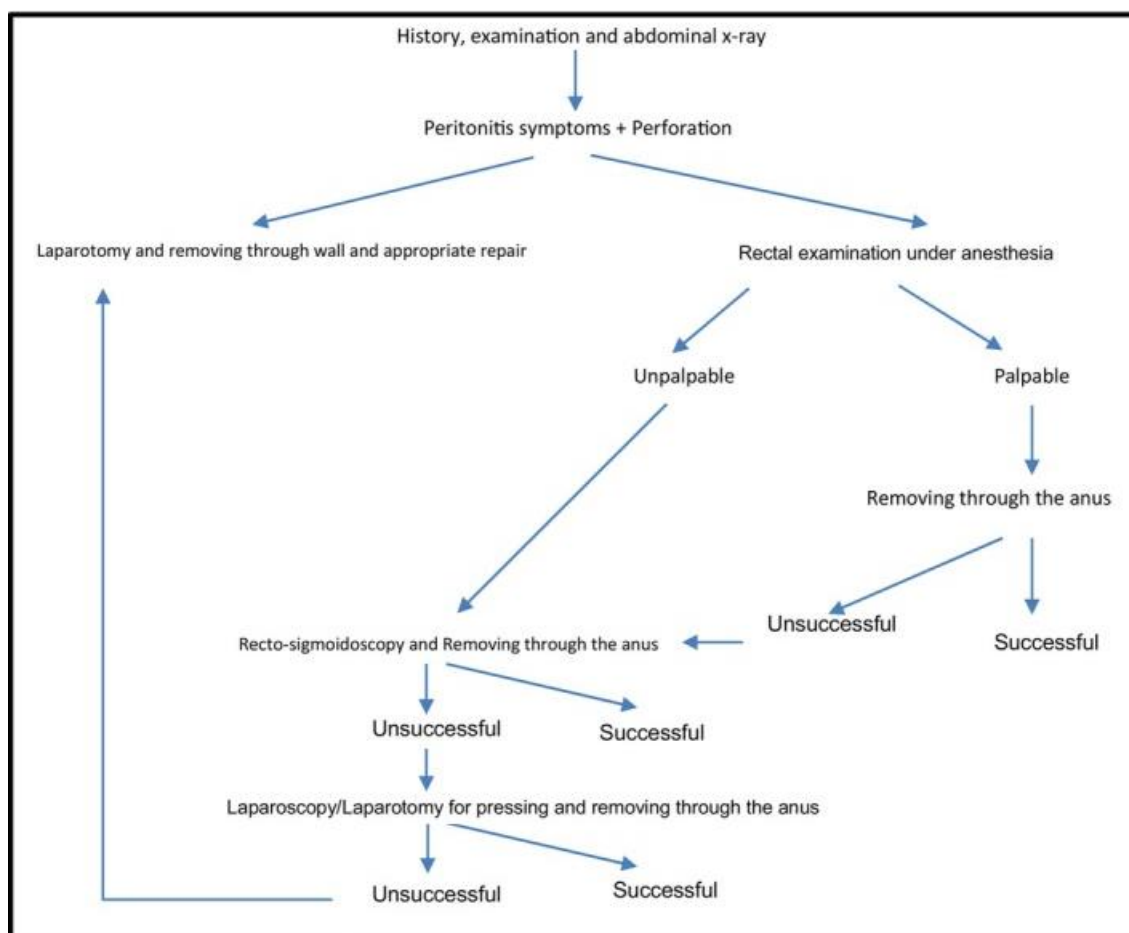
This attempt should be performed with local anesthesia, perianal block can be given if the object is not readily extractable and can be supplemented with the use of conscious sedation using fentanyl, versed, propofol, or ketamine. This aids in full relaxation of the patient's abdominal wall musculature and anal sphincter muscles, which is important for successful extraction. Patients should be positioned in the lithotomy position with reverse Trendelenburg angulation then suprapubic or sigmoid pressure applied by an assistant helps move an object caudally and prevents cephalad migration. Alternatively, the patient can be asked to perform a Valsalva maneuver and sufficient lubrication should be used to allow transanal extraction.

**Endoscopic Extraction**

If the object is not within reach for removal by hand or with the tools noted above, rigid or flexible sigmoidoscopy should be performed to visualize and attempt extraction.

**Operative Extraction**

If the above techniques are not successful, the patient requires general anesthesia. An exam under anesthesia should be the first procedure attempted, as paralysis and the use of a general anesthetic may allow transanal extraction with complete relaxation or a lower midline mini laparotomy may be used to directly squeeze the rectum and allow transanal removal. Finally, if none of these techniques work, a colotomy with transabdominal removal may be required. If gross contamination or spillage is present, a Hartmann procedure may be the prudent procedure. However, if tissue quality is good, a primary repair or short segment resection may be performed.



**Management Algorithm of per rectal foreign body [2]**

**Post extraction Care**

After the removal of an object, one must be concerned that the trauma from insertion or extraction caused rectal injury. The main purpose of follow - up examination or observation is to detect any perforation. If there is any question, a computed tomography scan with rectal contrast or rectal enema with water - soluble contrast can detect this potentially life - threatening complication. After diagnosis, stable

patients may be managed with antibiotics. Patients with signs of toxicity including fever, hypotension, or severe pain should be managed by surgical exploration.

**3. Summary**

Rectal foreign bodies represent a challenging and unique field of colorectal trauma. The important factors in dealing with these patients is fourfold: careful history and physical examination with respect for what is often an embarrassing

problem, a high index of suspicion for any evidence of toxicity that suggests perforation (and requires emergent laparotomy), a creative approach to nonoperative removal using tools originally designed for other uses, and appropriate short - term follow - up to detect any delayed perforation.

## References

- [1] Nepal A, Maharjan S, Chalise A, Rajbhandari AP. Rectal Foreign Body: A Case Report. *JNMA J Nepal Med Assoc.*2022 Dec 1; 60 (256): 1049 - 1051. doi: 10.31729/jnma.7905. PMID: 36705106; PMCID: PMC9795131.
- [2] Maddah G, Abdollahi A, Tavassoli A, Mashhadi MTR, Mehri A, Etezadpour M. An uncommon problem: Overcoming the challenges of rectal foreign bodies - A case series and literature review. *Clin Case Rep.*2023 Dec 11; 11 (12): e8313. doi: 10.1002/ccr3.8313. PMID: 38089487; PMCID: PMC10714057.
- [3] Rosser, Curtice. "COLONIC FOREIGN BODIES. " *JAMA* 93 (1929): 368 - 369.
- [4] Wagner, J. "Foreign bodies in rectum. " *American Journal of Surgery* 36 (1937): 266 - 269.
- [5] Zeren S, Bayhan Z, Algin MC, Mestan M, Arslan U. Foreign bodies in the rectum: 2 Case reports. *North Clin Istanb.*2017 May 10; 4 (1): 93 - 96. doi: 10.14744/nci.2015.30592. PMID: 28752152; PMCID: PMC5530167.