

# Twin-To-Twin Transfusion Syndrome

Niky Mathew

Associate Professor, OBG Department, Cauvery College of Nursing, Mysore, India

**Abstract:** *The twin-to-twin transfusion syndrome (TTS) results from an unbalanced blood supply through placental anastomoses in monochorionic twins. It induces growth restriction, renal tubular dysgenesis, and oliguria in the donor and visceromegaly and polyuria in the recipient. A better understanding of its pathophysiology could contribute to improving the management of TTS, which still carries a high perinatal mortality in both twins.*

**Keywords:** Monochorionic twins, Oliguria, Polyuria, Visceromegaly

## 1. Introduction

The twin-to-twin transfusion syndrome (TTS) is a severe complication occurring in 5% of monochorionic twin pregnancies. This condition is thought to result from an unbalanced fetal blood supply through the placental vascular shunts, with the larger twin being the recipient and the smaller twin the donor.

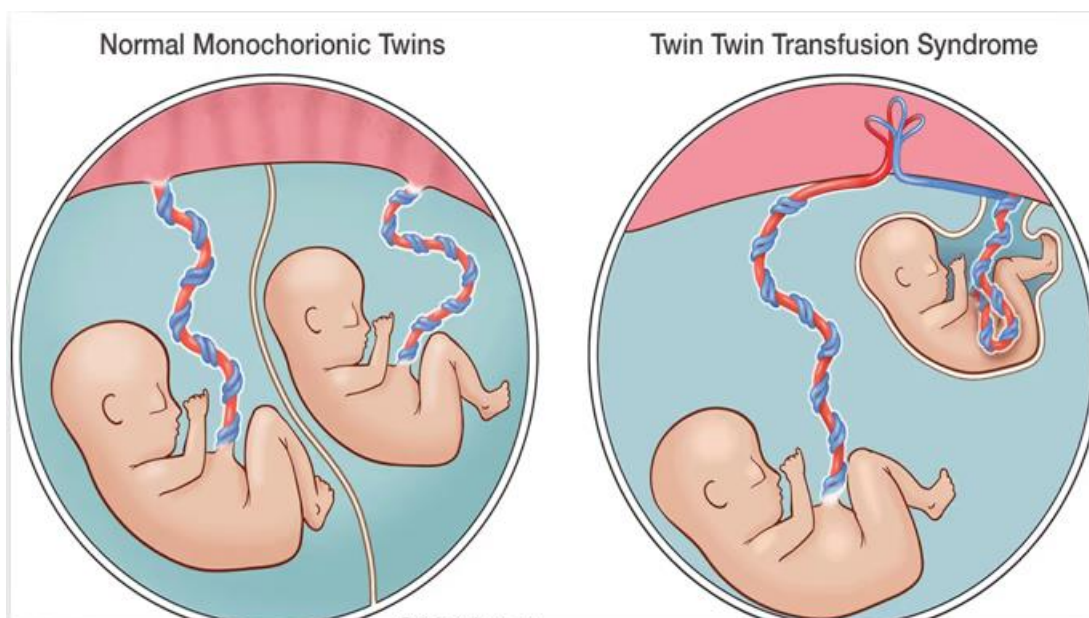
At an early stage, the disease is characterized by polyuria and polyhydramnios in the recipient fetus, whereas there is oliguria and, therefore, oligohydramnios in the donor. Major polyhydramnios may cause extreme premature labor. Severe oligohydramnios results in the stuck twin phenomenon, a condition in which the donor appears tightly wrapped in his amniotic sac.

In the most severe cases, the recipient may die from cardiac failure and the smaller twin from anemia and hypoxia, or both

twins may die as a result of premature labor. In either twin, severe ischemic brain damage may result from acute hemodynamic changes.

Twin-to-twin transfusion syndrome (TTTS) is a rare pregnancy condition affecting identical twins or other multiples. TTTS occurs in pregnancies where twins share one placenta (afterbirth) and a network of blood vessels that supply oxygen and nutrients essential for development in the womb. These pregnancies are known as monochorionic.

Sometimes the vessel connections within the placenta are not evenly dispensed and there is an imbalance in the blood exchange between the twins. One twin — the donor twin — gives away more blood than it receives in return and runs the risk of malnourishment and organ failure. The recipient twin receives too much blood and is susceptible to overwork of the heart and other cardiac complications.



## Difference between Normal Monochorionic Twins and TTTS

### The Donor Twin

The donor twin experiences progressive loss of blood volume (hypovolemia). Therefore, its kidneys don't have to filter as much fluid from the blood, and as a result, urination

decreases. This affects development of the bladder and leads to low levels of amniotic fluid.

Amniotic fluid, which consists of fetal urine, provides a cushion in the womb. In addition, as a fetus grows, it swallows this fluid. This aids in the development of its respiratory, urinary and gastrointestinal systems. An

Volume 13 Issue 7, July 2024

Fully Refereed | Open Access | Double Blind Peer Reviewed Journal

[www.ijsr.net](http://www.ijsr.net)

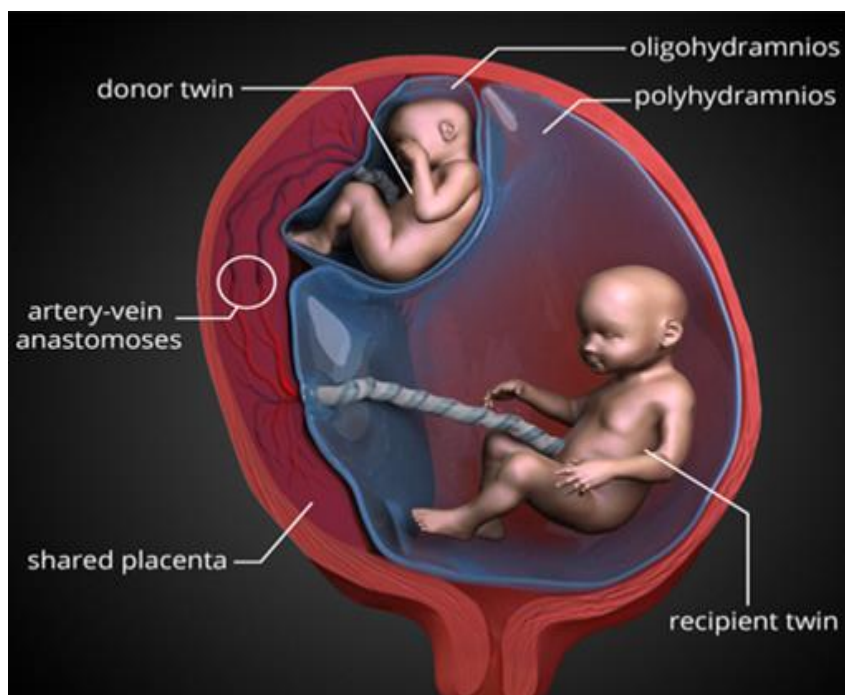
abnormal reduction in amniotic fluid is known as oligohydramnios. If amniotic fluid ceases to exist this is known as anhydramnios. If the blood volume in the donor twin's circulatory system is not effectively reaching the body, cardiovascular dysfunction can occur. This places the donor at risk for death.

### The Recipient Twin

The recipient twin is at risk for successively increasing blood volume (hypervolemia). Hypervolemia leads to increased urination, more frequent bladder filling and the production of

larger amounts of urine every time the bladder is emptied. This results in polyhydramnios an abnormal increase in amniotic fluid.

A persistent state of hypervolemia ultimately affects the function of the heart muscle in the recipient, which is working hard to pump the increased amount of blood. Hypervolemia can exceed the capacity of the cardiovascular system (the heart and circulatory system of blood vessels) and can then lead to cardiovascular dysfunction and even heart failure and death.



### Donor Twin and Recipient Twin

#### Risk Factors of Twin-to-Twin Transfusion Syndrome

Being pregnant with identical twins or multiples puts a woman at risk for having a pregnancy complicated by TTTS. However, TTTS is an indiscriminate condition, occurring at random in monochorionic pregnancies.

#### Twin-to-Twin Transfusion Syndrome Diagnosis

A doctor may suspect twin-to-twin transfusion syndrome based on the results of a routine prenatal ultrasound. A maternal-fetal medicine specialist can confirm the diagnosis by conducting more detailed testing to measure amniotic fluid volume, bladder filling and blood flow in the recipient and donor twins.

When there is a rapid increase of amniotic fluid volume, the uterine cavity also expands at an accelerated pace, placing the mother at risk for preterm labor and shortening of the cervix. This may lead to preterm labor or preterm rupture of membranes followed by delivery. For this reason, maternal assessment of the cervical length and uterine activity is essential in all women presenting with suspected TTTS.

An important factor in determining the prognosis of TTTS is the state of cardiovascular dysfunction in the twins. This is why a diagnosis of TTTS will include a detailed examination

of the fetal heart (fetal echocardiography) in both the recipient and donor.

#### Management and Treatment

Because Twin-to-Twin Transfusion Syndrome (TTTS) is a progressive disorder, early treatment may prevent complications, including preterm labor and premature rupture of membranes due to excessive fluid (polyhydramnios). Treatment for TTTS depends on the severity of the condition and the current stage of pregnancy.

##### 1) Fetoscopic Laser Intervention

- The fetal laser procedure is performed by introducing a thin fiber-optic scope through the mother's abdominal wall, through the wall of the uterus and into the amniotic cavity of the recipient twin.
- By examining the blood vessels on the placental surface directly, the abnormal vascular connections between the twins can be found and eliminated by directing a laser beam at them.
- Only those vessels that go from one twin to the other are coagulated by the laser beam. The normal blood vessels that help nourish each twin are left intact.

##### 2) Amnioreduction

- In a small percentage of pregnancies that develop TTTS, an artery to artery (A-A) connection between the twins

on the surface of the placenta can be found using ultrasound.

- The twin-pairs in whom these connections are demonstrated by ultrasound, have been shown to have better outcomes overall, and in our experience, over 80% survival of both twins after being treated with amnioreduction.
- Thus, although laser is the appropriate therapy for the vast majority of patients with TTTS, we occasionally offer amnioreduction to patients with TTTS who meet criteria for this therapy.

### 3) Umbilical Artery Blood Flow

- Blood in the umbilical artery (UA) normally flows away from the foetus and toward the placenta, in an attempt to obtain fresh oxygen and nutrients from the mother's circulation.
- If a placental condition worsens, it becomes harder for the blood to flow toward and within the placenta.
- With each heartbeat, the foetus pushes blood toward the placenta (the systole phase) through the umbilical artery, and normally, that beat is strong enough for blood to keep flowing forward, toward the placenta, even as the heart re-fills for its next beat (the diastole phase).
- In some cases, as TTTS progresses, forward flow in the umbilical artery of the donor may diminish between heartbeats. If the condition worsens, there may be no flow or even reversal of flow direction during the re-filling (diastole phase) of the foetal heart.
- All of the echocardiogram and ultrasound exam findings are considered in determining the severity of TTTS for each individual pregnancy.

## 2. Conclusion

This review article is to bring out awareness to women suffering from TTTS and also reveals that there is management of such syndrome and they can get healthy babies with limited complication.