

An Individualised Approach on an Endometrial Polyp with Homoeopathic Medicine: A Case Study

Dr. Antony Joy Selin¹, Dr. K. Manikanda Perumal²

¹ PG Scholar, MD Part II, Department of Materia Medica, White Memorial Homoeo Medical College, Attoor, Kanyakumari, Tamilnadu, India

Email: [joyselinantony23\[at\]gmail.com](mailto:joyselinantony23[at]gmail.com)

² Guide, Professor and HOD, Department of Materia Medica, White Memorial Homoeo Medical College, Attoor, Kanyakumari, Tamilnadu, India

Email: [dr.perumal007\[at\]gmail.com](mailto:dr.perumal007[at]gmail.com)

Abstract: *An endometrial polyp is a growth or mass that forms within the lining of the uterus (endometrium). These polyps are usually non - cancerous and vary in size, often appearing as small, finger - like projections or larger, round shapes. They are thought to develop due to hormonal changes, inflammation, or an abnormal response to oestrogen. While endometrial polyps can be diagnosed across all age groups, their highest frequency tends to occur between the ages of 45 to 55. In this journal, the case of 55 years old women suffering from bleeding and lower abdomen pain after menopause, diagnosed with Endometrial polyp and thickened endometrium. Following a five - months course of individualised Homoeopathic treatment, the patient experienced a complete recovery. Notably, the symptoms of bleeding and abdominal pain were alleviated, and subsequent examinations revealed a normal uterus devoid of endometrial polyps, along with a healthy endometrial lining. [1]*

Keywords: Endometrial polyp, thickened endometrium, Homoeopathy, Endometrium

1. Introduction

Endometrial polyps are abnormal growths that develop in the lining of the uterus (endometrium). They are typically benign and are composed of overgrowths of endometrial glands and stroma. These polyps can vary in size, ranging from very small, a few millimeters in diameter to larger ones that can be several centimeters wide.

Endometrial polyps manifest as either solitary growths or multiple growths within the uterine cavity, occasionally protruding into it [2]. Although typically non - cancerous, they may induce symptoms like irregular menstrual bleeding, heavy intermenstrual bleeding, and in some cases, infertility or challenges with conception.

2. Etiology

Endometrial polyps are excessive growths of endometrial glands and stroma that extend beyond the endometrium. While the exact cause of these polyps remains unclear, they are linked to endometrial hyperplasia. Consequently, unbalanced estrogen levels are deemed a potential risk factor for their development. [3]

While most polyps are noncancerous, about 0 to 13% can undergo malignant transformation. The likelihood of malignancy within an endometrial polyp is associated with a patient's age and menopausal status. In symptomatic postmenopausal women, the prevalence of malignant endometrial polyps is 4.47% compared to 1.51% in asymptomatic postmenopausal women. Other risk factors for malignant endometrial polyps comprise age over 60, larger - sized polyps, menopausal status, experiencing symptomatic bleeding, and having polycystic ovarian syndrome. [4]

3. Epidemiology

Endometrial polyps can develop across all age brackets, peaking in frequency between 40 to 49 years old. In reproductive - aged women experiencing abnormal uterine bleeding, the estimated prevalence of endometrial polyps ranges from 20 to 40 percent [5]. These polyps are discovered in around 10 percent of women during autopsy. Compared to postmenopausal females, premenopausal women have a lower likelihood of having malignant endometrial polyps. [6]

4. Symptoms

Signs and symptoms of uterine polyps include:

- Vaginal bleeding after menopause.
- Bleeding between periods.
- Frequent, unpredictable periods whose lengths and heaviness vary.
- Very heavy periods. [7]
- Infertility.

Some people have only light bleeding or spotting; others are symptom - free. [8]

5. Case Report

A 55 - year - old woman presented with concerns of spotting, vaginal discharge (leucorrhoea), and lower abdominal pain for the past 2 months. She underwent menopause at the age of 47 years.

The individual experienced sharp, stitching pain in the lower abdomen that worsens at night. Leucorrhoea is present and characterized by an offensive odour and slimy.

Complaints got worse in night and better in rest.

No history of Menorrhagia, No weight loss, No lumbago.

Past History and Family History:

Jaundice at the age of 20 years. Took Allopathy relieved. Her mother has diabetes, and her elder sister had carcinoma of uterus. The patient does not want any surgery so she came to Homoeopathy.

Life Space Investigation:

She was born into a middle - class family and married at the age of 21 years. Being the elder daughter - in - law in her husband's family, she faced relentless torment from her mother - in - law, but her husband didn't supported her. After a decade of enduring this, they eventually transitioned to living as a nuclear family. However, when her father - in - law passed away, her mother - in - law moved in with them, resuming her torment. Despite this, her husband continued to prioritize his mother over her. So she had hatred for her husband and mother in law. This bitterness often manifests in her interactions with her children, as she frequently shouts at them and struggles with depression.

Physical Generals:

Her appetite was normal, she has constipation, even soft stools require straining. Desire for sour foods. Thermal is chilly

Obstetric History:

G6 P5 L5 A1
Full term normal vaginal delivery

Repertorial Totality:

- Suppressed anger
- Depressed
- Shouting at her children
- Desire – Sour foods
- Stool – straining even for soft stool
- Thermal – chilly
- Stitching pain in abdomen
- Leucorrhoea slimy and offensive
- Abdomen pain aggravated at night and better by rest.

Remedy Name	Sep	Sulph	Ars	Psor	Puls	Chin	Hep	Ign
Totally / Symptom Covered	14 / 7	13 / 6	10 / 5	10 / 5	10 / 5	9 / 5	9 / 4	9 / 4
[Kent] [Mind]Anger,irascibility (see irritability,quarrelsome):Suppressed,from: (...)	1							2
[Kent] [Mind]Sadness,mental depression:Anger,after: (8)	1		1		1			
[Kent] [Mind]Sadness,mental depression: (249)	3	3	3	3	3	3	2	3
[Kent] [Stomach]Desires:Sour,acids,etc.: (77)	2	2	2	1	2	1	3	2
[Kent] [Rectum]Constipation (see inactivity):Difficult stool (see inactivity):Sof...	3	1		2	2	2	3	2
[Kent] [Abdomen]Pain:Stitching (sticking etc.): (103)	1	3	2	1	2	1	1	
[Kent] [Genitalia female]Leucorrhoea:Offensive: (46)	3	2	2	3		2		
[Kent] [Abdomen]Pain:Stitching (sticking etc.):Night: (1)		2						

Repertorial Result:

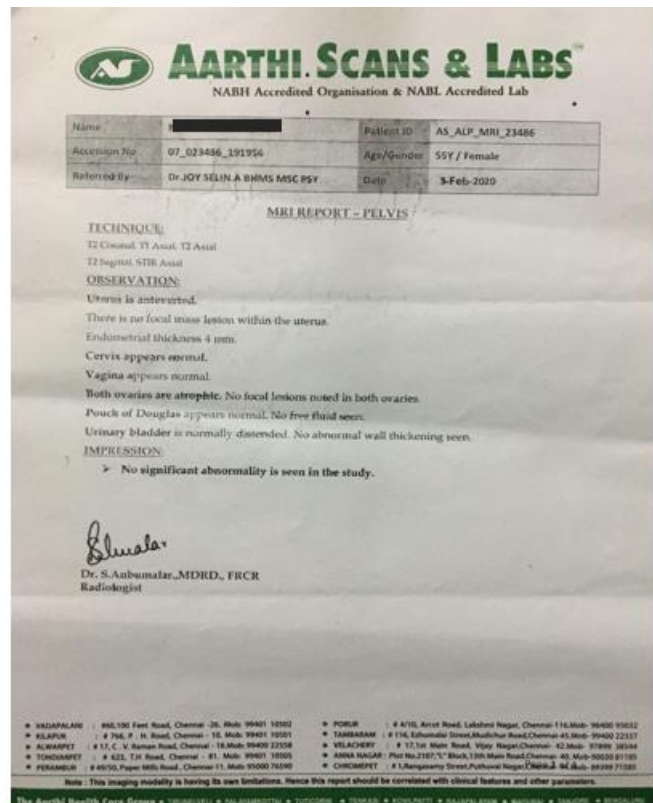
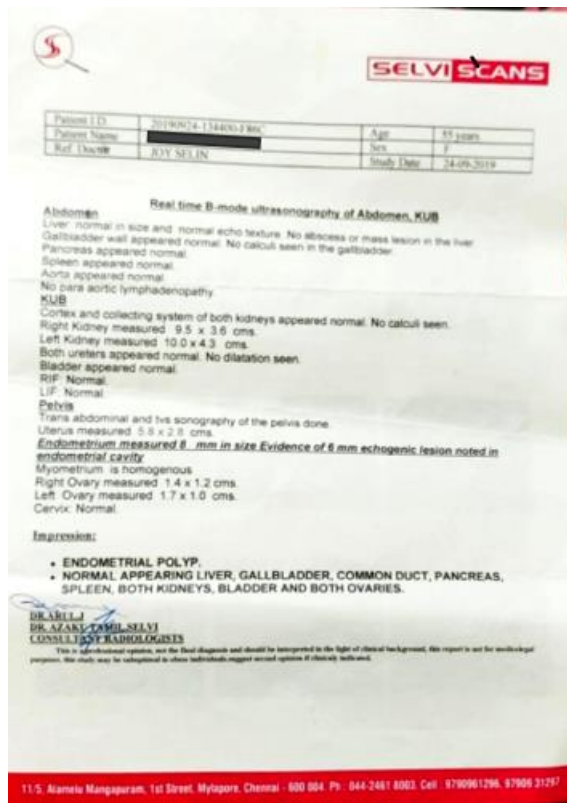
Medicine	SEP	SULPH	ARS	PSOR	PULS	CHIN	IGN
Marks	14	13	10	10	10	9	9
Symptoms Covered	7	6	5	5	5	5	4

Prescription:

After carefully evaluating the patient's case history and considering all their symptoms, a remedy was selected using the Homopath software. Finally, it was decided that SEPIA 1M was the most appropriate remedy for this case, spanning the entire spectrum, including the overall physical, mental, miasmatic and thermal picture [9]. The patient comes under sycotic miasm. Even though Sepia covers all the three miasms, it is predominantly Sycotic

Follow Up:

DATE	SYMPTOMS	REMEDY
21/09/19	Stitching pain in abdomen, Leucorrhoea offensive and slimy	SEPIA 1M / OD
23/10/19	Pain in abdomen reduced. Leucorrhoea present on and off	SEPIA 1M / OD
18/11/19	Patient feels better. Constipation reduced. Leucorrhoea reduced	SEPIA 1M / OD
22/12/19	Patient feels much better. Pain better	Placebo for 2 weeks
16/01/2020	Patient feels better. No new symptoms	Placebo / 2weeks



6. Discussion

Homeopathy is a holistic system of medicine and the treatment is based on individualization. According to Aphorism 153, Characteristic particular symptoms are taken for prescription. Individualised Homeopathic treatment could potentially serve as an alternative approach for treating endometrial polyp^[10]. Surgery is the usual choice of treatment for endometrial polyp in the conventional mode of treatment. After hormonal therapy and hysterectomy, side effects are numerous. Avoidance of surgery and preservation of uterus is possible through the Homoeopathic mode of treatment.

7. Conclusion

Results of this case indicate that individualized Homoeopathic treatment is effective in the treatment of Endometrial polyp. Although further studies employing enhanced methodologies are necessary to validate its efficacy.

References

- [1] Gültekin M, Diribaş K, Dursun P, Ayhan A. Current management of endometrial hyperplasia and endometrial intraepithelial neoplasia (EIN). *Eur J Gynaecol Oncol*.2009; 30 (4): 396 - 401.
- [2] Lacey JV, Jr, Chia VM. Endometrial hyperplasia and the risk of progression to carcinoma. *Maturitas*.2009; 63 (1): 39 - 44. <https://doi.org/10.1016/j.maturitas.2009.02.005>
- [3] Lees C, Bourne T. (Ed). Dewhurst's Textbook of Obstetrics & Gynaecology (9th ed). John Wiley & Sons; c2018.
- [4] Hiralal Konar. DC Dutta' Textbook of Gynecology.7th edition, New Central Book Agency
- [5] Williams Gynecology - by John O. Schorge, MD. Joseph Schaffer, Mdetc, McGraw - Hill Medical Publishing Company. Ch.8 and 11.
- [6] Gargett CE, Schwab KE, Brosens JJ, et al. Potential role of endometrial stem/progenitor cells in the pathogenesis of early - onset endometriosis. *Mol Hum Reprod*; c2014.
- [7] Roger Smith P. Dysmenorrhoea and Menorrhagia, A Clinician's Guide. First Edition, 2018, Springer Publishers
- [8] Howkins & Bourne. Shaws Textbook Of Gynaecology.16th Edition, Reed Elsevier India Private Limited, New Delhi; c2015. p.471 - 473.
- [9] Dr. Boericke W. New manual of Homoeopathic Materia Medica, 3rd revised and augmented edition, B. Jain Publishers, Pvt. Ltd, New Delhi.
- [10] Hahnemann S. Organon of Medicine Word Index Included, Fifth & Sixth Edition Combined, B Jain Publishers; c2017.