

# A Case of Herpes Zoster Treated with Individualized Homoeopathic Medicine - Case Report

Dr. J. Ashok., (MD - HOM)<sup>1</sup>, Dr. Dominin Raj., MD (Hom)<sup>2</sup>, Dr. Bhuvaneswari., MD (Hom)<sup>3</sup>

<sup>1</sup>PG Part II, Department of Case Taking and Repertory, White Memorial Homoeo Medical College and Hospital, Attoor, Tamilnadu

<sup>2</sup>Professor and HOD of Department of Case Taking and Repertory, White Memorial Homoeo Medical College and Hospital, Attoor, Tamilnadu<sup>2</sup>

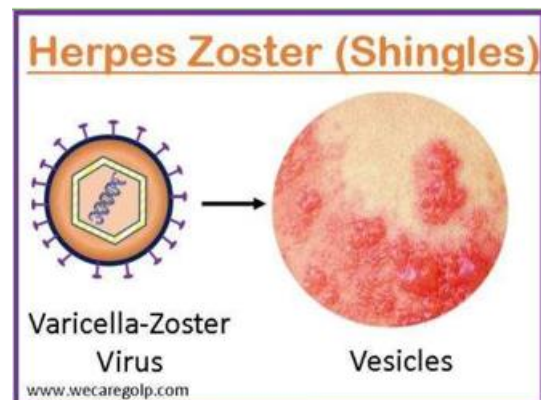
<sup>3</sup>Associate Professor, Department of Case Taking and Repertory, White Memorial Homoeo Medical College and Hospital, Attoor, Tamilnadu

**Abstract:** *Herpes Zoster (HZ) or Shingles is a reinfection of varicella virus or chicken pox. It dormant in dorsal root of spinal ganglia and cause fever, malaise, burning, painful vesicular eruptions, pustular discharge, affect facial nerve ganglion most commonly ocular and maxillary divisions and also cause post herpetic neuralgia. Homoeopathy approach cases in holistic way which treat the person according to the symptoms by framing totality and select the medicine. In this author intended to express Homoeopathic individualised medicine helps to treat the case and also avoid the further complications.*

**Keywords:** Herpes Zoster, shingles, homeopathy treatment, post herpetic neuralgia, individualized medicine

## 1. Introduction

Herpes zoster (HZ) or shingles is an acute and recurrent infection of chicken pox. It exhibits has painful vesicular eruptions which is a reactivation of dormant chicken pox virus (varicella). This is more common in 4<sup>th</sup> decades. Chicken pox and herpes zoster is caused same virus but zoster virus acquired partial immunity and it also dormant in dorsal root of spinal ganglia mainly in the cytoplasm of the neuron. It recurs and shows symptoms when it activated but the exact cause of activation is not knowing. It is more common in immune suppressed individual. It causes fever, malaise, vesicular eruptions lasting for 3 - 4 days. The pain can be lancing, deep - bore, burning, or vague, and in some cases it can be unbearable. The most common site of rupture is the ocular and maxillary division of the trigeminal nerve. Other areas of rupture include the facial nerve ganglion and the root of the thoracic or abdominal nerve. The rash begins as reddish papules that soon develop central vesicular fluid that becomes turbid within three days and crust formation within seven days.



Herpes zoster (Figure – 1)

The initial pain may subside with the formation of the pustules, but in some elderly patients it may remain in the same or altered form for several months or even years (Post - Herpetic Neuralgia). Vague paraesthesia, varying levels of sensory loss, and even a lesser degree of motor loss may remain over the affected segments for long periods of time. Generally, neuralgia is benign, but in susceptible individuals it can lead to severe distress and even suicidal tendencies. Homoeopathy is the system which have holistic approach it treats the patient as an individual and frame the totality and select the medicine according to that individual symptoms on the base of Similia similibus curenter. In this case homoeopathic medicine helps to manage the case and also avoid the further complications.

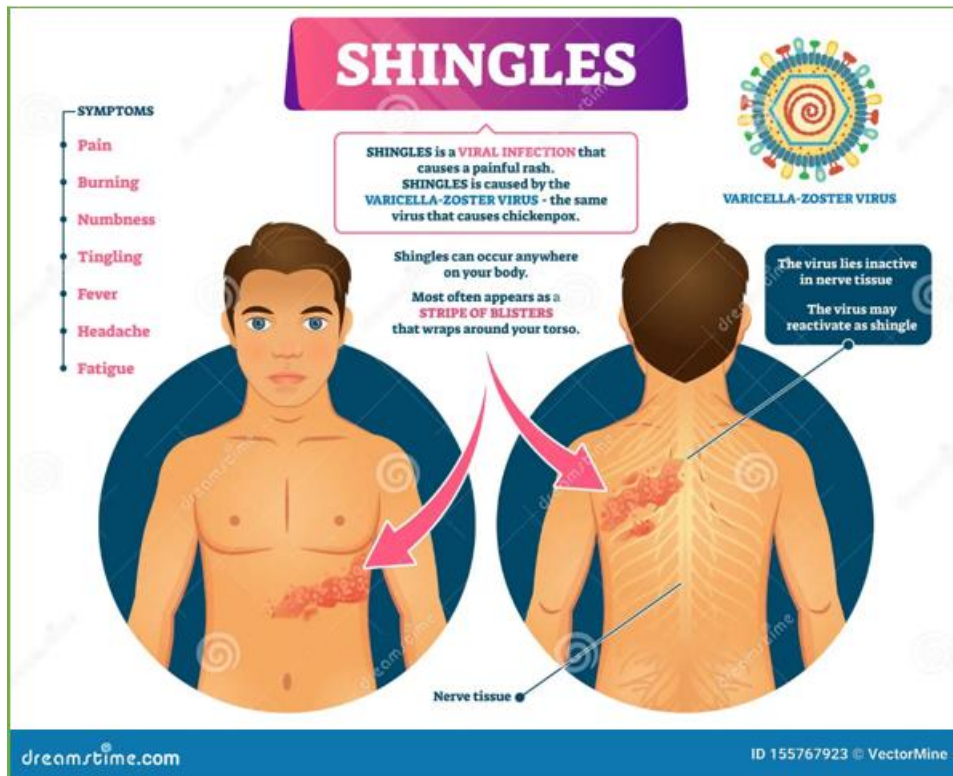


Figure 2

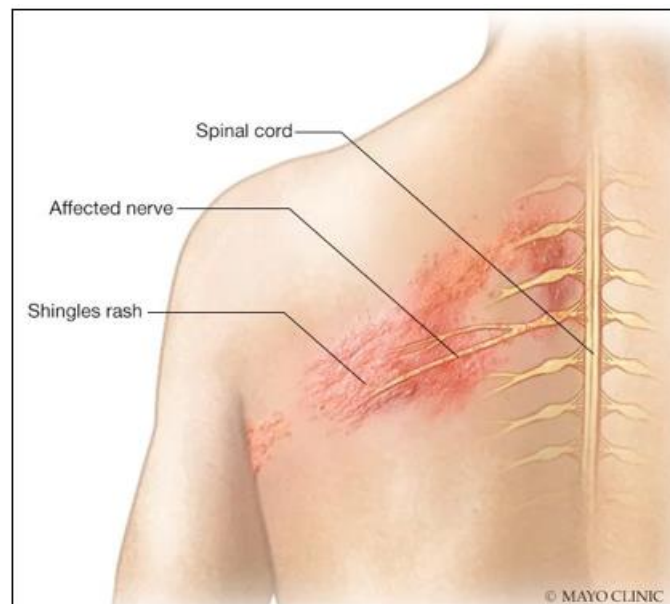


Figure 3

**Patient Profile:**

Patient Mr. X of age 50years and came with complaint of painful and yellowish eruption since 2days. Sudden onset of complaint, Painful and yellow vesicular eruption, feverish feeling present with chill, restlessness with pain, burning pain in the eruption present. Better by stretching limbs, changing position worse during rest and night. Complaint associated in headache and heaviness of head. Dryness of mouth and throat, bitter taste in mouth. Blister around mouth. No history of nausea and vomiting, Giddiness.

**Past History:**

No relevant past history

**Treatment History:**

Took allopathy medicine for fever

**Family History:**

Hypertension for his father

**Physical General:**

His appetite is reduced, bitter taste in mouth, thirst is normal with dryness of mouth and throat, passes urine for 4 - 5times, passes stool once in a day, regularly; sleep has disturbed due to complaint. chill during night.

**Mental General:**

He has been restless due to pain, anxious about health, sad about his complaints especially at night.

- > stretching limbs, changing position
- <rest, night
- Headache with heaviness feeling

**Diagnosis:**

Based on symptoms, the case diagnosed as Herpes zoster of ICD 10 code B02.

**Analysis and Evaluation:**

- Bitter taste in mouth with dryness of mouth and throat
- Blister around the mouth
- Painful and yellowish eruption
- Feverish feeling with chill
- Restlessness with pain
- Burning pain in eruption

**Repertorial Totality:**

Considering the above symptoms the case was repertorized in Radar opus 2.1.13 software (Zomoeo) Figure.1 using Boger Boenninghausen’s characteristic repertory by Dr. C. M. Boger. Most of the symptoms are covered by Arsenicum Album, Mercurius, Rhus Tox, Sepia, Sulphur, Nux Vomica. After the reference of Homoeopathic Materia Medica Rhus tox is selected. Rhus tox 1M prescribed on 05/4/2023. This case treated with successive homeopathic medicine. Advised to maintain personal hygiene.

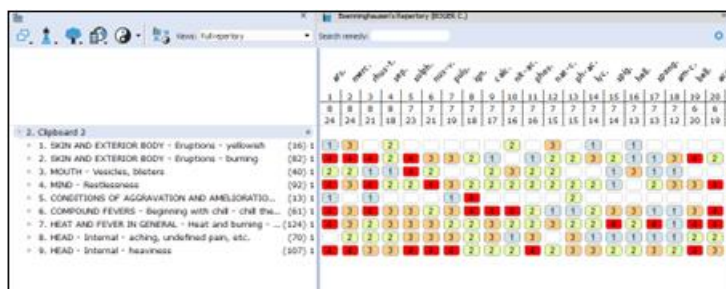


Figure 4: Repertorial Sheet

**Progress and Follow Up:**

Date of visit	Observation and result	Inference and Medicine with Potency Administration
05-04-2023	• Blister around the mouth	Rhus Tox 1M, Water dose repeated for 1hour once until pain reduced has prescribed
	• Painful and yellowish eruption	
	• Feverish feeling with chill	
	• Restlessness with pain	
	• Burning pain in eruption	
	• > stretching limbs, changing position	
	• <rest, night	
	• Headache with heaviness feeling	
	• Bitter taste in mouth with dryness of mouth and throat	
07-04-2023	• Blister around the mouth reduced	Condition improved and Placebo 3pills, 1 hour once prescribed
	• Burning pain in eruption reduced	
	• Blackish discolouration present	
	• Better by rest	
	• Physical generals are normal	
10-04-2023	• Pain around the eruption disappered	Condition improved, sac lac 1dose, OD Placebo 3pils, TDS for 1week.
	• Blackish eruption reduced	
	• Physical generals are normal	

Before Treatment (Figure 5 & 6) on 05/04/2023

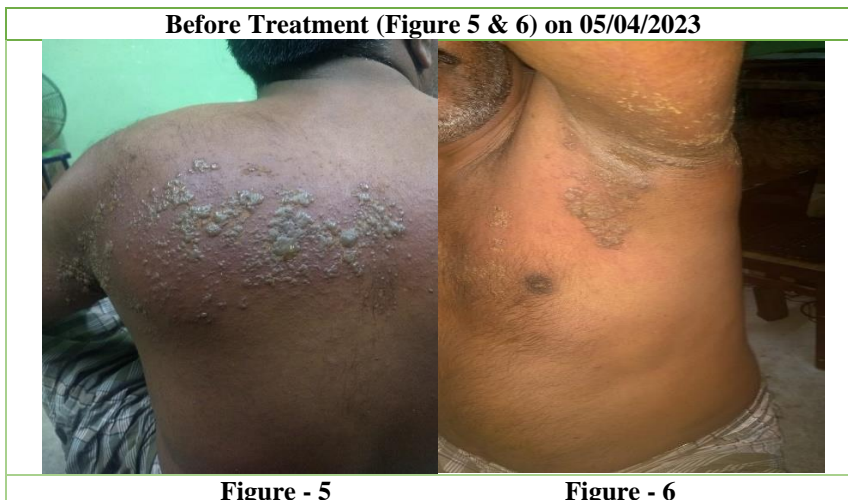

Figure - 5

Figure - 6

After Treatment (Figure 7 &amp; 8) on 10/04/2023

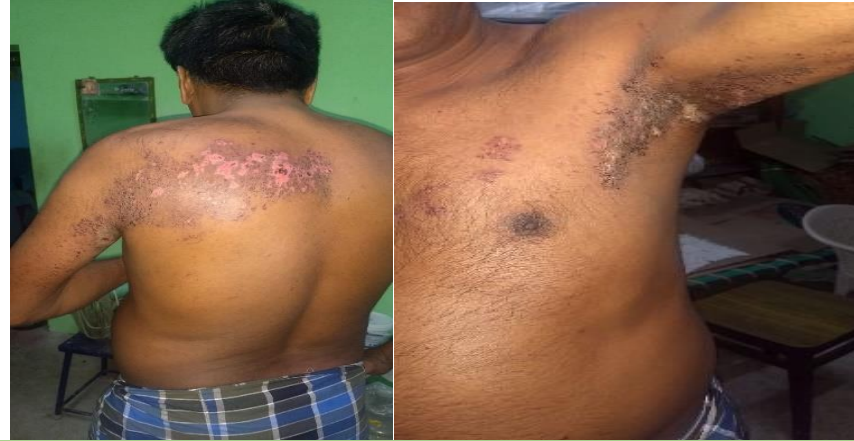

Figure - 7

Figure - 8

## 2. Result

Burning pain in the eruption has gradually disappeared and yellowish eruption is changed into pinkish colour (Fig 2 to Fig 5). Blister around the mouth changed and physical generals are returned to normal. There were no other complications of herpes zoster appeared.

## 3. Discussion and Declaration

Herpes zoster is also called as shingles. It is very common in immune suppressed individual. It is the reactivation of chicken pox (varicella virus). It causes severe pain and complications. Homoeopathic individualised and potentised medicine helps in acute condition like herpes Zoster. In this case, Rhus tox 1M is selected after referred to the materia medica which helps the person both physically and mentally. According to Organon of medicine, Dr. Hahnemann said in acute condition homoeopathic medicine can be repeated until complaints are reduced likewise Rhus tox 1M is given in water dose and repeated one hour once until the pain subsides. And the eruption has changed into pinkish colour. Hence homoeopathic similimum acted well in the case.

### Declaration of Patient Consent

The authors certify that they have obtained appropriate patient consent form. In the form, the patient has given his consent for his images and other clinical information to be reported in the journal. The patient understand that his name and initials will not be published and due efforts will be made to conceal his identity, but anonymity cannot be guaranteed.

### Financial Support and Sponsorship

Nil.

## References

- [1] Harrison's Principles of Internal Medicine, 20th Edition vol - 1, MC Grow - Hill Medical Publishing, New York, 2018; 1042 - 1045.
- [2] 2. Cotran S. Ramzi, Kumar Vinay, Collins Tucker, Robbins Pathologic Basis of Diseases, 6 thEdition, Harcourt asia Pte. Ltd.; India; 2000; 373 - 374.
- [3] 3. Davidsons Principles and Practice of Medicine,; 24 th edition, international, 2022; 879 - 8805.
- [4] James Tyler Kent, Lectures on Homoeopathic Philosophy, 2ndEdition, Modern Homoeo Publication, Kolkata, 1990; 182, 183.
- [5] Stuarts Close, The Genius Of Homoeopathy Lectures And Essays On Homoeopathic Philosophy, Reprint ed., B. Jain Publishers Pvt. Ltd., New Delhi, 1993; 140
- [6] Yogeshwari G, Khushbu P, Evidence - Based Homoeopathic Treatment of Acute Herpes Zoster (Shingles): A Case Report, Thieme Medical and Scientific Publishers Pvt. Ltd, 2021 December 31, 34 (04): 307 - 310, DOI: 10.1055/s - 0041 - 1736227
- [7] Chandranath D, EVIDENCE BASED HOMOEOPATHY IN TREATING HERPES ZOSTER - A PROSPECTIVE AND INTERVENTIONAL STUDY, International Research Journal of Pharmaceutical and Applied Sciences, 2013; 3 (2): 49 - 50
- [8] Sampathkumar P, Drage LA, Martin DP. Herpes zoster (shingles) and postherpetic neuralgia. Mayo Clin Proc 2009; 84 (03) 274 - 280
- [9] Mohini D. Shinde, Sheetal A. Patil, Anupam Mukherjee, Vijay Nema, Revisiting the therapeutic potential of homeopathic medicine Rhus Tox for herpes simplex virus and inflammatory conditions, Journal of Ayurveda and Integrative Medicine, Volume 14, Issue 4, 2023, 100739, ISSN 0975 - 9476, <https://doi.org/10.1016/j.jaim.2023.100739>.
- [10] Guess G. The Homeopathic Approach to the Treatment of Acute Herpes Zoster. Altern Ther Health Med.2023 Jul; 29 (5): 90 - 96. PMID: 37392197.
- [11] García - González AI, Rosas - Carrasco O. Herpes zoster (HZ) y neuralgia posherpética (NPH) en el adulto mayor: particularidades en la prevención, el diagnóstico y el tratamiento [Herpes zoster and post - herpetic neuralgia in the elderly: Particularities in prevention, diagnosis, and treatment]. Gac Med Mex.2017 Jan - Feb; 153 (1): 92 - 101. Spanish. PMID: 28128811.
- [12] Koshy E, Mengting L, Kumar H, Jianbo W. Epidemiology, treatment and prevention of herpes zoster: A comprehensive review. Indian J Dermatol Venereol Leprol.2018 May - Jun; 84 (3): 251 - 262. doi: 10.4103/ijdv. IJDVL\_1021\_16. PMID: 29516900.
- [13] John AR, Canaday DH. Herpes Zoster in the Older Adult. Infect Dis Clin North Am.2017 Dec; 31 (4): 811

- 826. doi: 10.1016/j. idc.2017.07.016. PMID:  
29079160; PMCID: PMC5724974.

- [14] Top Homeopathic Remedies for Shingles By Dr. Vikas  
Sharma MD [https://www.drhomeo.com/skin -  
problem/top - 6 - natural - homeopathic - remedies -  
shingles - herpes - treatment/](https://www.drhomeo.com/skin-problem/top-6-natural-homeopathic-remedies-shingles-herpes-treatment/)