

Homoeopathic Treatment Responsive in Vitiligo - A Case Report

Dr. Uzma Muneer

PG Scholar, Homoeopathic Materia Medica, Shri Guru Nanak Dev Homoeopathic Medical College and Hospital, Ludhiana, Punjab, India

Abstract: *Vitiligo, also known as Leucoderma, is a chronic skin condition characterized by the loss of pigment - producing cells (melanocytes), leading to white patches on the skin. The cure for the vitiligo seems unsatisfactory, on the other hand Homoeopathic treatment shows a beautiful recovery in a case of vitiligo presented below through A case report of a lady aged 40 years. The Medicine prescribed was Arsenicum Sulphuratum Flavum.*

Keywords: Vitiligo, Leucoderma, Pigmentation, Melanin pigment, Skin disorder, Homoeopathy

1. Introduction

Vitiligo also known as Leucoderma, is a chronic skin condition characterized by the loss of pigment - producing cells (melanocytes), leading to white patches on the skin.

Vitiligo is an acquired disease affecting 1% of the population worldwide. It may be familial and is associated with other auto immune diseases. It is characterized by the progressive disappearance of normal pigmentation in variously sized and shaped, white, smooth, sharply defined patches with hyper - pigmented borders.

Symptoms include pigmentation, the texture and functions of the affected portions remaining undisturbed. It probably begins with a moderate increase of pigment which is only observed at the border after the atrophic process has occurred.

Generalized vitiligo is often symmetrical and frequently involves the hands, wrists, knees and neck, as well as the area around the body orifices. Associated hair may also depigment. Segmental vitiligo, is restricted to one part of the body but not necessarily a dermatome. Some spotty perifollicular pigment may be seen within the depigmented patches and is sometimes the first sign of repigmentation. Sensation in the depigmented patches is normal.

The edges of the primary lesions are always convex and correspond to the concave border of hypertrophied pigment. The contrast in colour is most apparent in the summer owing to a tanning of the normal skin. Hence it is that the return of winter shows a less conspicuous condition. The progress of the whitening process is slow, consuming years when it extends over large areas. When the surface is largely involved, the map - like distribution of white and dark colour would make it seem as if the latter were the abnormal skin.

Etiology and Pathology

The cause is unknown but it is more frequent in tropical countries and in the dark races. It occurs in adults and affects equally both sexes. It has followed or been associated with malarial and eruptive fevers, such neurotic diseases as migraine, alopecia areata, scleroderma, Addison's disease and Graves' disease, exposure to extreme heat or cold, or

local injuries. These factors have little in common except that they lead to a derangement of the nervous system and this fact, in addition to the change in the skin (atrophy of pigment), leads to the assumption that vitiligo is pathologically a trophoneurosis.

General Management:

- Protecting the patches from excessive sun exposure with clothing or sunscreen may be helpful to avoid sunburn.
- Camouflage cosmetics may help those with dark skin, as can potent topical corticosteroids.
- Narrowband UVB is the most effective repigmentary treatment available for generalised vitiligo but even very prolonged courses often do not produce a satisfactory outcome.
- Autologous melanocyte transfer, using split - skin or blister roof grafts, is sometimes employed on dermabraded recipient skin.

Homoeopathic point of view:

This disease, which causes white patches on the skin, has been known for centuries and different medical sciences are trying to cure it differently.

First and foremost, it is not a contagious disease, but causes a lot of disfigurement, particularly in females. There is a lot of mental confusion in one who develops this disease. As such, its treatment is important even from the cosmetic point of view.

Human skin in different parts of the world has different hues. The colour of the skin is due to a pigment called Melanin. It is more in coloured people than among whites. When this pigment decreases, the skin turns white. It is suggested that the pigment increases when the parts are exposed to sun or ultra violet rays. Hence, many physicians ask their patients to expose the white spots to the sun after application or ingestion of their favourite medicine. Dr S. R Wadia, in his book Leucoderma, Its Homoeopathic Treatment said, in my humble opinion, external applications temporarily turn the skin rose red or dark. At times, even blisters are formed. After some time, the skin again turns white. He also said, One of my patients, who applied probably Bavchi powder, mixed with water, within a day, had huge blisters on his feet which were opened by me and dressed. After the reaction subsided, the skin turned the same colour.

Volume 13 Issue 7, July 2024

Fully Refereed | Open Access | Double Blind Peer Reviewed Journal

www.ijsr.net

Causes from homoeopathic view point:

- Certain diseases are may be responsible like, Amoebic Dysentery and intestinal parasites, Jaundice liver affections, diabetes, and tubercular infections etc.
- Suppressed skin diseases with a lot of external applications as well as powerful internal modern drugs. After a certain amount of time, the patient develops white spots.
- History of repeated vaccinations plus inoculations.
- In some cases, shock, anxiety, tension causes changes in the skin.
- Family history of leucoderma in both, or either parents the children inherit the disease.
- Cautery of the skin, particularly the growths on the skin like warts, or moles, are very often responsible for some peculiar skin diseases and this is one of them.
- Miasmatic Conditions, like Psora, Psycosis, Syphilis.
- It was observed that there were certain points where the ratio between sodium and potassium is low, high and very high and can be classified as, (i) Hormonal (ii) Hereditary (iii) Acquired and (iv) Idiopathic

Diet

died plays an important part and certain foods are considered responsible for this disease. Modern people eat too much and it is a fashion to eat out, they don't know what they eat under various fancy names. This animal harbours a lot of parasites and eggs which are in the form of cysts. After eating the cyst wall is digested and the tiny worms are released in the intestines, to do havoc in human beings so it should be avoided.

- Milk with oily food or curds with sour dishes and radish. Milk and curds with flesh and fish is also to be avoided. Fruit, milk and meat together, is contrary food. Green and red radish, beet roots, carrots, plumes, spinach, black currents and black dates are very good as diet.
- According to Dr Mufti, psoralens may be the components of normal diet as they are present in such plants as celery, figs, parsley, carrots, caraway, anise, citrus fruits etc.
- Avoid drinking outside water, boil your water and filter it, milk and milk products are to be avoided.
- Take wheat chapati and avoid white bread, add bran to the wheat flour as much as possible. Pan and tobacco are to be avoided.

Homoeopathic Management:

As we know the other treatments for vitiligo or leucoderma is unsatisfactory, Homoeopathic offer very good and responsive treatment. There are thousands of homoeopathic medicines which can be prescribed in vitligo on the basis of symptoms similarity after proper case taking. Medicines can be prescribed according to constitution of the patients, also on the therapeutic bases, Homoeopathic medicines have very good effects in management of vitiligo.

A Case Report

Patient Information: A 40 years female patient came with the complaint of white patch on scalp, (frontat part of scalp), skin discoloured, clear white patch for about 3 years.

She told she had premature graying of hairs so always used to dye her hairs, and she had a doubt that she started having

this complaints after using some dye, which she even don't remember which of the dye she used. Patient have itching and burning of skin. She had taken a lot of medicines in past two years and did not get any satisfactory result. Used so many medicines and oils directly on the affected area but not improved and its becoming worse day by day.

Generalities: She is very anxious and this anxiety became more as the day precede I became fearful. Fear especially at night. Fear of disease always what happened to my head. Always pray to god for its cure, very religious. On inquiring further she told she always had heaviness of abdomen after eating, extreme thirst for cold water, she said my day starts with water and thirsty in the morning. Appetite normal, always eat warm food does not like cold food.

Diagnosis: A clear case of leucoderma.

Analysis of case and Repertorisation:

After the complete case taking according to the Homoeopathic principles following characteristic symptoms were taken in to consideration for Analysis, Evaluation, and Repertorisation.

- Fear at night
- Anxiety
- Religious
- Skin pigmentation
- Skin discoloration
- Burning
- Itching
- Thirst excessive in the morning
- Loathing of food after eating
- Always want warm food

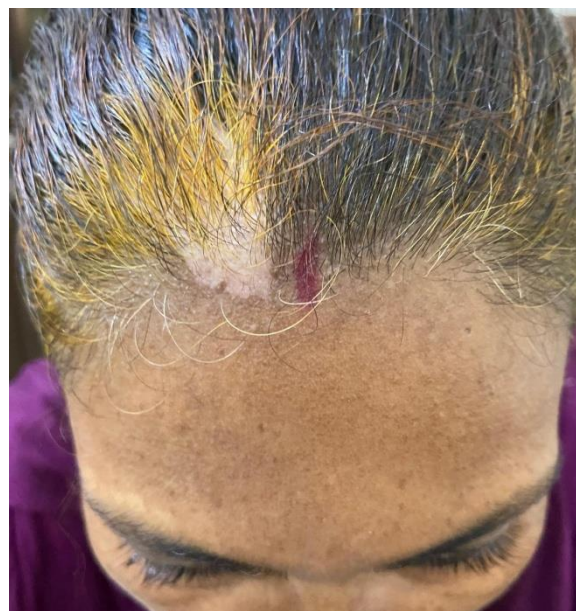

Figure 1: Before treatment
(23rd August 2023)

All of the above symptoms converted in to rubrics and repertorisation was done from the Homoeopathic software Radar 1.1.13.

After repertorisation, maximum number of symptoms (10) covered by three medicines, i. e. First grade - Arsenic album, Second grade - Calcarea carb, and third grade - Arsenicum

sulphuratum flavum. After further study from the material medica Arsenicum sulphuratum flavum 30, was prescribed

to the patient. Medicine was repeated during follow up according to the need of the patient.

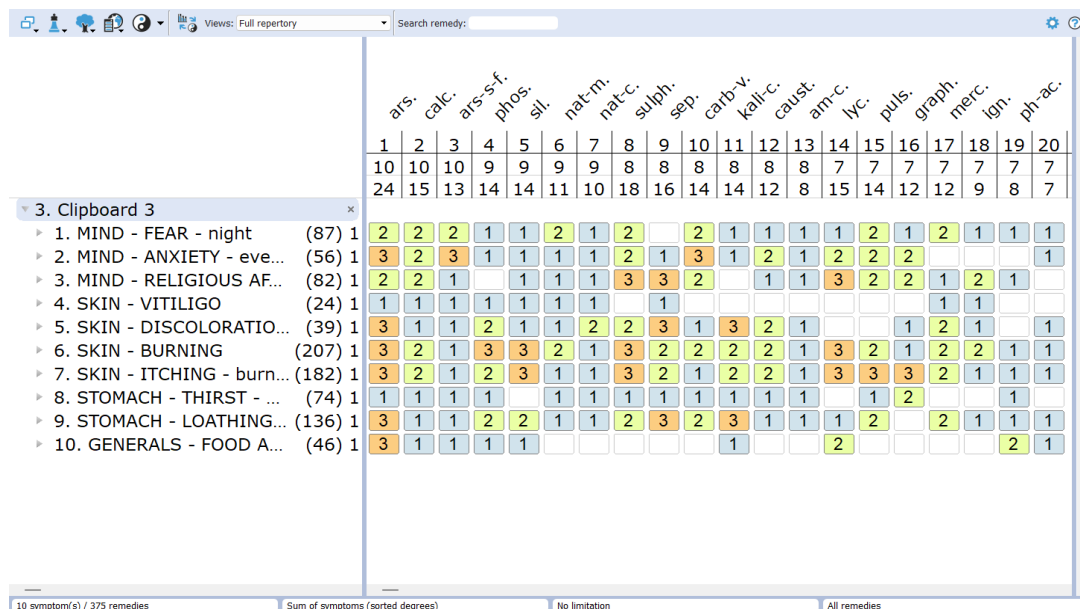


Figure 2: Repertorisation chart

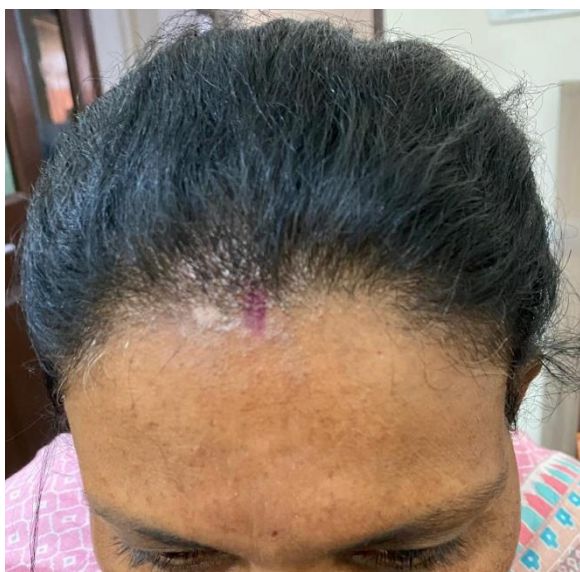

Figure 3: After treatment (15 March 2024)

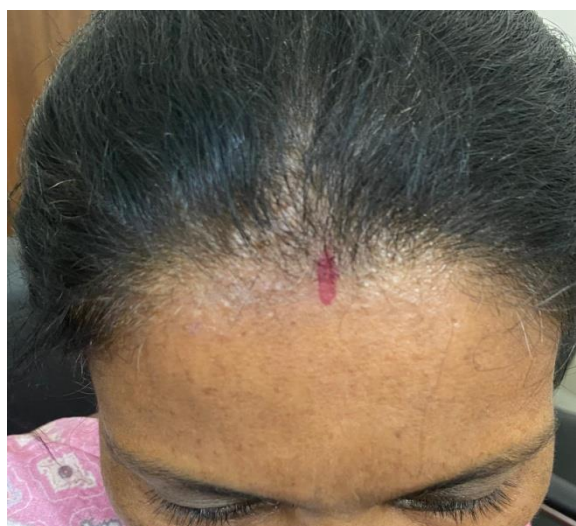

Figure 4: After treatment (25th May 2024)

2. Discussion and Conclusion

As the cure for the vitiligo seems impossible and unsatisfactory, on the other side by the grace of Allah, The Almighty Homoeopathic is responsive in cases of vitiligo. By adopting the similimum in the above case, the patient was treated very well from Homoeopathic medicine, Arsenicum sulphuratum flavum. **So we can conclude that Homoeopathy is effective in treatment of vitiligo or leucoderma.**

References

- [1] S. R Wadia, Leucoderma: Its Homoeopathic Treatment reprint edition 2002, 2004 B jain publsher
- [2] FREDERICK M. DEARBORN, A. B., M. D Reprint edition 1993 B. Jain Publishers (P) Lttd.
- [3] Davidson’s essentials of medicine, 2nd edition, Elsevier.
- [4] Boericke W. Pocket Manual of Homoeopathic Materia Medica & Repertory: Comprising of the Characteristic and Guiding Symptoms of All Remedies (clinical and Pahtogenetic [sic]) Including Indian Drugs. B. Jain publishers; 2002.
- [5] Repertorisation from Homoeopathic software RadarOpus 2.1.11