

Near Total Airway Obstruction in a “Bleeding Tracheostomy”-A Roller Coaster Ride

Dr. Soumi Pathak¹, Dr. Itee Chowdhury², Dr Nitesh Goel³, Dr. Anusha⁴

Running Title: Late tracheostomy bleed causing airway obstruction

Abstract: *Late tracheostomy bleed can cause life-threatening airway obstruction. Timely detection is paramount, as even small quantities of endobronchial blood can lead to a substantial deterioration in gas exchange and hypoxemia. Moreover, the altered colour of the organised clot can sometimes give a deceptive appearance of a tumour mass. In this case report, we would like to highlight how a multidisciplinary team helped in identifying the cause of the airway obstruction thereby enabling prompt intervention.*

Keywords: Airway obstruction, tracheostomy, Haemorrhage

1. Introduction

Tracheobronchial airway obstruction is a critical medical emergency that demands immediate intervention. [1, 2] This report presents a case of acute near-complete airway obstruction in a tracheostomised patient on postoperative day three. Bronchoscopy revealed a large pale-yellow mass occluding nearly 90% of the tracheal lumen. [2]

2. Case Report

A 46-year-old male, post-operative case of Carcinoma tongue with Temporary tracheostomy and radial artery free flap, developed acute onset of severe respiratory distress on POD-3. His BP is 90/70 mm Hg, pulse-130/min and Spo2-85%. Laboratory investigations revealed a Hb-7, INR-1.44 and platelet 1.9lakhs. Tracheostomy suctioning, nebulization and oxygen supplementation were done. Chest x-ray revealed left lung collapse. FIG1 After obtaining informed consent, he was shifted to the operation theatre for emergency re-exploration.

In the operation theatre (OT), monitors were attached, a wide-bore IV was secured, and fluids started. As the patient was very anxious and agitated, Injection dexmedetomidine infusion was started, and 20µg of Injection Fentanyl was administered. While arranging the bronchoscope, his left radial artery was cannulated, and he was put on pressure support ventilation with 100% Oxygen. The airway peak pressure was 40. A fiberoptic bronchoscope (FOB) was inserted through the swivel connector, revealing a large pale-yellow mass just below the tracheal stoma, causing 90% occlusion of the tracheal lumen. The surgeon was clueless regarding the aetiology of the mass. The possibility of a tracheobronchial tumour FIG2 had to be ruled out, so the interventional pulmonologist was notified urgently. With the help of long MLS forceps, the mass was gradually separated from the tracheal wall. The patient desaturated during the procedure, and SpO2 went up to 80%. Manual assisted ventilation with 100% oxygen revealed a stony hard bag and high peak pressure. His heart rate decreased to 37/min and blood pressure was 70/50 mm of Hg. Injection atropine was given, and Inj. Noradrenaline infusion was started. A ball valve occlusion of the trachea was suspected, so the circuit was disconnected, to allow the egression of the

trapped air. Fortunately, the pulmonologist was able to take out a large portion of the tracheal mass. The patient became hemodynamically stable. However, the patient's saturation failed to improve. Ultrasound scanning of the lung was done to rule out pneumothorax.

Further, bronchoscopy revealed that the mass was extending beyond the bifurcation of the trachea, completely occluding the left bronchus and partially occluding the right bronchus. In the meantime, a cut section of the tracheal mass revealed it to be an organized blood clot. The pulmonologist took out around 350ml of blood clots from both the lungs with the help of forceps and cryoprobe. Gradually the lung compliance, the airway pressure and saturation of the patient improved. Exploration of the neck revealed an aberrant anterior jugular vein and oozy thyroid tissue. The vein was ligated, and the surrounding area was cauterised.

The patient was then paralyzed and shifted to the SICU for elective ventilation. The next day, the chest X-ray revealed significant improvement. The patient was weaned off the ventilator over two days and, after his saturation improved, shifted to the ward with stable vitals and Spo2-98%. The patient was discharged from the hospital on POD-9.

3. Discussion

A rare presentation of late tracheostomy bleed is near complete obstruction of the tracheobronchial tree with clots. It is a life-threatening complication which requires early intervention. [3] Moreover, the altered colour of the tracheobronchial clot can sometimes give a deceptive appearance of a tumour mass. The early signs are a sudden increase in peak airway pressures, paradoxical breathing, increased end-tidal carbon dioxide level, and decreased oxygen saturation. [4]

In our patient, the thrombus caused a ball valve obstruction of the tracheal lumen. Although inspiration was possible with high pressure, the thrombus prevented the egression of air from the lung. This resulted in increased intra-thoracic pressure, severe bradycardia and cardiovascular collapse. The patient became haemodynamically stable after the massive clot was removed, but the saturation improved only after the pulmonologist removed the clots from both lungs.

The primary cause of immediate haemorrhage after tracheostomy is usually ooze from the stomal granulation tissue. [2] Other causes may include vascular anomalies, such as an aberrant anterior jugular communicating vein, a high left brachiocephalic vein, a high inferior thyroid vein, or an abnormal coagulation profile. [4] Thromboelastography may help in early detection of coagulopathy. In this case, diffuse ooze was found from the thyroid tissue, and an aberrant anterior jugular vein was found. Early identification of tracheostomy bleeds is important because even small amounts of endobronchial blood can cause significant deterioration of gas exchange and hypoxaemia. [5]

Careful Suctioning should be done to localise the source of bleeding. External compression, surgical clips, cauterisation or gauze soaked with adrenaline or tranexamic acid are often used for external bleeding. [6] However, bleeding within the stoma may require bronchoscopy-guided electrocoagulation and cryoablation. In instances of firmly adherent clots, the Fogarty arterial embolectomy catheter or application of thrombolytics directly onto the surface of the clot, and forceps removal in a piecemeal fashion may be advocated. [6]

Lastly, patients with a history of previous surgery, radiation and distorted anatomy are not only associated with difficult tracheostomy but are also more prone to post-tracheostomy bleed. [4] Thus strict vigilance and a prompt diagnosis are the keys to preventing the catastrophic complication of the airway. A multidisciplinary team is the need of the hour.

References

- [1] Stockin M. D. et al. 'Tracheobronchial thrombus in a combat wounded patient with a new tracheostomy'. *Journal of Bronchology & Interventional Pulmonology*.2020; 27 (3): 216–218. doi: 10.1097/lbr.0000000000000680.
- [2] Bradley PJ. 'Bleeding around a tracheostomy wound: What to consider and what to do?'. *The Journal of Laryngology & Otology*.2009; 123 (9): 952–956. doi: 10.1017/s002221510900526x.
- [3] Shlugman D, Satya-Krishna R, Loh L. 'Acute fatal haemorrhage during percutaneous dilatational tracheostomy'. *British Journal of Anaesthesia*.2003; 90 (4): 517–520. doi: 10.1093/bja/aeg074.
- [4] Beiderlinden M. et al. 'Risk factors associated with bleeding during and after percutaneous dilatational tracheostomy*. *Anaesthesia*.2007; 62 (4): 342–346. doi: 10.1111/j.1365-2044.2007.04979. x.
- [5] Lewith H, Athanassoglou V. Update on management of tracheostomy. *BJA Education*.2019; 19 (11): 370–376. doi: 10.1016/j. bjae.2019.08.002.
- [6] Gadowski J, Zawadka M. Removal of airway obstruction due to presence of blood clots and the role of tranexamic acid – case report. *Anaesthesiology Intensive Therapy* 2022; 54 (2): 190–193. doi: 10.5114/ait.2022.115350.

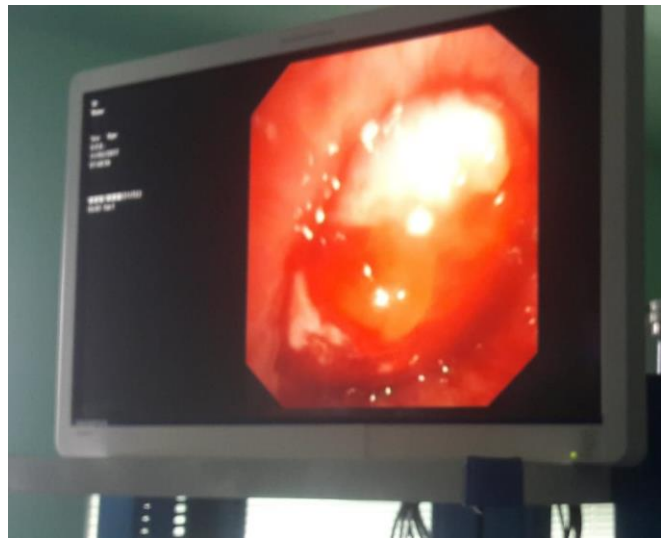

Figure 1: Tracheal Mass Yellow Coloured

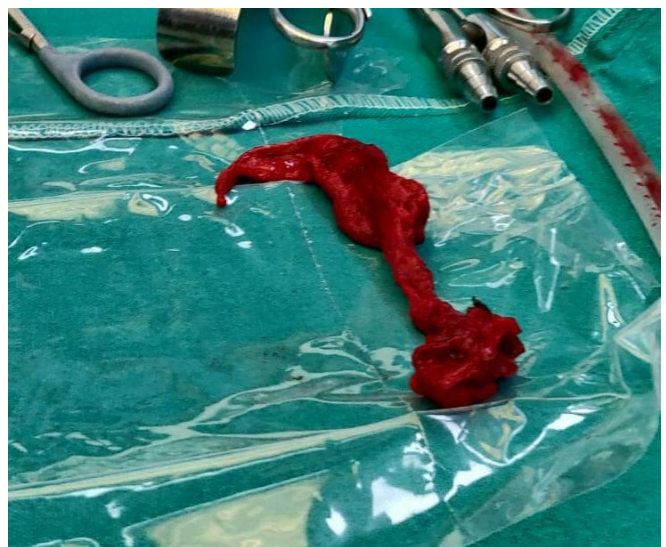


Figure 2: Tubular Organised Clot