

MRI Evaluation of Acute Knee Injury in Road Traffic Accidents Involving Motorcycles

Dr. Sujay Bani

BGS Global Institute of Medical Sciences

Email: [sujayub07\[at\]gmail.com](mailto:sujayub07[at]gmail.com)

Abstract: This study aims to evaluate the effectiveness of diagnostic MRI in assessing post-traumatic knee joint injuries resulting from motorcycle road traffic accidents and to identify common injury patterns involving knee structures. Conducted as a retrospective analysis at a medical college, the research included 68 patients who underwent MRI within one month of their accident. Standard MRI protocols were followed, utilizing sequences such as sagittal PD FS, coronal T1 TSE, and STIR. The findings revealed that the anterior cruciate ligament and medial meniscus were the most frequently injured structures, with joint effusion being less common than bone marrow contusions. Fractures were the least observed injury. The study highlights MRI as a reliable, non-invasive diagnostic tool for knee trauma in motorcycle accidents, particularly in the South Indian population, and provides valuable insights for radiologists in trauma settings.

Keywords: knee injuries, MRI, motorcycle accidents, trauma imaging, anterior cruciate ligament

Aims

- 1) To review the efficacy of diagnostic MR imaging to evaluate post-traumatic knee joint injuries in motorcycle road traffic accidents.
- 2) To demonstrate patterns of injuries, involving structures of knee joint.

1. Background

The knee joint is a hinge type of synovial joint, formed collectively by the articulations between the patella, femur and tibia. It is one of the most thoroughly studied and treated joints for a variety of pathologies including trauma being one of the most impactful aetiologies. Unlike sports injuries where the nature of insult can be pin-pointed to a set mechanism, road traffic accidents most often result in a combination of insults with temporal and spatial differences. And magnetic resonance imaging is a substantial diagnostic imaging modality to evaluate such patients. In developing countries, such as ours, motorcycles are one of the most used modes of transport in both rural and urban settings. The knowledge about patterns of knee injury in road traffic accidents involving motorcycle is seldom researched upon in current literature.

2. Materials and methods

A retrospective study of knee joints evaluated with MRI within one month after a motorcycle road traffic accident was conducted at a medical college level. Standard institutional protocols and MRI sequences were utilized for the same. The findings were then compared and corroborated with existing literature on knee joint trauma and interpreted to arrive at a result.

MRI parameters: FOV 14 - 16 cm, and section thickness of 3 - 4 mm, matrix 560 x 1024. Sequences included were sSagittal PD FS (PD: Proton density, FS: Fat saturation) and PD TSE (TSE: Turbo spin-echo), coronal T1 TSE and STIR (STIR: Short tau inversion recovery), and axial PD FS and T1 TSE sequences.

Inclusion criteria:

- All the patients referred to our department for MRI imaging with knee complaints following motor bike trauma.

Exclusion criteria:

- Patient with past history of knee surgeries or prosthetic implants in-situ.

3. Results

Among a total of 68 cases included in this study over a period of 6 months, males and females had equal representation, with most of the participants being young adults. The left knee was more commonly injured than the right knee. The anterior cruciate ligament was the most common injured structure followed by the medial meniscus. Joint effusion was seen in fewer cases than bone marrow contusions. Fracture was the least observed finding. Precise numbers and statistics representing the above mentioned and rest of the findings are described below in graphical representations.

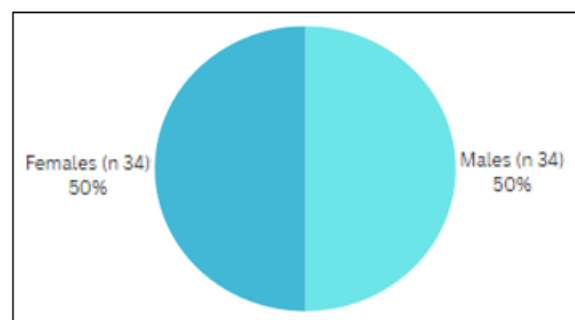


Figure 1: Sex distribution

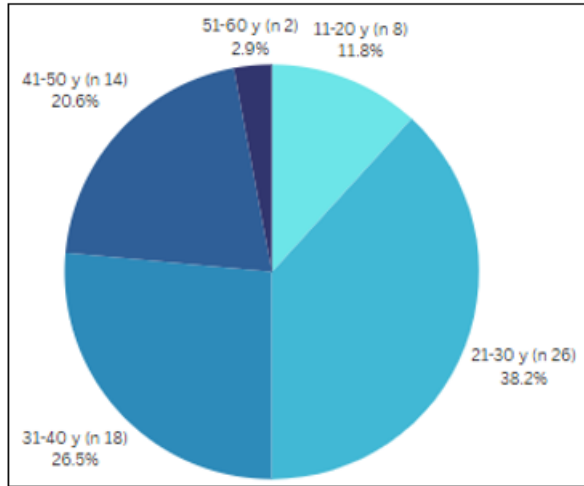


Figure 2: Age distribution

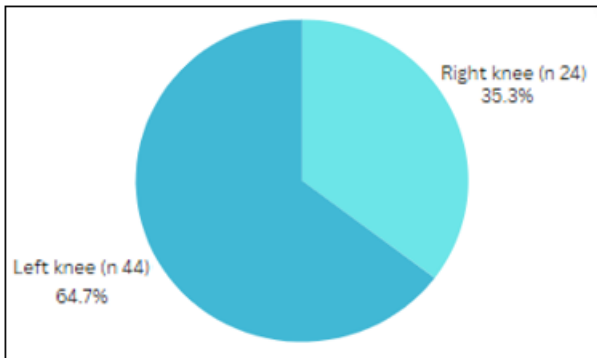


Figure 3: Side involved (R/L)

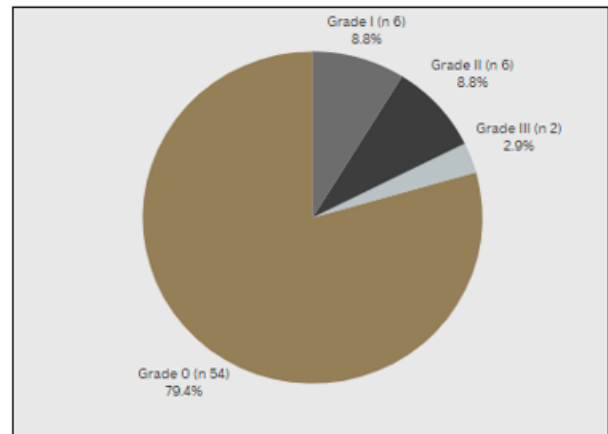
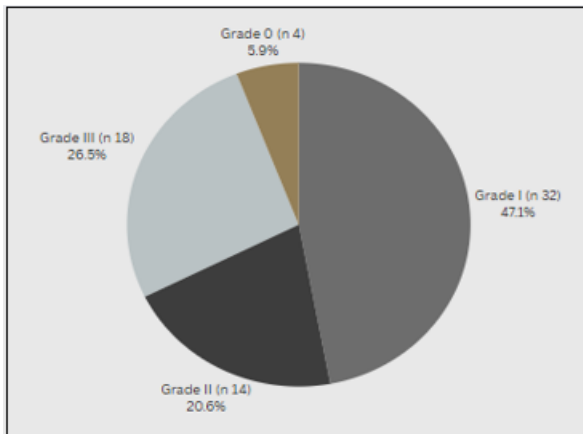


Figure 4: Anterior (Fig.4a) and Posterior (Fig.4b) cruciate ligament injuries.

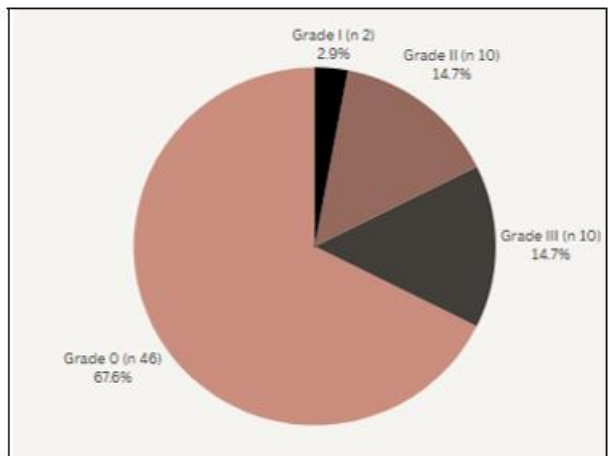
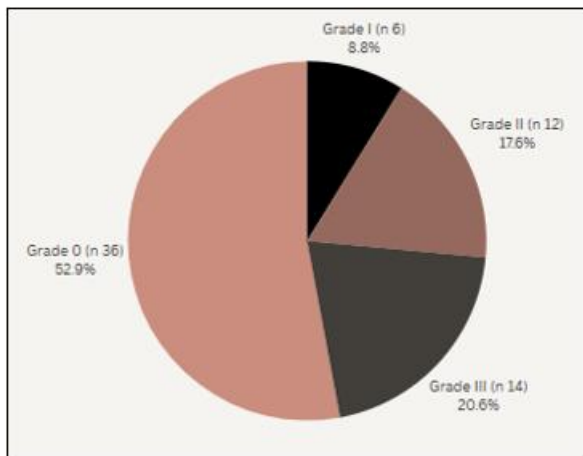


Figure 5: Medial (Fig.5a) and Lateral (Fig.5b) collateral ligament injuries.

Table 1: Ligament and meniscal injuries

	Injured	Not Injured	% Injured
Anterior Cruciate Ligament	64	4	94
Posterior Cruciate Ligament	14	54	20
Medial Collateral Ligament	10	58	14
Lateral Collateral Ligament	24	44	35
Medial Meniscus	32	36	47
Lateral Meniscus	22	46	32

Table 2: Bone contusions

Bone Marrow Contusion			Total (n)
Femur	Medial Condyle	8	28
	Lateral Condyle	20	
Tibia	Medial Condyle	4	20
	Lateral Condyle	16	
Fibula			6

Table 3: Knee joint effusion (present/ absent)

Joint Effusion	n
Joint Effusion	24

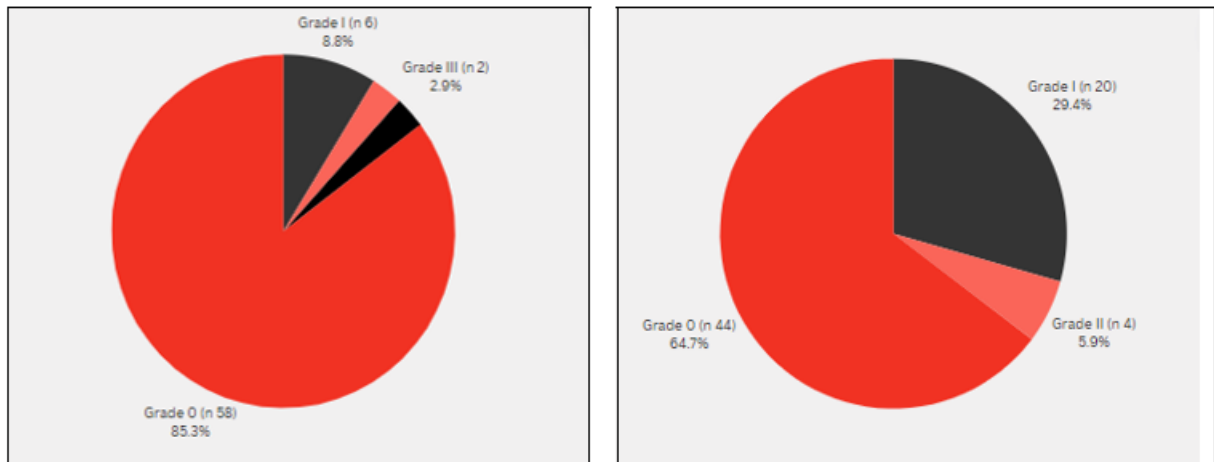


Figure 6: Medial (Fig.6a) and Lateral (Fig.6b) meniscus injuries.

4. Conclusion

Multi - sequence multi - planar magnetic resonance imaging is a practical, non - invasive and a precise imaging technique for diagnostic evaluation of knee joint trauma related to road traffic accidents involving motorcycles. The results of this study are relevant and unique to motorcycle accidents in the south Indian population and can be utilized to add on to the existing knowledge of the reporting radiologists at trauma centers.

References

- [1] Dr. Ashwini Sankhe, Dr. Aakash Vaswani, Dr. Shraddha Karhadkar. MRI evaluation in knee joint injuries related to bike trauma. International journal of scientific research. Volume 8, issue 8, August 2019.
- [2] Rajesh Umap, Bijpuriya Anurag, Sachin Bagale, Navid Shattari. Evaluation of traumatic knee joint injuries with MRI. International Journal of Contemporary Medicine Surgery and Radiology.2018; 3 (3): C77 - C81.
- [3] Mu J, Reddy DLVB. Role of Mri in Meniscal Tears dr. IOSR J Dent Med Sci 2017; 16 (3): 111–7.
- [4] Shetty, Lakhkar B, Krishna G. Magnetic resonance imaging in pathologic 138 conditions of knee. Indian J Radiol Imaging.2002; 12 (3): 375.
- [5] Madurwar AU, Ramya M, Kumar S et al. Evaluation of role of MRI in knee joint injuries in correlation with arthroscopy. International Journal of Research and Review.2017; 4 (7): 40 - 46.