

# Early Clinical Outcomes of Arthroscopic ACL Reconstruction Using Peroneus Longus Tendon Autograft

Dr. Sandeep Kumar Deep<sup>1</sup>, Dr. Varun Phogat<sup>2</sup>, Dr. Manish Sharma<sup>3</sup>

<sup>1</sup>Senior Resident, Department of Orthopaedics, Pandit Madan Mohan Malviya Hospital, New Delhi, India  
Corresponding Author Email: [docsandeep23\[at\]gmail.com](mailto:docsandeep23[at]gmail.com)

<sup>2</sup>Senior Resident, Department of Orthopaedics, Pandit Madan Mohan Malviya Hospital, New Delhi, India

<sup>3</sup>Head of Department, Department of Orthopaedics, Pandit Madan Mohan Malviya Hospital, New Delhi, India

**Abstract:** **Background:** Peroneus Longus Tendon (PLT) graft use in ACL reconstruction offers several promising features, including faster harvesting, optimal graft thickness, and minimal impact on knee joint stabilizers. However, the impact of peroneus longus tendon (PLT) graft harvest on donor ankle morbidity has been a topic of debate, with conflicting opinions presented in various studies. This study aims to evaluate the efficacy of peroneus longus tendon autografts in ACL reconstruction and assess their impact on donor ankle function through clinical and functional outcome measures. **Material and Method:** The study involved 30 patients who underwent ACL reconstruction using a peroneus longus tendon (PLT) autograft with an endobutton and biointerference screw. The outcomes of the ACL reconstruction were evaluated using the Tegner-Lysholm and IKDC scores. Additionally, donor site morbidity in the foot and ankle following tendon harvesting was assessed using the American Orthopedic Foot and Ankle Society (AOFAS) and the Foot and Ankle Disability Index (FADI) scores. **Result:** The average age group in our study was 29.3 years with a range of 18 to 53 years. The mean peroneus longus tripled graft diameter in our study was 8.63 with a range of 7.7 to 9.6 mm. The mean IKDC score preoperatively was 54.3±6.34, and postoperatively at the final follow-up was 94.2±10.60. The mean Tegner-Lysholm score preoperatively was 59.5±8.8, and postoperatively it was 96.3±5.8. AOFAS score at final follow-up was 97.94±3.42 as compared preoperatively to 98.32±1.63, while FADI score at 12 months was 97.62±1.15 as compared to 98.08±2.85 preoperatively. **Conclusion:** The peroneus longus tendon (PLT) graft is a safe and effective alternative for arthroscopic ACL reconstruction and can be considered a primary graft choice. PLT grafts in ACL reconstruction result in significant functional improvements, as indicated by IKDC and Lysholm-Tegner scores. Furthermore, the excellent AOFAS and FADI scores at final follow-up indicate no significant donor site morbidity with preserved ankle function.

**Keywords:** ACL Reconstruction, Autograft, Peroneus Longus Tendon Graft, Donor ankle morbidity, Functional outcome

## 1. Introduction

Anterior cruciate ligament (ACL) injuries are prevalent among athletes and physically active individuals, significantly impacting knee stability and function. ACL reconstruction is essential to regain knee stability and prevent further damage to knee including meniscal injuries and early degeneration of cartilage<sup>1,2</sup>.

ACL reconstruction is one of the most commonly performed orthopedic procedures worldwide, yielding positive clinical outcomes and allowing patients to return to their previous levels of activity. Autografts are the preferred choice for ACL reconstruction and include quadrupled hamstring grafts, Patellar Tendon, Quadriceps Tendon, and Peroneus Longus tendon.

The Bone-Patellar Tendon-Bone (BPTB) has long been regarded as the 'gold standard' graft for primary ACL reconstruction, particularly in young and active patients. However, concerns about donor-site morbidity, such as anterior knee pain from PT harvesting, patella fracture and patellar tendon ruptures have led others to prefer alternative autograft options<sup>3,4</sup>. Hamstring tendon (HT) graft is one of the most commonly used autograft worldwide because it provides better strength than BPTB. However, variability in muscle diameter and tendon size among individuals can lead to

inconsistencies in graft performance and a decrease in hamstring power following harvest<sup>5</sup>.

Peroneus longus Tendon (PLT) grafts were previously reserved for revision cases or multi-ligamentous reconstructions, but they are now recognized as a viable option for primary reconstruction as well. The PLT offers several promising features, including faster harvesting, optimal graft thickness, and minimal impact on knee joint stabilizers, reducing the risk of complications<sup>6</sup>. However, the impact of peroneus longus tendon (PLT) graft harvest on donor ankle morbidity has been a topic of debate, with conflicting opinions presented in various studies. While most studies indicate that patients undergoing ACL reconstruction with peroneus longus grafts experience no significant ankle or foot disability, some have raised concerns about its potential inferiority for primary ACL reconstruction due to its negative impact on inversion-eversion and ankle stability<sup>7-9</sup>.

This study aims to evaluate the efficacy of peroneus longus tendon autografts in ACL reconstruction and assess their impact on donor ankle function through clinical and functional outcome measures. Given the limitations of conventional ACL graft choices, investigating the peroneus longus tendon as a primary graft alternative is crucial. This study provides clinical insights into its viability, potentially broadening options for ACL reconstruction.

## 2. Material and Method

This is a prospective cohort study conducted in the Department of Orthopedics, Pandit Madan Mohan Malviya Hospital, New Delhi from May 2020 To May 2023 following formal approval from the institute's ethical committee and signing of informed consent forms by the participating patients. ACL tears were diagnosed through a detailed medical history, physical examination, and MRI of the injured knee. Strict adherence to international ethical standards was ensured.

### Inclusion criteria:

- Patient aged >18 years and <50 years.
- Clinical and Radiological evidence of ACL tear with symptoms of knee instability.
- A normal contralateral knee.

### Exclusion criteria:

- Multiligament injury.
- Associated meniscal injuries.
- Bilateral anterior cruciate ligament deficiency.
- Presence of fractures around the knee.

Following a thorough description of the treatment, its prospective outcomes, potential complications, and the lengthy rehabilitation process that would ensue, the chosen patients gave their informed consent.

### Procedure

The patient was put in a supine position following the administration of adequate anesthesia (spinal/spinal and epidural/general). A pneumatic tourniquet was used, and the pressure was adjusted based on the systolic blood pressure before anesthesia. Diagnostic arthroscopy performed through standard anterolateral portal and anteromedial portal.

### Graft Harvesting

A 3 cm longitudinal incision was made over the posterior border of the lateral malleolus. Peroneal sheath was then incised along the line of incision. Peroneus longus tendon identified (**Figure 1**). Both Peroneus longus and Peroneus brevis tendon were identified (**Figure 2**). PLT was excised (**Figure 3**), and the remaining distal part was secured to peroneus brevis through tenodesis with ethibond 5-0. The proximal end of the tendon was released by a closed tendon stripper (**Figure 4**), extending up to a maximum length of 5 cm distal to the fibular head to prevent injury to the common peroneal nerve and tripled in length after separating the muscle tissue. Graft diameter and length were measured (**Figure 5**). Absorbable sutures were used to close the peroneal sheath, while non-absorbable sutures were used to close the incision wound.

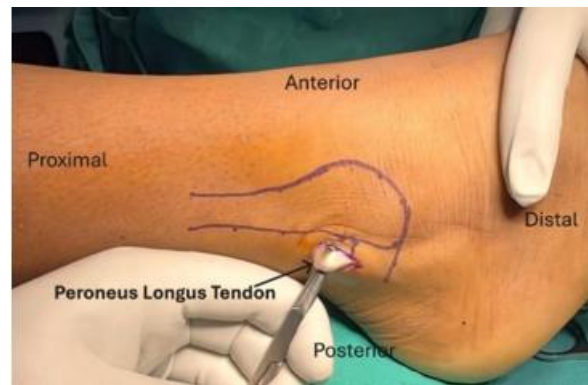


Figure 1

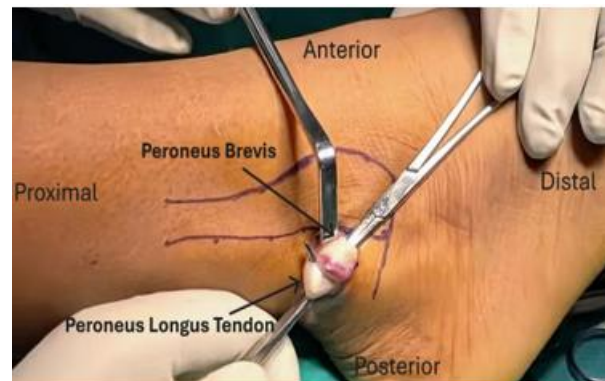


Figure 2

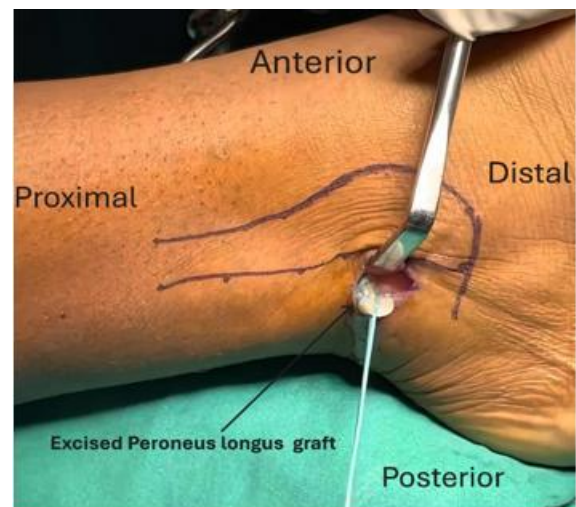


Figure 3

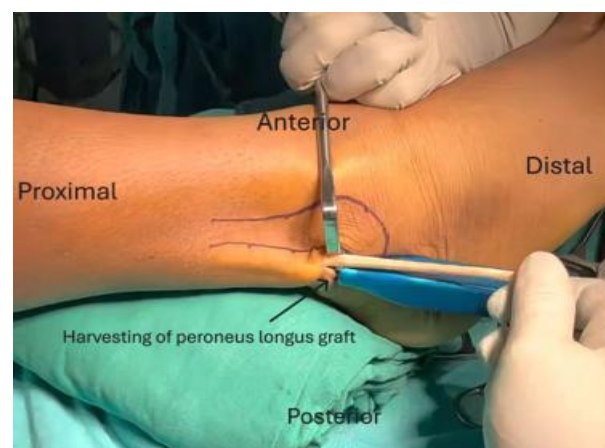
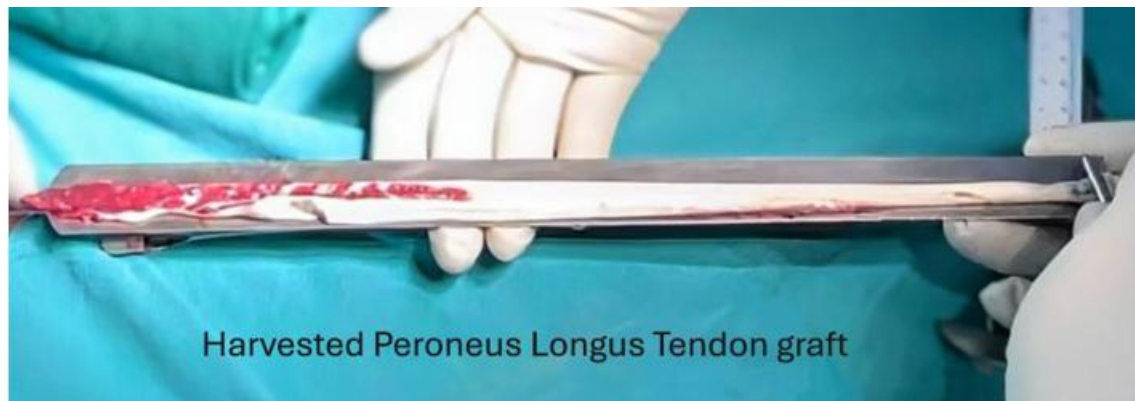

Figure 4



**Figure 5**

**Figure 1:** Peroneus longus tendon identification 2. Peroneus Longus and Peroneus Brevis identification 3. Excised Peroneus Longus tendon 4. Harvesting of Peroneus Longus tendon 5. Measuring of harvested Peroneus Longus tendon graft

### Tunnel Placement

**Femoral Tunnel-** The femoral tunnel was made first with the help of a femoral offset guide introduced via the anteromedial portal and placed at the 2 o'clock position in the left knee and 10 o'clock in the right knee. The guide wire was introduced, and reaming was initially performed with a 4mm reamer throughout the bone, followed by reaming with a size corresponding to the graft diameter. Loop ethibond was placed through the tunnel and secured.

**Tibial Tunnel-** A guide pin was inserted into the knee using a drill guide system, angled at 55° to the tibial shaft. The pin's tip was placed behind the anterior horn of the lateral meniscus and 7 mm anterior to the posterior cruciate ligament. The tunnel was then drilled using a cannulated drill bit according to the size of graft harvested.

### Graft Placement and Fixation

Ethibond loop was retrieved from the tibial side. Prepared Peroneus Longus graft with fixed loop endobutton was then pulled until the Endobutton passed through the outer femoral cortex, flipped over, and the adjustable loop was tightened to secure 15-25 mm of the graft within the femoral socket. Cyclical tensioning through repeated flexion and extension ensured the proper alignment of the graft and remove any kink. Arthroscopic visualization was done to confirm alignment and absence of impingement. Tension was applied to the Ethibond before securing the interference screw at the tibial end. The graft was assessed for impingement, and notchplasty was performed if necessary to alleviate any compression.

### Rehabilitation

In the immediate postoperative period, the patient was immobilized in a knee brace and limb elevation was given. Intravenous antibiotics were administered for 2 days post-surgery. Every patient had the same ACL rehabilitation regimen, which was to begin with 50–75% partial weight bearing with crutches and advance to full weight bearing with crutches and knee flexion up to 90 degrees by the end of the fourth week. By six weeks, patients were able to achieve full flexion and weight bearing without crutches. Return to sports activities was recommended only after six months. Patients were monitored postoperatively, 6 months, and 1 year, with

functional outcomes of the knee and ankle assessed at each follow-up.

### Statistical Analysis

Statistical analysis was performed using SPSS software (Version 24.0). Pre-operative and post-operative data were compared using the t-test and Chi-square test for inferential statistics. Descriptive statistics were presented as mean and standard deviation. A P-value of less than 0.05 was considered statistically significant.

### 3. Results

Our study consisted of 30 patients out of which 23 were male and 7 were female patients. Average age group in our study was 29.3 years with a range of 18 to 53 years. 21 patients had right sided injury while 9 patients had left side injury. The most common mode of injury in our study was road traffic accidents (RTA) (46.6%), followed by sports injuries (36.6%), as shown in **Table 1**.

**Table 1:** Clinical features of patients in study

Characteristics		No. of Patients
Age group	18-30	21(70%)
	30-40	5(16.7%)
	>40	4(13.3%)
Sex	Male	23(76.7%)
	Female	7(23.3%)
Laterality	Right	21(70%)
	Left	9(30%)
Mode of injury	RTA	14(46.7%)
	Sports	11(36.6%)
	Self Fall	5(16.7%)
Graft diameter	<8MM	3(10%)
	8-9MM	23(76.7%)
	>9 MM	4(13.3%)

The mean peroneus longus tripled graft diameter in our study was 8.63, with a range of 7.7 to 9.6 mm.

The Lachman test was used to assess knee joint stability, which showed grade 0 or no laxity in 27 cases at 12 months postoperatively, with grade 1+ laxity in 3 cases. A pivot shift test was reported negative in all cases at 12 months postoperatively.

Functional outcome of knee was assessed using IDKC and LYSOHLM TEGNER SCALE, which showed significant differences at 6 and 12 months when compared preoperatively. The mean IKDC score preoperatively was  $54.3 \pm 6.34$  and postoperatively at final follow-up was  $94.2 \pm 10.60$ . The mean Tegner-Lysholm score preoperatively was  $59.5 \pm 8.8$  and postoperatively was  $96.3 \pm 5.8$ . (Table 2)

**Table 2:** Comparison of preoperative and postoperative functional scores of knee

Score	Test Time	Mean $\pm$ SD	P Value
IDKC	Pre-Op	$54.3 \pm 6.34$	
	6 Months	$86.2 \pm 8.53$	<0.001
	12 Months	$94.2 \pm 10.60$	<0.001
Lysohlm Tegner	Pre-Op	$59.5 \pm 8.8$	
	6 Months	$87.67 \pm 7.36$	<0.001
	12 Months	$96.3 \pm 5.8$	<0.001

The impact of harvesting the PLT autograft on the ankle joint was assessed using the AOFAS and FADI scores. AOFAS score at final follow up was  $97.94 \pm 3.42$  as compared preoperatively to  $98.32 \pm 1.63$  while FADI score at 12 months was  $97.62 \pm 1.15$  as compared to  $98.08 \pm 2.85$  preoperatively (Table 3). Both were found not significant when compared preoperatively.

**Table 3:** Comparison of preoperative and postoperative functional scores of Ankle

Score	Test Time	Mean $\pm$ SD	P Value
AOFAS	Pre Op	$98.32 \pm 1.63$	
	6 Months	$94.1 \pm 2.32$	0.0634
	12 Months	$97.94 \pm 3.42$	0.0857
FADI	Pre Op	$98.08 \pm 2.85$	
	6 Months	$96.17 \pm 2.05$	0.0767
	12 Months	$97.62 \pm 1.15$	0.0843

In our study, two patients experienced superficial infections at the donor ankle site, which resolved with dressing and antibiotic treatment. None of the patients sustained any nerve injuries.

#### 4. Discussion

The human Knee comprises of 4 major ligaments, of which the most commonly injured ligaments is the anterior cruciate ligament (ACL). ACL injuries are most commonly seen in athletes, especially in sports that require sudden stops, directional changes, or jumping, such as soccer, basketball, and skiing<sup>10</sup>. Furthermore, road traffic accidents (RTA) can also result in ACL injuries, often due to high-impact collisions that cause the knee to twist or hyperextend.

Arthroscopic reconstruction of the injured anterior cruciate ligament (ACL) has emerged as the gold standard treatment method in modern medical practice. Various types of grafts have been utilized for ACL reconstruction, including autografts, allografts, and synthetic grafts.

Allografts offer advantages such as shorter operation time, as well as favorable cosmetic outcomes. However, they come with disadvantages, including high costs, the potential for delayed incorporation, risks of disease transmission, and the possibility of immunological reactions<sup>11</sup>.

Autografts have become the preferred choice for grafting due to their ease of availability and biological compatibility with the patient's own tissues. Several autograft options are available for ACL reconstruction, including Bone-Patellar Tendon-Bone Graft, Quadriceps Tendon Graft, Hamstring Tendon Graft and Peroneus Longus Tendon Graft<sup>12-13</sup>.

The Bone-Patellar Tendon-Bone (BPTB) graft is often regarded as one of the best options for ACL reconstruction due to its ability to facilitate strong bone-to-bone healing, leading to early recovery and enhanced stability. However, it also has certain disadvantages, including the potential for chronic quadriceps weakness, patellar chondromalacia, patellar fractures, tendon shortening, ruptures, and patellofemoral pain syndromes<sup>14</sup>.

Hamstring tendon grafts have become the preferred choice for many surgeons due to several advantages, including greater mechanical strength, reduced patellofemoral pain, and less loss of extension. Among the disadvantages of hamstring grafts are irregular graft diameter and donor site complications such as thigh hypotrophy and hypoesthesia or numbness brought on by injury to the saphenous nerve's infrapatellar branch. Furthermore harvesting hamstring graft in patients with concomitant MCL injury can lead to instability of knee joint<sup>15-16</sup>.

The potential drawbacks of the two primary autografts used in ACL surgery have led to a resurgence of interest in the peroneus longus tendon (PLT) graft as an alternative in recent times with multiple studies being conducted to evaluate the outcomes associated with this option. Several encouraging features have attracted surgeons to the PLT graft, including faster harvesting times, ease of harvest, consistent graft length and diameter, and favorable functional outcomes. Additionally, research indicates that the biomechanical strength of the harvested PLT is superior to both hamstring and bone-patellar tendon-bone (BPTB) grafts<sup>9</sup>.

The mean diameter of harvested peroneus longus graft in our study was 8.63, with range of 7.7 to 9.6 mm. Multiple studies have previously shown a correlation between graft diameter in ACL reconstruction and the need for revision surgery, concluding that grafts measuring 8 mm or less in diameter are associated with a higher relative risk of failure. In our study, only three patients had grafts smaller than 8 mm, indicating that the grafts harvested from the peroneus longus are of adequate size and more consistent<sup>17-18</sup>. Quinn et al in their study also found the mean diameter of the harvested PLT graft to be >8 mm<sup>19</sup>.

Functional outcome of knee assessed using IDKC and Tegner-Lysholm score showed excellent results at 1 year follow up in our study when compared preoperatively. Result of mean IKDC score pre-operative was  $54.3 \pm 6.34$  and post-operatively at 1 year follow up was  $94.2 \pm 10.60$ . Mean Tegner-Lysholm score pre-operative was  $59.5 \pm 8.8$  and post-operatively at 1 year follow up was  $96.3 \pm 5.8$ . It was similar to study done by Rhatomy et al<sup>20</sup>, kermoglu et al<sup>21</sup>, and Hossain et al<sup>22</sup>.

Donor ankle function in our study was found to be excellent as per FADI and AOFAS score at final follow up. Similar

finding was shown by Keyhani et al<sup>5</sup> and Rhatomy et al<sup>20</sup>. Otis et al<sup>23</sup> in their study concluded that peroneus brevis is a stronger evtor of foot than peroneus longus thus leading to preserved evtor function after harvesting peroneus longus graft. None of the patients in our study reported any adverse outcomes, including ankle instability, loss of motion, or nerve injury.

A viable primary graft for ACL reconstruction must meet several key criteria. These include faster and easy harvesting, consistent size and diameter for optimal outcomes, strong biomechanical properties, good functional results, and preservation of knee function and range of motion, along with minimal donor site morbidity. The peroneus longus tendon (PLT) demonstrates all of these qualities, making it a worthy candidate as a primary graft choice. However, long-term studies are still needed to evaluate the overall survival and revision rates of PLT grafts in ACL reconstruction.

Limitations- Our study had certain limitations, including a single center study, small sample size, a shorter follow-up period, and the lack of comparison between the PLT graft and other graft options.

Multicentric studies with larger sample sizes and extended follow-up periods are necessary to better understand the long-term complications of PLT graft harvesting on donor ankle function, as well as to assess graft rupture rates and survival duration.

## 5. Conclusion

This study confirms the Peroneus Longus Tendon as a viable autograft option for primary ACL reconstruction, demonstrating excellent postoperative knee function and minimal donor site morbidity. Future research should focus on long-term comparisons with conventional grafts to further establish its superiority.

## References

- [1] Rothrauff BB, Jorge A, de Sa D, Kay J, Fu FH, Musahl V: Anatomic ACL reconstruction reduces risk of post-traumatic osteoarthritis: a systematic review with minimum 10-year follow-up. *Knee Surg Sports Traumatol Arthrosc.* 2020, 28:1072-1084. 10.1007/s00167-019-05665-2
- [2] Lyman S, Koulouvaris P, Sherman S, Do H, Mandl LA, Marx RG: Epidemiology of anterior cruciate ligament reconstruction: Trends, readmissions, and subsequent knee surgery. *J Bone Joint Surg Am.* 2009, 91:2321-8. 10.2106/JBJS.H.00539
- [3] Pearsall IV, Albert W, Hollis JM, Russell Jr GV, Scheer Z: A biomechanical comparison of three lower extremity tendons for ligamentous reconstruction about the knee. *Arthrosc J Arthrosc Relat. Surg.* 2003, 19:1091-1096. 10.1016/j.arthro.2003.10.015
- [4] Christen B, Jakob RP: Fractures associated with patellar ligament grafts in cruciate ligament surgery. *J Bone Joint Surg Br.* 1992, 74:617-9. 10.1302/0301-620X.74B4.1624526
- [5] Frank CB, Jackson DW: The science of reconstruction of the anterior cruciate ligament. *J Bone Joint Surg Am.* 1997, 79:1556-76. 10.2106/00004623-199710000-00014
- [6] Keyhani S, Qoreishi M, Mousavi M, Ronaghi H, Soleymanha M: Peroneus Longus Tendon Autograft versus Hamstring Tendon Autograft in Anterior Cruciate Ligament Reconstruction: A Comparative Study with a Mean Follow-up of Two Years. *Arch Bone Jt Surg.* 2022, 10:695-701. 10.22038/ABJS.2022.59568.2938
- [7] Sasetyo DR, Rhatomy S, Pontoh LAP: Peroneus longus tendon: The promising graft for anterior cruciate ligament reconstruction surgery. *AP-SMART.* 2017, 9:25. 10.1016/j.asmart.2017.05.033
- [8] Anghong C, Chernchujit B, Apivatgaroon A, Chaijenkit K, Nualon P, Suchao-in K: The Anterior Cruciate Ligament Reconstruction with the Peroneus Longus Tendon: A Biomechanical and Clinical Evaluation of the Donor Ankle Morbidity. *J Med Assoc Thai.* 2015, 98:555-60.
- [9] Shi FD, Hess DE, Zuo JZ, et al.: Peroneus Longus Tendon Autograft is a Safe and Effective Alternative for Anterior Cruciate Ligament Reconstruction. *J Knee Surg.* 2019, 32:804-11. 10.1055/s-0038-1669951
- [10] Griffin LY, Albohm MJ, Arendt EA, et al.: Understanding and Preventing Noncontact Anterior Cruciate Ligament Injuries: A Review of the Hunt Valley II Meeting. January. 20052006, 34:1512-1532. 10.1177/0363546506286866
- [11] Barrett G, Stokes D, White M: Anterior cruciate ligament reconstruction in patients older than 40 years: allograft versus autograft patellar tendon. *Am J Sports Med.* 2005, 33:1505-12. 10.1177/0363546504274202
- [12] Fulkerson JP, Langeland R: An alternative cruciate reconstruction graft: the central quadriceps tendon. *Arthroscopy.* 1995, 11:252-254. 10.1016/0749-8063(95)90078-0
- [13] Macaulay AA, Perfetti DC, Levine WN: Anterior cruciate ligament graft choices. *Sports Health.* 2012, 4:63-8. 10.1177/1941738111409890
- [14] Bonamo JJ, Krinick RM, Sporn AA: Rupture of the patellar ligament after use of its central third for anterior cruciate reconstruction. A report of two cases. *J Bone Joint Surg Am.* 1984, 66:1294-1297.
- [15] Ahn JH, Lee SH: Risk factors for knee instability after anterior cruciate ligament reconstruction. *Knee Surg Sports Traumatol Arthrosc.* 2016, 24:2936-2942. 10.1007/s00167-015-3568-x
- [16] Figueroa D, Calvo R, Vaisman A, Campero M, Moraga C: Injury to the infrapatellar branch of the saphenous nerve in ACL reconstruction with the hamstrings technique: clinical and electrophysiological study. *Knee.* 2008, 15:360-363. 10.1016/j.knee.2008.05.002
- [17] Conte EJ, Hyatt AE, Gatt CJ, Jr, Dhawan A: Hamstring autograft size can be predicted and is a potential risk factor for anterior cruciate ligament reconstruction failure. *Arthroscopy.* 2014, 30:882-90. 10.1016/j.arthro.2014.03.028
- [18] Spragg L, Chen J, Mirzayan R, Love R, Maletis G: The effect of autologous hamstring graft diameter on the likelihood for revision of anterior cruciate ligament reconstruction. *Am J Sports Med.* 2016, 44:1475-81. 10.1177/0363546516634011

- [19] Peroneus Longus Tendon Autograft May Present a Viable Alternative for Anterior Cruciate Ligament Reconstruction. A Systematic Review Quinn, Matthew et al., *Arthroscopy*, Volume 40, Issue 4, 1366-1376.e1, April. 2024, 10.1016/j.arthro.2023.10.016
- [20] Rhatomy S, Hartoko L, Setyawan R, et al.: Single bundle ACL reconstruction with peroneus longus tendon graft: 2-years follow-up. *J Clin Orthop Trauma*. 2020, 11:332-6. 10.1016/j.jcot.2019.09.004
- [21] Kerimoglu S, Aynaci O, Saracoglu M, et al.: [Anterior cruciate ligament reconstruction with the peroneus longus tendon]. *Acta Orthop Traumatol Turc*. 2008, 42:38-43. 10.3944/aott.2008.038
- [22] Hossain GJ, Islam MS, Rahman Khan MM, et al.: A prospective study of arthroscopic primary ACL reconstruction with ipsilateral peroneus longus tendon graft: Experience of 439 cases. *Medicine*. 2023, 102:9-32943. 10.1097/MD.0000000000032943
- [23] Otis JC, Deland JT, Lee S, et al.: Peroneus brevis is a more effective evtor than peroneus longus. *Foot Ankle Int*. 2004, 25:242-6. 10.1177/107110070402500408