

# Surgical Management of Middle Third Clavicle Fracture In Adults by Cannulated Lag Screw

Dr. S. P. Rai<sup>1</sup>, Dr. R. S. Topwal<sup>2</sup>

<sup>1</sup>Associate Professor

Department of Orthopedics, Career Institute of Medical Sciences & Hospital, Lucknow (UP), India

<sup>2</sup>Assistant Professor

Department of Orthopedics, Career Institute of Medical Sciences & Hospital, Lucknow (UP), India

**Abstract:** Introduction: Clavicle fracture is a common traumatic injury around shoulder girdle due to its subcutaneous position. It is caused by either low- energy or high- energy impact. Fracture of the clavicle accounts for approximately 5 to 10% of all fractures and up to 44% of injuries to the shoulder girdle. About 80% of these fractures are in the middle third of the bone and less often in the lateral third (15%) and medial third (8%). Aims and Objectives: To study the role of open reduction and internal fixation in clavicular fractures by single Lag Screw Fixation as surgical procedures over middle 1/3 fracture clavicle, clinically evaluate the results, discuss merits and demerits of surgical procedures, and finally draw conclusions of overall study. Methodology: The present study was carried out from July 2012 to April 2014 at Department of Orthopedics, Career Institute of Medical Sciences & Hospital, Lucknow. During these period 28 patients of clavicular fractures at middle third region, Type 2 B1 and B2 was treated surgically by using Cannulated Lag Screw. Adult male and female patients above 18 years who require surgical intervention for displaced and comminuted fracture. Those with Lateral third and medial third fracture were excluded from present procedure. Results and Observations: we had 28 cases of middle third clavicle fracture which were fixed by single cannulated Cancellous Lag screw. Postoperatively patients were given only arm sling and from next day they were encouraged swing exercises. The functional outcome is assessed by Constant and Murley score. In this study most patients had excellent functional range in less than 8 weeks. For 8 patients with comminuted fracture, immobilization in Arm sling was preferred more than 8 weeks with gentle mobilization exercises. Clavicle fracture fixed with cannulated screw Lag fixation had fairly excellent functional outcome in term of recovery time and cost effective with fairly least complication. Conclusion: Clavicle fractures are usually treated conservatively but there are specific indications for which operative treatment is needed like comminuted, displaced middle third clavicle fractures and displaced lateral third clavicle fracture. In this study primary open reduction and internal fixation with Cannulated screws of fresh middle third clavicle fractures provides a more rigid fixation and does not require immobilization for longer periods. In this study, Dynamic compression was achieved by Lag effect provided by single cannulated Cancellous screw is strong and it does not gives excessive prominence through the skin as usually it is prominent when Plate is used. For displaced, comminuted middle third clavicle fracture Cannulated screws fixation and early mobilization gave excellent results. This method of fixation is easier to perform, cost effective, least chance of complications with good functional recovery.

**Keywords:** Lag fixation, cannulated screw, clavicle fracture, middle third displaced and comminuted

## 1. Introduction

Clavicle is the bony link from thorax to shoulder girdle and contributes to movements at shoulder girdle. Clavicle fracture is a common traumatic injury around shoulder girdle due to their subcutaneous position. It is caused by either low- energy or high- energy impact. Fracture of the clavicle accounts for approximately 5 to 10% of all fractures and up to 44% of injuries to the shoulder girdle. About 70% to 80% of these fractures are in the middle third of the bone and less often in the lateral third (12% to 15%) and medial third (5% to 8%). Fractures of the clavicle have been traditionally treated non-operatively. Although many methods of closed reduction have been described, it is recognized that reduction is practically impossible to maintain and a certain amount of deformity and disability is expected in adults<sup>1</sup>. In the past few years several publications have described about poor outcomes like mal union and nonunion (15%) after conservative treatment of severely displaced clavicular fractures.

## 2. Aims and Objectives

To study the role of surgical treatment by open reduction and internal fixation in clavicular fractures, using single Cannulated Cancellous screw as surgical procedures over mid third fracture clavicle, also clinically evaluate the results of surgical procedures over fracture clavicle. To discuss merits and demerits of the surgical procedures and finally draw conclusions of overall study.

## 3. Methodology

The present study was carried out from July 2012 to April 2014 at Orthopedics Department of Career Institute of Medical Sciences & Hospital, Lucknow. During this period 28 patients of middle third clavicle fractures fixation done surgically by using a single cannulated Cancellous screw.

**Inclusion criteria:** Adult male and female patients above 18 years who require surgical intervention according to Robinsons classification<sup>2</sup>- Type 2 B1( Displaced with simple or small fragment) and Type 2 B2( grossly

displacement and comminuted) middle third clavicle fracture were included for this study after taking written consent from them.

**Exclusion criteria:** Patients less than 18 years of age, Patients not willing for surgery, very old aged persons and Patients medically unfit for surgery were excluded. General information like name, age, sex, occupation and address were noted. Then a detailed history was elicited regarding mode of injury like fall on the shoulder, Road traffic accident, direct injury to shoulder and fall on outstretched hand. Enquiry was made to note site of pain and swelling over the affected clavicle. Past medical illness and family history were also recorded. General condition of the patients was examined for pallor, pulse rate and blood pressure. Respiratory and cardio vascular system were examined for any abnormalities .consent for surgery taken.

**Operative Method:** Patient was taken for surgery under GA, in supine position. A cushion was pushed underneath the fracture side shoulder .Longitudinal incision made along centering the fracture site, fracture exposed and 1.25mm Guide wire was passed from Inferio-medial to superior-lateral direction so as it to pass about one inch either side away from fracture line. Cannulated drill of 2.5mm was mounted over guide wire to drill both sides, and then fragment was reamed with 3.5 mm Tap. Insertion point was over drilled inferio-medially. Then one Cannulated screw(with core dia 2.5mm,thread dia 4mm,shaft dia2.7mm, cannulation1.35mm,head dia 5mm) with length variation from 50mm to 65mm length was used. The cannulated screw slowly threaded over guide wire. Fracture ends would approximate as this screw traverses-in, giving Lag effect at fracture ends (Fig.1). Few fractures had comminution at fracture site with large fragments. In these fractures, after Cannulated Screw insertion large fragments were approximated by encirclage wiring (Fig. 2 & Fig 3). Whereas those with small pieces were left as such by the side as graft. Shoulder Arm immobilizer was used post operation.

**Post Operative care:** Patients were kept nil orally for 4 to 6 hours post-operatively. Intravenous fluids were given as needed. Antibiotics were continued for 10 days. Analgesics and tranquilizers were given according to the needs of the patient. The operated upper limb was immobilized in an arm pouch for simple fractures and shoulder immobilizer as advised for comminuted fractures .Check x-rays were taken to study the alignment of fracture fragments. The wound was inspected at 3or 4th postoperative day. Suture removal was done on 10th postoperative day. Patients were discharged with the arm pouch.

Rehabilitation of the affected arm was started at the end of 2 weeks. Gentle pendulum exercises to the shoulder in the arm pouch were allowed from next morning. At 4 to 6 weeks gentle active range of motion of the shoulder was allowed but abduction limited to 80 degrees. At 6 to 8 weeks active range of motion in all planes were allowed.

**Follow up:** Regular follow up for every 4 weeks was done. Local examination of the affected clavicle for tenderness, instability deformity and shoulder movements were assessed (Fig 4). X-rays were taken at each follow up visits to know about progressive fracture union and implant position. Rehabilitation of the affected extremity were done according to the stage of fracture union and time duration from day of surgery. Patients were followed up till radiological union. The functional outcome was assessed by Constant and Murley3 score.

#### 4. Results and Observations

The present study consists of 28 patients of fresh fracture of the clavicle which were treated surgically with cannulated screw for middle third clavicle fracture between July 2012 to April 2014. Following observation are made in our study .In this present study there were 28 patients All the patients in middle third clavicle fracture were closed type and displaced fractures. There were no associated medical illnesses in any patient. In middle third clavicle fractures direct injury occurred due to fall on shoulder while slipped over floor outstretched hand and injured4(14%); fall from two wheeler in 8(29%), fracture due to road traffic accident 12(43%), due to fall of object over shoulder 3(11%)and 1(3%) by assault injury(Table 2).

Majority of the patients with middle third clavicle fracture i.e.16 patients (57%) were in the age group of 18-29.; while 8(29%) patients were between age group 30-49 and rest 4(14%) were over age of 50 years. The youngest patient was 18 years and oldest patient was 59 years. The average age of patient was35.65 years .In middle third clavicle fracture majority were males, 18 (64%) patients and 10((36%).females (Table 1). In this study for middle third clavicle fractures there were 16 patients (57%) of right sided and 10patients (36%) of left sided and 2(7%)patients has fracture of both clavicles.(Table3).In middle third clavicle fracture 8 patients (28%) had associated injuries, among them 2 patient (7%) had scapular body fracture and 3(11%) patients had associated rib fracture,2 (7%) had Head injury and one patient had multiple fractures All the Patients were immobilized in an arm pouch. we followed Robinson's AO classification, There were no type-1 (medial third)or Type3(lateral third) fracture. In type-2 middle third fracture type-2 B1 (displaced with simple or single butterfly fragment) occurred in 20patients (78%) and type -2 B2 (displaced with comminuted or segmental) fracture occurred in 8 (32%) patients(Table3). All the patients were fixed with single Cannulated Lag screw. Since 8(32%) patients had either comminution or fragment was large to approximate, after fixation with cannulated screw it was reinforced with encirclage wiring for better approximation.

**Duration of Union,** The fracture was considered to be united when clinically there was no tenderness, radiologically the fracture line was not visible and full unprotected function of the limb was possible .In middle third clavicle fracture 20 patients (72%) united at the end of 12 weeks. In 6 patients (21%) union occurred by 16 weeks while2(7%) patients required immobilization for

more than 18 wks due to large butterfly fragment at fracture site, which united at >20 weeks (Table 5). Removal of the Screw was advised at the end of 1 year. Patient was explained that screw can be removed as a day care procedure but most of them were satisfied or unwilling for second surgery as they were not having any problems. only 6 patients implant removal done One patient Screw was protruding proximally and distally at fracture site and patient was feeling disturbed, so removal was done by 9<sup>th</sup> months after operation (fig 5).

## 5. Complications

Surgical procedure fixation by single cannulated screw is relatively safe procedure. We did not had any major complications except few minor ones (Table 4). In middle third clavicle fixation 3 patients (10.7%) had hypertrophic skin scar and in 4 patients (14%) prominence of screw head medially, in one (3%) prominence occurred both proximally and distally and we removed this screw by the end of 9 months and arm sling given for 4 weeks. In this patient painful restriction of shoulder movements occurred and later it resolved with physiotherapy. No non union occurred. Superficial infection occurred in 3 patients (10.7%), which was treated with oral antibiotics for 5 days and in another 5 patient (18%) restriction of shoulder movements occurred due to associated scapular and multiple rib fractures where immobilization was extended for few more weeks, but it recovered after mobilization exercises of shoulder. The functional outcome is assessed by Constant and Murley score. In this study on 22 patients (79%) with middle third clavicle fracture treated with Lag screws had excellent functional outcome, good functional outcome in 4 patients (14%) and fair functional outcome in 2(7%) patient (Table 6).

## 6. Discussion

Clavicle fractures are usually treated conservatively. In a study conducted to analyze the results of conservative treatment by Hill et al<sup>1</sup>, Nordqvist et al.<sup>4</sup> and Robinson et al.<sup>5</sup> found poor results following conservative treatment of displaced middle third clavicle fracture. Multi centre trial by Canadian trauma society<sup>6</sup> compared result of conservative treatment with plating which was associated with implant failure. Other study by Conservative treatment of displaced lateral third clavicle fracture has higher rate of non union and residual shoulder dysfunction as showed by Edwards et al<sup>7</sup>. In this present study middle third clavicle fracture patients with Robinson Type-2 B1 (Displaced with simple or butterfly fragment) were more common and there were 20 patients (71%). Type-2 B2 (displaced with comminution) occurred in 8 patients (29%). In Bostman et al<sup>8</sup> study, also found that middle third clavicle fracture Robinson type-2 B1 was common in 78.64% patients whereas Robinson type-2 B2 occurred only in (21.36%) patients. In our study the middle third clavicle fractures were fixed with single Cannulated screw as Lag fixation and no plate was used. It provides stable fixation at fracture site and unlike Plate it does not require pre contouring. With our fixation there is minimal tissue trauma. Since screw head is deeply secured inferio-medially, no protuberance as is with plate and least chance

of loosening. Screw fixation is very cost effective as compared to plate. In this study majority of the middle third clavicle fracture 20 patients (72%) united at the end of 12 weeks. In 4 (10%) patients fracture took longer period to unite. It was due to large butterfly fragment at fracture site which united by 16-20 weeks. There were no non-union. Lazarus MD<sup>9</sup> stated radiological union occurred approximately between 6 to 12 weeks. In Kao et al<sup>10</sup> series union occurred after an average period of 4 months. Bostman<sup>8</sup> series had similar union. In our study 72% middle third clavicle fracture fixed with Lag screw united by 12 weeks while rest took 4 to 6 weeks more period depending upon comminution at fracture site.

## 7. Conclusion

Clavicle fractures are usually treated conservatively but there are specific indications for which operative treatment is needed like comminuted, displaced middle third clavicle fractures.

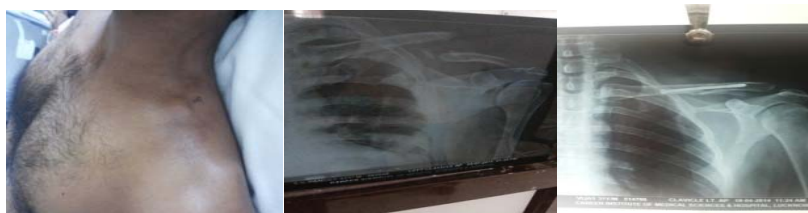- Among the fixation methods intra medullary fixation by K-wire do not control rotation so they require longer period of immobilization till union.
- Plating at mid third fracture requires pre contouring and chance of soft tissue trauma and loosening of implant is more, also cosmetically unacceptable
  - In this study primary open reduction and internal fixation with Cannulated screw fixed with Lag effect in fresh middle third clavicle fractures, provides a more rigid fixation and does not require immobilization for longer periods.
  - In this study Lag screw fixation provide stable fixation without disturbing blood supply due to minimal tissue handling and blood supply preservation due to placement of Lag screw inside medullary cavity of fractured clavicle.
- This does not require pre contouring like plate nor there is chance of loosening as often happens with plate fixation
- All the fractures united and there were no non union or major complications with fixation by Single cannulated screw.
- This method of fixation has been performed with small sample size. Further evaluation and Modification is expected in due course with broader perspective, to be accepted as standard method of mid third clavicle fixation.

## Bibliography

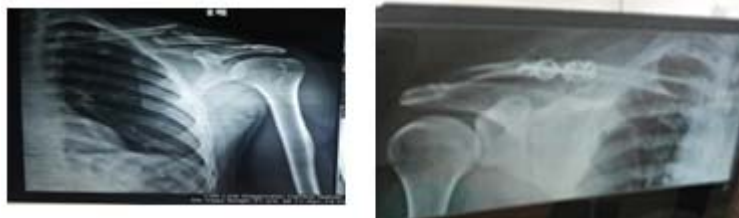- [1] Hill JM, Mc Guire MH, Crosby LA. Closed treatment of displaced middle third fractures of the clavicle gives poor results. *J Bone Joint Surgery (Br)*, 1997; 79:537-540
- [2] Robinson CM. Fractures of the clavicle in the adult. Epidemiology and classification's *Bone Joint Surgery (Br)*, 1998; 80: 476-484.
- [3] Constant CR, Murley AHG. A clinical method of functional assessment of the shoulder. *Clinical Orthopaedics and Related Research*. 1987; 214: 160-164.

- [4] Nordqvist A, Petersson CJ, Redlund-Johnell I. Mid clavicular fractures in adults: end result study after conservative treatment. *J Orthop Trauma*, 1998 ; 12 : 572-576
- [5] Robinson CM, Court Brown CM, McQueen MM, Walkefield AE. Estimating the risk of non union following non operative treatment of a clavicular fracture. *J Bone Joint Surgery (Am)*, 2004; 86:1359-1365.
- [6] Canadian Orthopaedic Trauma Society. Non operative treatment compared with plate fixation of displaced mid shaft clavicular fractures. A multicenter randomized clinical trial. *J Bone Joint Surg Am*. 2007; 89 A: 1–10.
- [7] Edwards DJ, Kavanagh TG, Flannery MC. Fractures of the distal clavicle a case for fixation. *Injury*, 1992; 23: 44-46.
- [8] Bostman O, Manninen M, Pihlajamaki H. Complications of plate fixation in fresh displaced mid clavicular fractures. *J Trauma*, 1997; 43:778-783
- [9] Lazarus MD. Fractures of the Clavicle. Chapter-26, In: Buchholz RW and Heckman JD, editors, *Rockwood and Green's fractures in Adults*, 5th edition, Philadelphia: Lippincott Williams and Wilkins, 2001; 1041-1078.
- [10] Kao FC, Chao E K, chen CH, Yu SW, Chen CY, Yen CY. Treatment of distal clavicle fracture using Kirschner wire and tension band wires. *J.Trauma*, 2001; 51: 522-525.
- [11] Kelly L. Vander Have, MD, Aaron M. Perdue, MD, Michelle S. Caird, MD, and Frances A. Farley, MD. Operative versus Non operative Treatment of Mid shaft Clavicle Fractures in Adolescents *J PediatrOrthop* 2010; 30:307–312).
- [12] McKee MD, Pedersen EM, Jones C, et al. Deficits following non operative treatment of displaced mid shaft clavicular fractures. *J Bone Joint Surg Am*. 2006; 88A:35–40

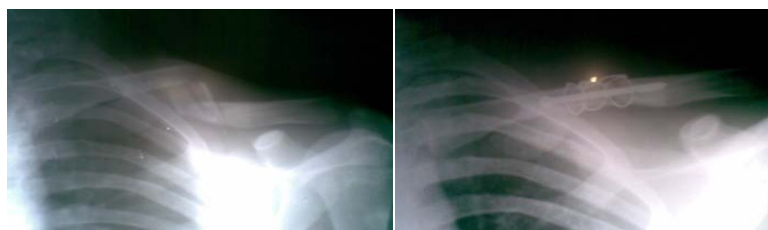**Clinical Photograph**



**Figure 1:** Mid third fracture clavicle fixed with lag screw.(Type2 B1)



**Figure 2:** Comminuted mid third clavicle fracture with large intermediate fragment fixed with cannulated screw and encirclage wire(Type2 B2)



**Figure 3:** Communitated fracture mid third Clavicle fix with single cannulated screw and reinforced with three encirclage wiring





Figure 4: Post operation --showing full range of motion

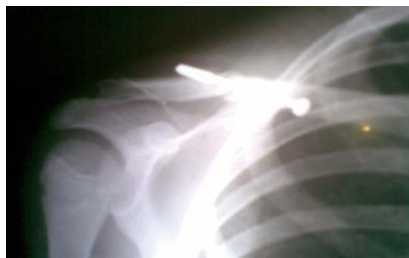

Figure 5: Showing cut through of screw and collapse at fracture side. Sling immobilization continued and fracture united

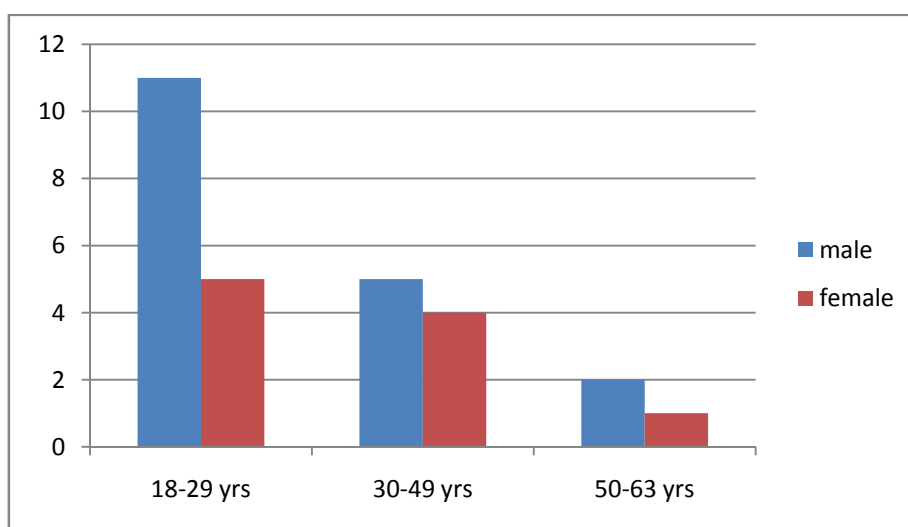


Table 1: Age and Sex distribution of mid1/3 Clavicle fracture

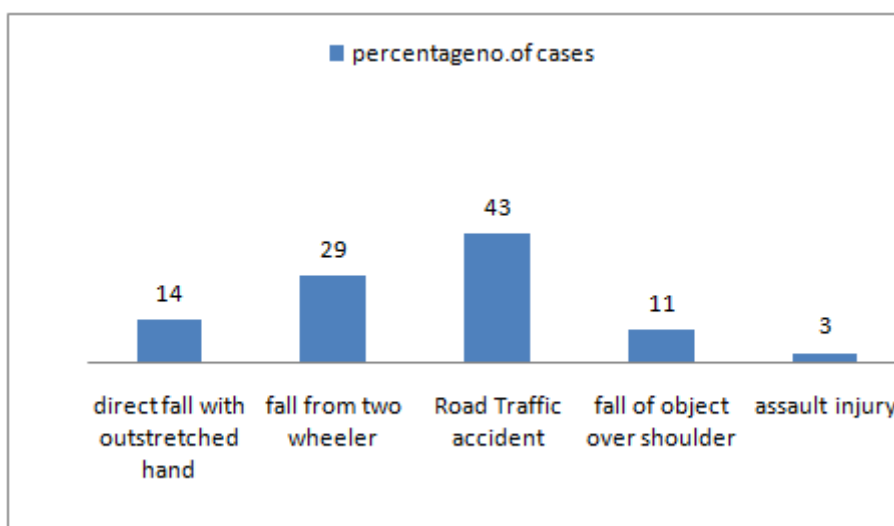
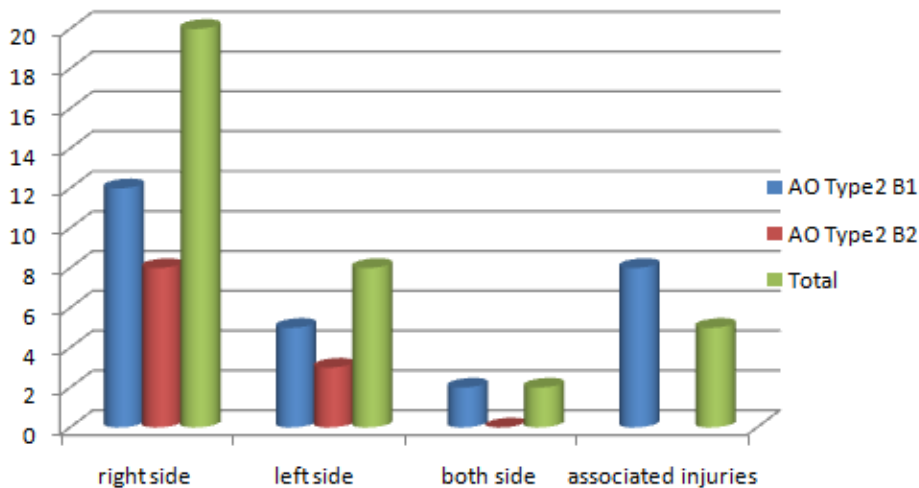
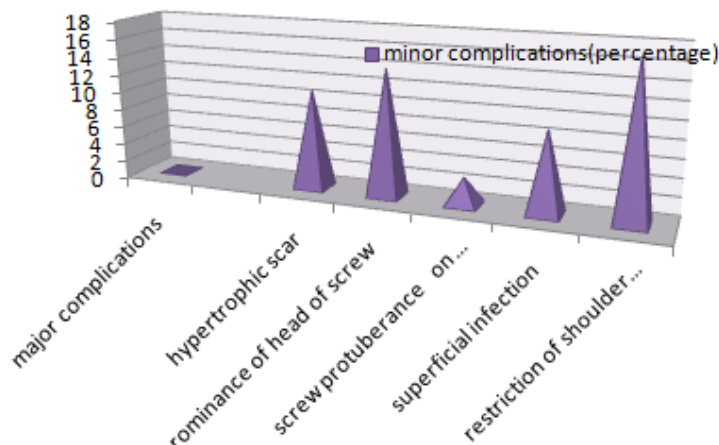


Table 2: Showing Mode of Injury

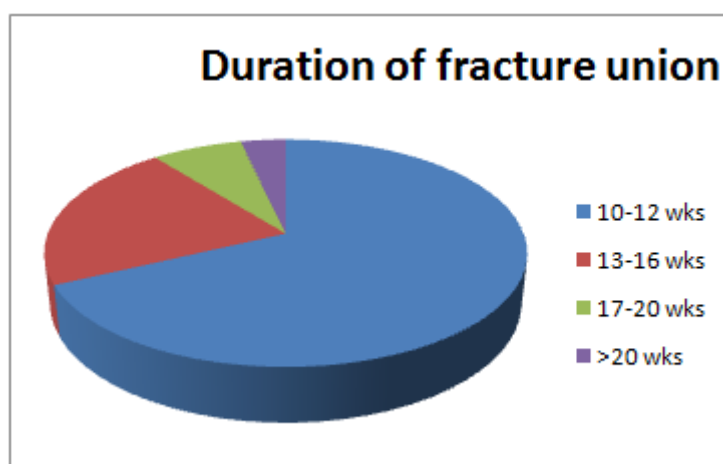


**Table 3:** Distribution of type AO fracture (Robinson's Classification) and its site



**Major complications-nil**  
**Minor complications(16 cases)**

**Table 4:** Complications following Lag Fixation



**Table 5:** Showing duration of fracture union.

**Table 6:** Range of Motion of shoulder after surgery

Full movement	22(79%)
Terminal restriction of abduction/rotation	4(14%)
Restriction of all movements	2(7%)