

Sudden Sensorineural Hearing Loss in a Hypertensive and Diabetic Patient

Dr. Bhanukumar M¹, Dr. Prakash², Dr. Subhash Chandra³, Dr. Ashok P⁴, Dr. Saivivek V⁵

¹Associate Professor, Department of General medicine JSS Hospital, Constituent of JSS University Mysore, India

²Professor, Department of ENT JSS Hospital, Constituent of JSS University Mysore, India

³BJ Professor and Unit Chief, Department of General medicine JSS Hospital, Constituent of JSS University Mysore, India

⁴Assistant Professor, Department of General medicine JSS Hospital, Constituent of JSS University Mysore, India

⁵Post Graduate, Department of General medicine JSS Hospital, Constituent of JSS University Mysore, India

Abstract: Sudden bilateral hearing loss in a hypertensive and diabetic, though a rare occurrence is a known one. We hereby present a case of a 60 year old woman with uncontrolled diabetes and hypertension with sudden bilateral hearing loss.

Keywords: Sudden bilateral hearing loss in a hypertensive and diabetic

1. Introduction

Sudden sensorineural hearing loss (SSNHL) is commonly defined as sudden hearing impairment of more than 30dB across three contiguous frequencies in <3 days¹⁻⁵. It affects an estimated 5 to 20 per 100000 persons per year. Previous systematic review's suggested that viral infection, vascular impairment, immune mediated mechanisms and inner ear & central nervous system infections are the most commonly known causative factors and a few cases are idiopathic⁶.

2. Case Report

A 60-year-old lady patient presented with sudden onset of bilateral hearing loss. She was apparently fine 1 day back when she developed sudden onset of bilateral hearing loss. Patient was a known case of uncontrolled hypertension and diabetes on treatment. Patient had no history of any trauma, ear discharge, and any symptoms related to hearing difficulty in the past. Patient does not give any history of fever or rash prior to this episode. Patient has no history of joint pains.

Patient was morbidly obese with a heart rate of 80 beats per minute, regular and equally felt in all the peripheries. Her BP was 180/110 in right arm supine position and no variation on the left arm or on standing. Patient had no pallor, icterus, cyanosis, lymphadenopathy and edema. Patient's fundus showed non-proliferative diabetic retinopathy.

Patient's complete blood counts, renal function tests, urine microscopy, were within the normal limits

Her fasting glucose was 306mg/dl, post prandial was 256 with a HBA1c of 9%. Patient's audiogram showed bilateral profound hearing loss (Figure 1, 2). The only finding in her ENT exam was Rinne's test being negative, decreased Absolute bone conduction test on either side and Weber's was centralised. CT and MRI of brain and temporal bones

showed bilateral minimal periventricular ischemic changes and lacunes in bilateral corona radiata, centrum semi ovale and Fronto- parietal white matter .

Patients Brainstem evoked potentials proved Sensorineural hearing loss (Figure 3,4) .We initiated her on steroids (methyl prednisolone for 5 days at a dosage of 500 mg /day followed by oral predisone for 3 weeks)and controlled her diabetes and hypertension but found no recovery during her follow up for 3 continuous months in her hearing status. She was then put on hearing aid trial and was advised cochlear implants.

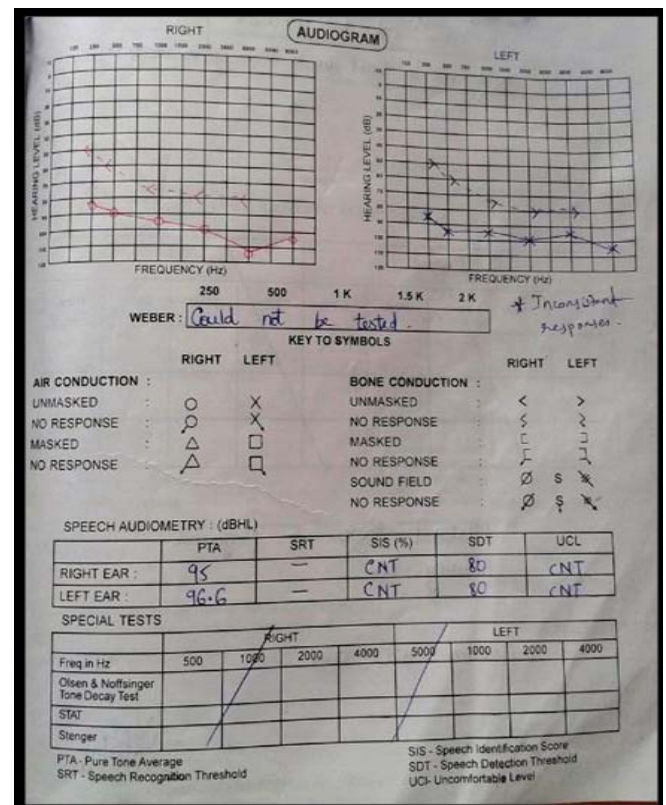


Figure 1

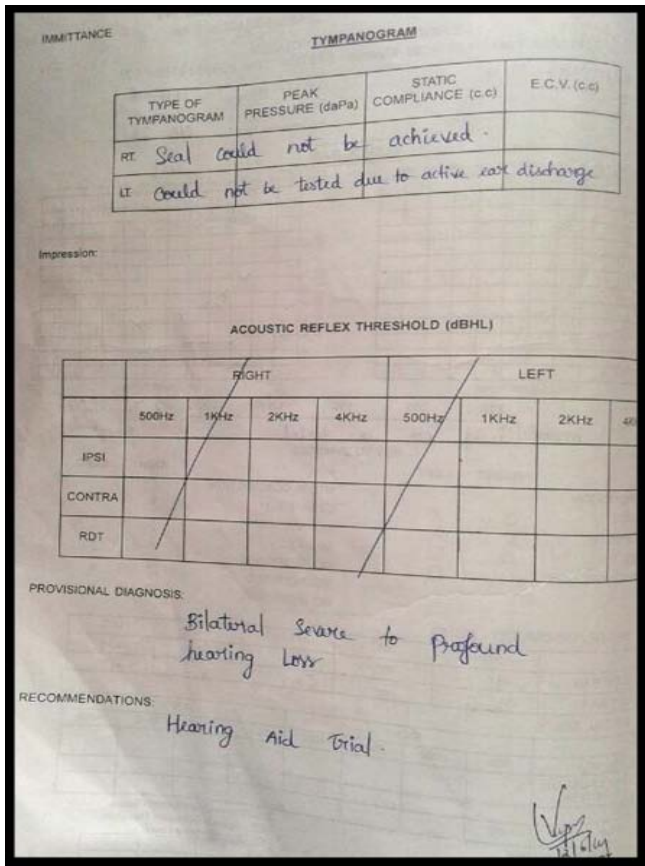


Figure 2

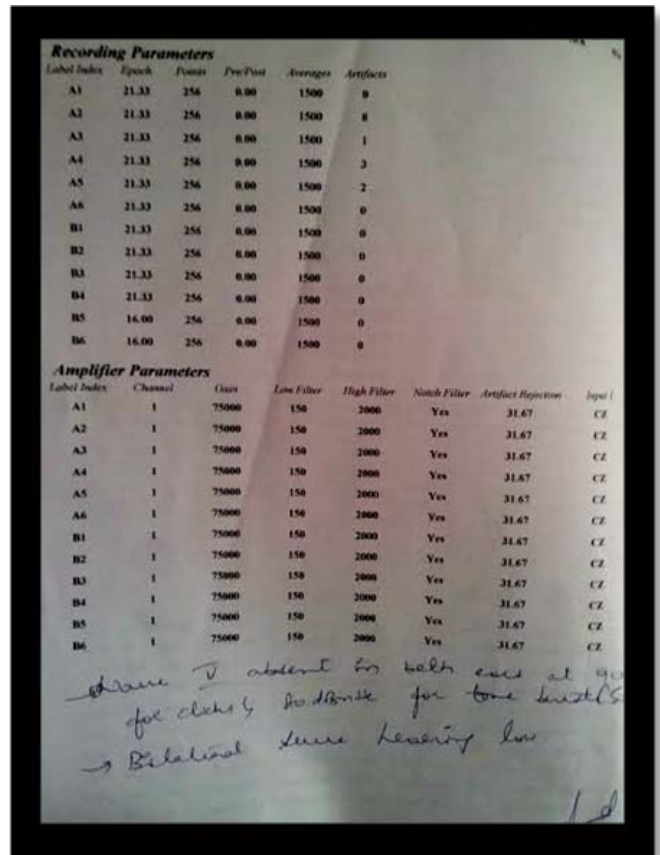


Figure 4

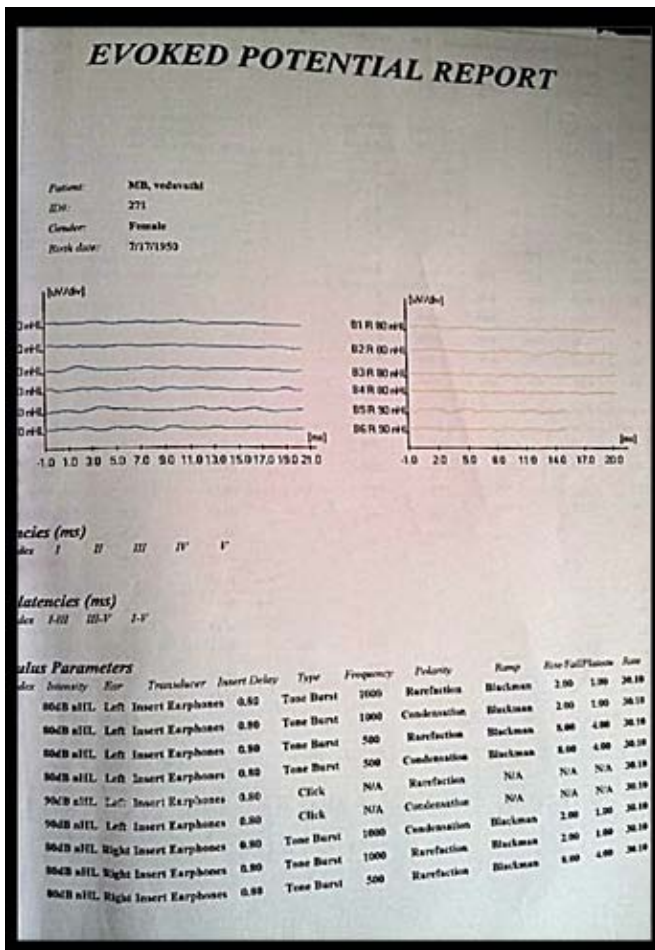


Figure 3

3. Discussion

Interruption of the vascular blood supply to the cochlea has long been speculated as an etiology for SSNHL. The inner ear's reliance on blood supply from the labyrinthine artery a branch of anterior inferior cerebellar artery and the absence of collateral arterial blood flow puts the labyrinth at significant risk from an ischemic event. Thrombosis, hemorrhage, and vasospasm are possible mechanisms leading to disruption of inner ear arterial flow⁷.

Evidence to support this etiologic theory is present in several studies. Tagaya et al.'s study looking at three-dimensional, fluid-attenuated inversion recovery of magnetic resonance imaging (MRI) findings in patients with SSNHL reported high signals in the affected inner ear of patients with sudden deafness 4hours after intravenous gadolinium injection, which may reflect minor hemorrhage or a disrupted blood-labyrinthine barrier⁸. The acute and sudden presentation of SSNHL is similar to the presentation of other acute ischemic events such as myocardial infarction, amaurosis fugax, and cerebro vascular events. Studies have examined the relationship between SSNHL and other acute ischemic events. Lee et al. found that four out of 12 patients presented with a cerebral ischemic event within 1 day to 2 months after developing SSNHL. Lin et al.'s study found that the stroke risk among SSNHL patients was 1.6 times higher than control patients within 5 years after hospitalization for an acute SSNHL episode, and half of these events occurred more than 2 years after the onset of SSNHL. As the stroke risk among SSNHL patients appears to be higher than in control patients, it becomes imperative to address and

modify their medical cardiovascular risk factors after SSNHL has already occurred⁹.

4. Conclusion

There is contradictory evidence on a vascular etiology of SSNHL in the literature. Many acquired or inherited cardiovascular risk factors were found to have a positive association with SSNHL⁹. Our perspective in this patient is that both uncontrolled hypertension and diabetes collectively were responsible for this acute event.

Reference

- [1] Vakkalanka S, Ey E, Goldenberg RA. Inner ear hemorrhage and sudden sensorineural hearing loss. *Am J Otol* 2000; 21:764–765?
- [2] Loughan S. Management of sudden sensorineural hearing loss: a consultant survey. *J Otolaryngol* 2000; 114:837–839.
- [3] Wilson WR. The relationship of the herpesvirus family to sudden hearing loss: a prospective clinical study and literature review. *Laryngoscope* 1986; 96:870–877.
- [4] Berrocal JRG, Camacho RR, Portero F, Vargas JA. Role of viral and *Mycoplasma pneumoniae* infection in idiopathic sudden sensorineural hearing loss. *Acta Otolaryngol* 2000; 120:835–839.
- [5] Fitzgerald DC, Mark AS. Sudden hearing loss: frequency of abnormal findings on contrast-enhanced MR studies. *AJNR Am J Neuroradiol* 1998; 19:1433–1436.
- [6] Chau JK, Lin JRJ, Atashband S, Irvine RA, Westerberg BD. Systematic review of the etiology of adult sudden sensorineural hearing loss. *Laryngoscope* 2010; 120:1011–1021.
- [7] Tagaya M, Teranishi M, Naganawa S, et al. 3 Tesla magnetic resonance imaging obtained 4 hours after intravenous gadolinium injection in patients with sudden deafness. *Acta Otolaryngol* 2010; 130:665–669.
- [8] Lee H, Sohn SI, Jung DK, et al. Sudden deafness and anterior inferior cerebellar artery infarction. *Stroke* 2002; 33:2807–2812.
- [9] Systematic Review and Meta-Analysis of the Risk Factors for Sudden Sensorineural Hearing Loss in Adults, *Laryngoscope*, 122:624–635, 2012