

# Morphometric Analysis of Superior Articulating Surface of Talus

Dr. Shishirkumar<sup>1</sup>, Dr. Satheesha Nambiar<sup>2</sup>, Dr. Arunachalam Kumar<sup>3</sup>, Dr. Girish V. Patil<sup>4</sup>

<sup>1</sup>Assistant Professor, Department of Anatomy, DM- Wayanad Institute of Medical Sciences, Meppadi, Wayanad, Kerala, India

<sup>2</sup>Professor of Anatomy at KMCT Medical College, Associate Professor at Vydehi Institute of Medical Sciences, Bangalore, India

<sup>3</sup>Head, R&D, K.S.Hegde Medical Academy, Mangalore, India

<sup>4</sup>Associate Professor, Department Of Anatomy, DM-WIMS Meppadi, Kerala, India

**Abstract:** Talocrural joint is major weight bearing joint of the body, since human is the only known obligate bipedals<sup>1</sup>. Therefore the body weight is transmitted to the ground through the two lower limbs. So some great features have been evolved in humans to keep the body upright. And talus is a single bone which takes the weight of the whole body. Study is done using 30 Tali (15 right sides and 15 Left sides). Measurements were similar on both sides. The measurements were lower when compared to one study showing the racial difference.

**Keywords:** Bipedals, Evolved, Racial, Talocrural joint, Tali.

## 1. Introduction

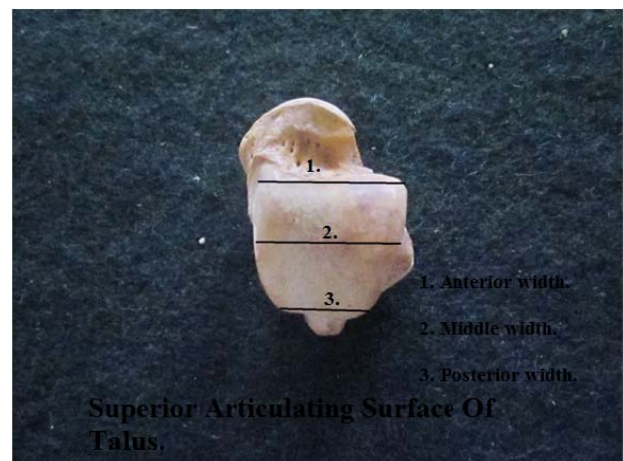
The talocrural joint is a major weight bearing joint of the body. The weight of the body is transmitted from the tibia and fibula to the talus which distributes the weight anteriorly and posteriorly within the foot. One sixth of the static load of the leg is carried by the fibula at the tibiofibular joint<sup>2</sup>. The passive stability depends on the contour of the articular surfaces, the integrity of the collateral ligaments, the integrity of the distal tibiofibular ligaments, the reticular system around the ankle and the crossing and attached tendon tunnels<sup>3</sup>. The lower end of tibia along with its medial malleolus and the lateral malleolus of the fibula form a deep recess to accommodate the body of talus. Ankle is one of the most frequently injured joint<sup>4</sup> and very limited amount of studies is available on morphometry of the superior articular surface of talus which will help in the reconstruction surgeries and in the manufacture of implants in south Indians.

## 2. Material & Methods

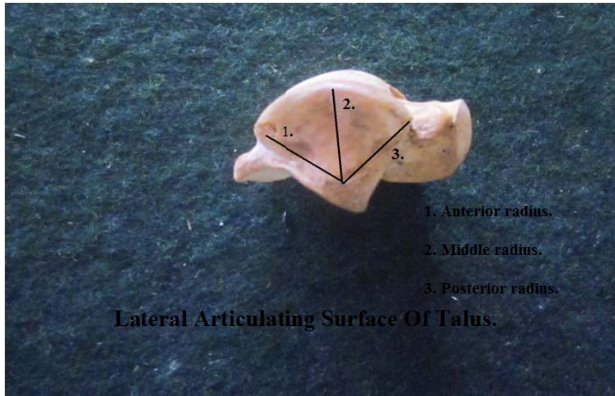
This study is done in the department of Anatomy K.S.Hegde Medical Academy, Deralakatte, Mangalore by using 30 Tali (15 right sides and 15 Left sides). The measurements that were taken on the superior articulating surface are, medial side length, lateral side length, central length, anterior width, central width, posterior width, lateral side: central radius, lateral side: posterior radius, medial side: anterior height.



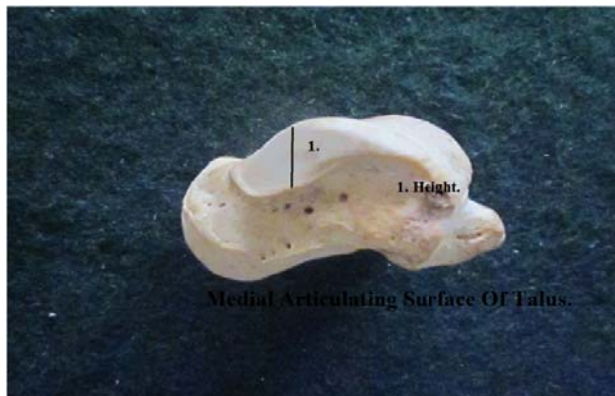
**Image 1:** Length measurements of superior articulating surface of talus taken at different levels.



**Image 2:** Width measurements of superior articulating surface of talus taken at different levels.



**Image 3 (left):** Measurements of lateral articular surface of talus taken at different levels.



**Image 4 (right):** Measurements of medial articular surface of talus taken at different levels.

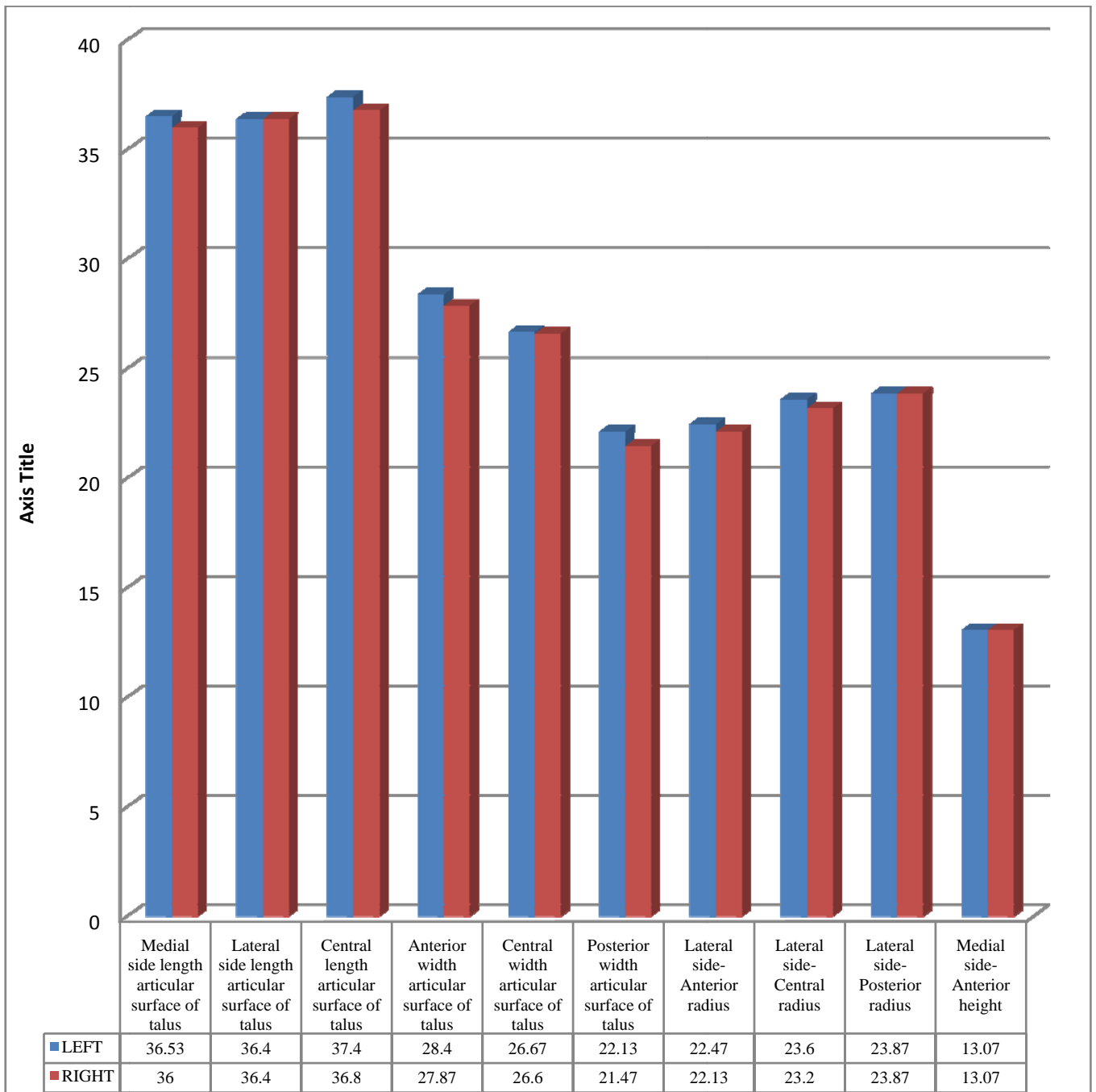
All the measurements were taken using a thread and digital calipers.

### 3. Observation and Results

#### Morphometry of Articular Surface in Talus (Dry Bone)

**Table 1:** Morphometry of each side in dry talus

	SIDE	Mean	Std. Deviation	P Value
Medial side length	LEFT	36.53	3.35	0.654
	RIGHT	36	3.09	
Lateral side length	LEFT	36.4	3.18	1
	RIGHT	36.4	2.41	
Central length	LEFT	37.4	2.41	0.486
	RIGHT	36.8	2.24	
Anterior width	LEFT	28.4	1.72	0.347
	RIGHT	27.87	1.30	
Central width	LEFT	26.67	1.87	0.924
	RIGHT	26.6	1.92	
Posterior width	LEFT	22.13	1.68	0.288
	RIGHT	21.47	1.68	
Anterior radius	LEFT	22.47	1.30	0.437
	RIGHT	22.13	0.99	
Central radius	LEFT	23.6	1.24	0.355
	RIGHT	23.2	1.08	
Posterior radius	LEFT	23.87	1.24	1
	RIGHT	23.87	0.99	
Anterior height	LEFT	13.07	1.03	1
	RIGHT	13.07	0.88	
Table No.1				



Graph No. 1: Comparison in the morphometry of different sides in the articulating surfaces of the dry talus. X-axis: Components to be measured. Y-axis: measurement in mm.

Irrespective of the side to which the bone belongs, the mean values of the length of superior trochlear surface of talus on the medial, lateral and central part are 36.26 mm, 36.4 mm and 37.1 mm. The mean values of the width of superior trochlear surface of talus on the anterior, central and posterior part are 28.13 mm, 26.63 mm and 21.8 mm. The mean values of the anterior, middle and the posterior radius on the lateral articulating surface are 22.3 mm, 23.4 mm and 23.8 mm. The mean value of the anterior height on the medial side is 13.06 mm.

On the right side, the mean length measurements are 36 mm, 36.4 mm and 36.8 mm. The mean width measurements are 27.87 mm, 26.6 mm and 21.47 mm. The mean radius measurements are, 22.13 mm, 23.2 mm and 23.87 mm. The mean height value is 13.07 mm

On the left side, the mean length measurements are 36.53 mm, 36.4 mm and 37.4 mm. The mean width measurements are 28.4 mm, 26.67 mm and 22.13 mm. The mean radius measurements are 22.47 mm, 23.6 mm and 23.87 mm. The mean height value is 13.07 mm.

#### 4. Discussion

Irrespective of the side to which the bone belongs, the mean values of the length of superior trochlear surface of talus on the medial, lateral and central part are 36.26 mm, 36.4 mm and 37.1 mm. The mean values of the width of superior trochlear surface of talus on the anterior, central and posterior part are 28.13 mm, 26.63 mm and 21.8 mm. The mean values of the anterior, middle and the posterior radius on the lateral articulating surface are 22.3 mm, 23.4 mm and

23.8 mm. The mean value of the anterior height on the medial side is 13.06 mm.

The length is almost similar throughout, though the lateral side is little more than lengthier than the other side measurements. From the above measurements it is clear that the articular surface is wider in front and narrows posteriorly. The lateral articular surface forms an arc of a circle because the radius in different regions is almost similar in length.

On the right side, the mean length measurements are 36 mm, 36.4 mm and 36.8 mm with a standard deviation of 3.094 mm, 2.414 mm and 2.242 mm. The mean width measurements are 27.87 mm, 26.6 mm and 21.47 mm with a standard deviation of 1.302 mm, 1.92 mm and 1.685 mm. The mean radius measurements are, 22.13 mm 23.2 mm, and 23.87 mm with a standard deviation of 0.99 mm, 1.082 mm and 0.99 mm. The mean height value is 13.07 mm, with a standard deviation of 1.033 mm.

On the left side, the mean length measurements are 36.53 mm, 36.4 mm and 37.4 mm with a standard deviation of 3.357 mm, 3.18 mm and 2.414 mm. The mean width measurements are 28.4 mm, 26.67 mm and 22.13 mm with a standard deviation of 1.724 mm, 1.877 mm and 1.685 mm. The mean radius measurements are 22.47 mm, 23.6 mm and 23.87 mm with a standard deviation of 1.302 mm, 1.242 mm and 1.246 mm. The mean height value is 13.07 mm, with a standard deviation of 0.884 mm.

The measurements on both sides are similar. According to the study by Rosdi Daud et al.<sup>5</sup> on three dimensional morphometric study of the trapezium shape of the trochlear tali, the anterior width and the posterior width was measured in 99 participants (49 females and 50 males).

The mean anterior width was found to be 32.36 mm with a standard deviation of 2.36 mm and a range of 25.56 mm to 37.74 mm in males. In females, it was 28.38 mm with a standard deviation of 1.68 mm and a range from 25.11 mm to 32.39 mm.

The posterior mean width was measured to 26.31 mm with a standard deviation of 2.07 mm and a range of 20.88 mm to 31.21 mm in males. In females, the mean width was found to be 22.98 mm with a standard deviation of 1.63mm and the range from 19.97 mm to 26.53 mm.

On the right side, the mean anterior width was measured to be 30.47 mm with a standard deviation of 2.8 mm. On the left side, it was measured to be 30.32 mm with a standard deviation of 2.93 mm.

On the right side, the mean posterior width was measured to be 24.92 mm with a standard deviation of 2.37 mm. On the left side, it was measured to be 24.39 mm with a standard deviation of 2.61 mm.

The measurements are lower when compared. It may be because of the population difference. In the study of ankle morphometry on 3D-CT images by Andrea Hayes et al.<sup>6</sup> in 21 subjects (10 females and 11 males), the mean width on the anterior part was 29.9 mm with a standard deviation of 2.6

mm, in the middle the mean width in the middle measured to be 27.9 mm with a standard deviation of 3 mm and on the posterior part it measured 25.2 mm with a standard deviation of 3.7 mm. The study is in agreement with the study of Andrea Hayes et al.<sup>6</sup>

## 5. Conclusion

Morphometry of articular surface in talus (dry bone): The lateral length measurement is higher than the other length measurements. Articular surface is wider in front and narrows posterior. The measurements on both sides are similar. This study will help in the reconstruction surgeries and in the manufacture of implants in south Indians.

## Acknowledgment

The present study is based upon the Dissertation work done by Dr. Shishirkumar under the guidance of Dr. Satheesha Nambiar. It would be impossible to complete the work without the help of Dr. Arunachalam Kumar in the Dept. of Anatomy, K.S.Hegde Medical Academy, Mangalore, Nitte University.

## References

- [1] DeSilva. J.M. Functional morphology of the ankle and the likelihood of climbing in early hominins. 2009; 106(16): 6567-6572. doi/10.73/pnas.0900270106.
- [2] Lambert KL. The weight bearing function of the fibula. A strain gauge study. J Bone Joint Surg Am. 1976; 53 (3): 507.
- [3] McCullough CJ, Burge PD. Rotary stability of the load bearing ankle. An experimental study. J Bone Joint Surg Br. 1980; 62(4): 460.
- [4] Bruce D. Beynon, Darlene F, Murphy, Denise M. Alosa Predictive Factors for Lateral Ankle Sprains. J Athl Train. 2002; 37(4): 376-380.
- [5] Rosdi Daud, Mohammed Rafiq Abdul Kadir, Sudin Izman, Amir Putra Md Saad, Muhammad Hisyam Lee, Aminudin Che Ahmad. Three-dimensional morphometric study of the trapezium shape of the trochlea tali. The journal of foot & ankle surgery 2013; 1-6.
- [6] Andrea Hayes, Yuki Tochigi, Charles L. Saltzman. Ankle morphometry on 3d-ct images. Iowa Orthop J. 2006; 26: 1-4.

## Author Profile



**Dr. Shishirkumar** has completed his MBBS from KLE'S JNMC Belgaum and has completed his M.D in Anatomy from K. S. Hegde Medical Academy, Deralakatte, Mangalore. He is presently working as an Assistant Professor in the Department Of Anatomy, DM-WIMS Meppadi, Kerala.



**Dr. Satheesha Nambiar** is presently a Professor of Anatomy at NITTE UNIVERSITY. Was a Professor of Anatomy at KMCT Medical College, Associate Professor at Vydehi Institute

of Medical Sciences, Bangalore.



**Dr. Arunachalam Kumar** presently heads the R&D in K. S. Hegde Medical Academy, Mangalore. He is also a Professor in Anatomy in K. S. Hegde Medical Academy Mangalore. He is India's most Eccentric Genius and he even has a name in the Limca book of records.



**Dr. Girish V Patil** has completed his MBBS from KIMS Hubli and has completed his M.D in Anatomy from VIMS Bellary. He has also finished his DNB Anatomy. He is presently working as an Associate Professor in the Department Of Anatomy, DM-WIMS Meppadi, Kerala.