

Treatment of Olecranon Fracture with Locking Compression Plate

Amit Agrahari¹, S. N. Chishti², A. Mahendrasingh³, Snehasis Datta⁴, Vinil Paul⁵

^{1,2,3,4,5} Department of Orthopaedics, Regional Institute of Medical Sciences, Imphal, Manipur, India

Abstract: ***Aim-** To know the outcome of Treatment of Olecranon Fracture with Locking Compression Plate in Regional Institute of Medical Science, Manipur, Imphal, India. **Introduction:** Olecranon fractures represent approximately 10% of all fractures around the elbow and can be caused either by direct trauma or by indirect trauma. **Material and Methods:** In Regional Institute of Medical Sciences, Imphal, Manipur. Thirty consecutive patients with fracture olecranon process of ulna treated with locking compression plate with follow up period of 6 months. **Results:** Based on the DASH assessment criteria, the final outcome for all cases was excellent in 26 (86.66%), good in 3 (10%) and failure in 1 (3.33 %) patient. **Conclusion:** Locking compression plate acts as an extra-medullary load bearing device, stabilising fracture fragments and ensuring early bony union. The locked plate-screw system produces a rigid screw-bone fixation which prevents malrotation or shortening. Early return of joint functions is easily achieved concurrent with fracture healing.*

Keywords: Olecranon fracture, Locking compression plate, Extra medullary load bearing device, DASH criteria, Early bony union.

1. Introduction

Olecranon fractures represent approximately 10% of all fractures around the elbow and can be caused either by direct trauma, such as falling on the tip of the elbow, or by indirect trauma, such as falling on a partially flexed elbow with indirect forces generated by the triceps muscle avulsing the olecranon^(1,2). Elbow injuries occur in specific patterns. Recognition of these patterns can help the surgeon anticipate associated fractures and ligament injuries, better predict the prognosis of the injury, and plan and execute operative treatment. For example, the capsuloligamentous injury in an elbow dislocation progresses from lateral to medial in a posterolateral rotatory mechanism. As the elbow dislocates posteriorly, the radial head and/or the coronoid process can fracture as they collide with the distal humerus. The last structure to be injured is the anterior band of the medial collateral ligaments. On the other hand, the elbow can be destabilized by a distinct injury pattern that involves a varus posteromedial rotational injury force. This is characterized by a fracture of the anteromedial facet of the coronoid process with either a lateral collateral ligament injury, a fracture of the olecranon, or both.

Extensor integrity is examined by asking the patient to extend the elbow against gravity. It is also critical to check the integrity of the ulnar nerve preoperatively because its proximity to the fracture site renders it vulnerable to injury⁽³⁾

1.1 Anatomy of Elbow Joint

The elbow joint is a hinge variety of synovial joint. This includes two articulations

- 1) Humero-ulnar, between humeral trochlea and ulnar trochlear notch and
- 2) Humero-radial, between humeral capitulum and radial head.

Its complexity is increased by continuity with the superior radio-ulnar joint within a continuous synovial cavity, this complex being the cubital articulation.

1.2 Ligaments of the elbow joint

The humero-ulnar and humero-radial articulations form a largely uni-axial joint. The ligaments include capsular and the collaterals namely, ulnar and radial collateral. The collateral ligaments supplement the natural stability of the elbow joint.

a) The articular capsule:

It is anteriorly broad and thin, attached proximally to the humerus above the coronoid and radial fossae and to the front of medial epicondyle, and distally to the edge of the ulnar coronoid process and annular ligament. On either side it is continuous with the ulnar and radial collateral ligament. Posteriorly the capsule is thin and attached proximally to the humerus behind its capitulum and lateral trochlear margin and lower part of the olecranon and distally it reaches the superior and lateral margins and is laterally continuous with the superior radio-ulnar capsule.

b) The ulnar collateral ligament:

This is a triangular band consisting of thick anterior, posterior and inferior parts limited by thin intermediate fibers. The anterior part is attached by its apex to the front of medial epicondyle and by its broad distal base to proximal tubercle on the medial coronoid margin. The posterior part, also triangular is attached on the back of medial epicondyle and to the medial margin of olecranon. The inferior or oblique part is a weak band extending between olecranon and coronoid processes.

c) The radial collateral ligament:

This is a fan shaped band, attached proximally to the lateral epicondyle and distally to the annular ligament. Some of its posterior fibers cross the ligament to the proximal end of the ulnar supinator crest. It is intimately blended with the attachment of supinator and extensor carpi radialis brevis.

2. Material and Methods

This is a prospective study in which minimum of thirty consecutive admitted patients with fracture olecranon process of ulna, aged 20 to 70 years, irrespective of sex, has been subjected to internal fixation with locking compression plate.

The fractures has been assessed by anteroposterior and lateral view X-rays (figure 1). All routine investigations (blood routine examination, urine routine examination, electrocardiograph, bleeding time, clotting time, chest X-rays, blood sugar-fasting & post prandial, liver function test and kidney function test) has been done on all patients. Operation has been done under suitable anaesthesia (general / regional anaesthesia).

3. Operative/Surgical Techniques

The patient is placed in a lateral decubitus position on the operating room table with the injured arm in a nonsterile tourniquet strapped to an arm holder, allowing a full range of flexion and extension⁽³⁾. The skin over the arm will be prepared by soap scrub and application of the povidone iodine solutions. A dorsal midline incision that gently curves around the medial aspect of the olecranon tip is made with the proximal extent of the incision extending several centimeters proximal to the olecranon. The ulna is exposed between the flexor and extensor carpi ulnaris muscles. The triceps insertion is not violated. No more than 2 mm of periosteum at the fracture edges is elevated to visualize an anatomical reduction. Two Kirschner wires (K-wires) are then drilled antegrade from the medial and lateral margins of the proximal fragment to hold the reduction without obstructing midline plate placement. Reduction of the fracture is confirmed with biplanar fluoroscopic imaging. The contoured plate is then applied to the dorsal surface of the olecranon with the proximal portion of the plate being applied superficial to the triceps tendon (figure 2). The incision wound has been closed in three layers (figure 3). The operated limb will be kept elevated with elbow right angle flexed. During this time passive and active movements of fingers will be encouraged. Patient will receive parenteral third generation cephalosporin for three days which will be changed to appropriate oral formulation if required later on. Check X-ray (Antero-posterior/Lateral) of the elbow will be taken next day (figure 4).

4. Results and Discussion

Of the thirty adult patients with fracture olecranon underwent open locking compression plating over the three years at average of 6 month follow up with mean age of 31 ± 9 years. The age group of 21-30 yrs. comprised the highest number of patients (53.33%) (Figure 5 table 1). There were 26 (86.66%) closed fractures and 4 (13.33%) type I open fractures. The mean duration of hospitalization for all patients was 20.4 ± 3.2 days (14 - 29 days) which was differed little between open and closed fractures (Table 2). The mean time to sound clinical union was 12.65 ± 3.78 weeks (10 -30 weeks). Mean time to complete cortical bridging or radiological union was 23.68 ± 3.17 weeks (20 -

36 weeks) (Table 3). There were no intraoperative and immediate post-operative complications. Late complications encountered were single cases of non-union due to infection, 1 failure (broken locking plate) and 1 superficial wound infection.

Based on the assessment criteria Disabilities of the Arm, Shoulder and Hand(DASH) for the present study, the final outcome for all cases was excellent in 26 (86.66%) patients, good in 3 (10%) patients and failure in 1 (3.33%) patient (Table 4).

5. Conclusions

Locking compression plate acts as an extra-medullary load bearing device, stabilizing fracture fragments and ensuring early bony union. Vascular compromise is minimal due to the fact that the plate does need not to be in contact with the bone. The locked plate-screw system produces a rigid screw-bone fixation which prevents malrotation or shortening. Early return of joint functions is easily achieved concurrent with fracture healing. Though not an ideal procedure as far as operative scar is concern, an open compression plate fixation with minimal periosteum and vascular traumatization, locking compression plating is a safe procedure for complex olecranon fractures, with an excellent functional outcome, early clinical and radiological union, it can be done on a routine basis with a minimum of complication.

References

- [1] Miller RH, Dlabach AJ. Shoulder and elbow injuries. In: Canale ST, Beaty JH, editors. Campbell's Operative Orthopaedics. 11th ed. Philadelphia: Mosby Elsevier; 2008. p. 2601-55.
- [2] Veillette CJ, Steinmann SP. Olecranon fractures. Orthop Clin North Am 2008 Apr; 39(2): 229-36.
- [3] Ring D. Elbow fractures and treatments. In: Bucholz RW, Court-Brown CM, Heckman JD, Tornetta P, editors. Rockwood and Green's Fractures in Adults. 7th ed. Philadelphia: Lippincott Williams and Wilkins; 2006. p. 906-42.
- [4] Hak DJ, Golladay GJ. Olecranon fractures: treatment options. J Am Acad
- [5] Orthop Surg 2000; 8: 266-75.

Table 1: Showing age-sex distribution of patients

Age group (in years)	Male	Female	Total	Percentage (%)
18-20	2	1	3	10.00
21-30	12	4	16	53.33
31-40	5	1	6	20.00
41-50	3	1	4	13.33
51-60	-	1	1	3.33
Total	22	8	30	100.00

Table 2: Showing duration of hospital stay

Type of fracture	Duration of hospitalisation (days)	Mean duration of hospitalisation (days)
Closed	14-27	20.1 ± 2.9
Open	19-29	22.0 ± 4.7
Combined	14-29	20.4 ± 3.2

Table 3: Showing time to union

Type of Union	Duration to union (weeks)	Mean duration to union (weeks)
Clinical	10-30	12.65 ± 3.78
Radiological	20-36	23.68 ± 3.17

Table 4: Showing final result

Outcome	Number of patients	Percentage (%) (n=30)
Excellent	26	87 (86.67)
Good	3	10 (10)
Failure	1	3 (3.33)
Total	30	100.00

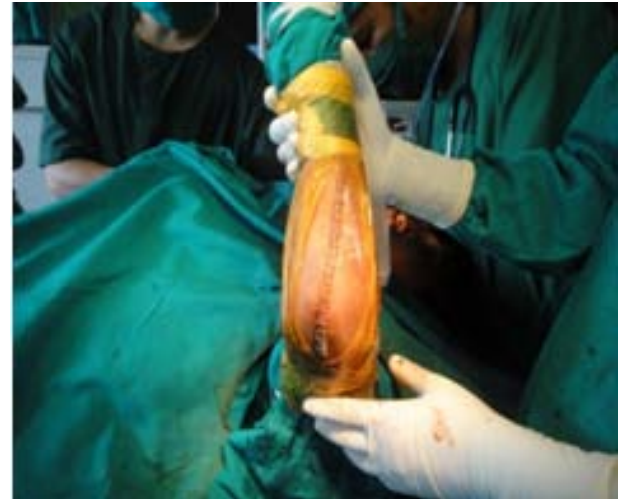

Figure 3

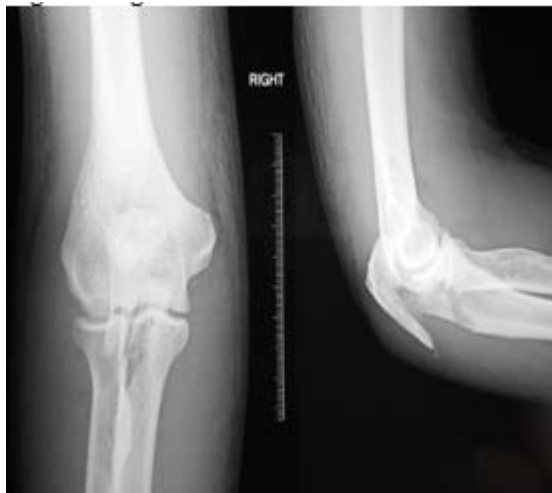

Figure 1

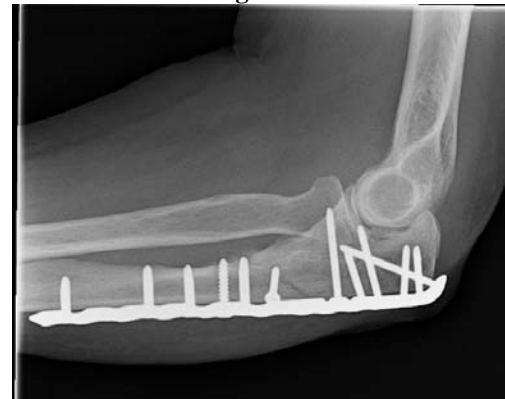

Figure 4

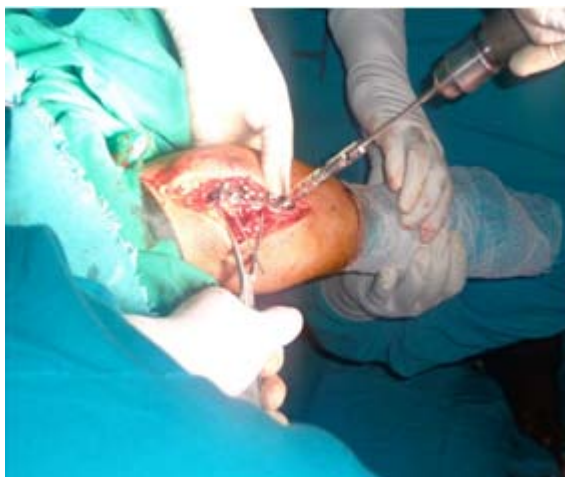

Figure 2

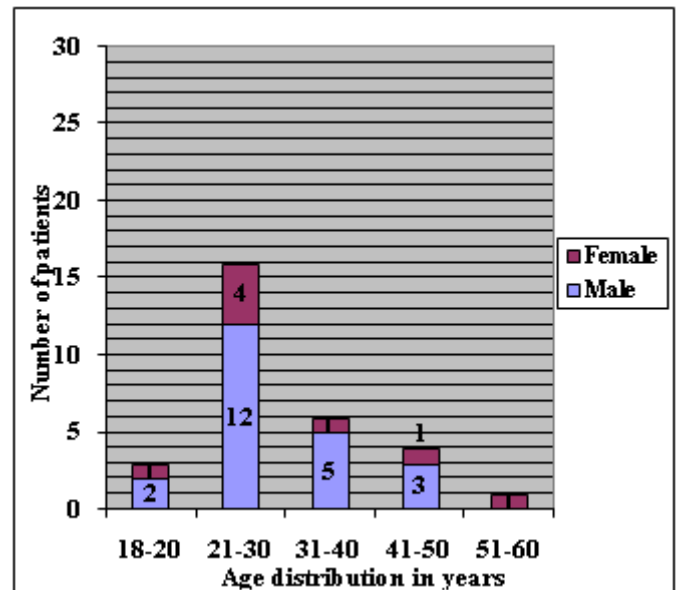


Figure 5: Showing age-sex distribution of patients

Author Profile



Dr. Amit Agrahari passed MBBS in 2010 from S.N.M.C. Agra, UP, India. He is Post-graduate trainee, Department of Orthopaedics, Regional Institute of Medical Sciences, Imphal, Manipur, India.

Dr. S. N. Chishti is professor, Department of Orthopaedics, Regional Institute of Medical Sciences, Imphal, Manipur, India.

Dr. A. Mahendra Singh is professor, Department of Orthopaedics, Regional Institute of Medical Sciences, Imphal, Manipur, India.

Dr. Snehasish Datta is Post-graduate trainee, Department of Orthopaedics, Regional Institute of Medical Sciences, Imphal, Manipur, India.

Dr. Vinil Paul is Post-graduate trainee, Department of Orthopaedics, Regional Institute of Medical Sciences, Imphal, Manipur, India.