

Histological Study of follicles in Thyroid Gland of *Pati* Ducks (*Anas platyrhynchos domesticus*) of Assam at Different Age Groups

Snehangsu Sinha¹, Munmun Sarma², KB Dev Choudhury³

Department of Veterinary Anatomy & Histology, College of Veterinary Science,
Assam Agricultural University, Khanapara, Guwahati-781022, India

Abstract: The study was conducted on 42 number of Assam *Pati* ducks divided into 7 groups to study the histomorphological characteristics of thyroid glands from day-old to 40 weeks of age. The thyroid glands were collected from 6 birds in each group. The material was fixed and processed for histological studies. The microscopic structure of thyroid glands of *Pati* ducks revealed primarily the capsule enclosing the follicles that contained colloid. The capsule was made up of collagen and reticular fibers with scanty elastic fibers. The interfollicular space was narrow and consisted of fine collagen and reticular fibers that extended from the capsule. The interfollicular space was relatively devoid of elastic fibers. Parenchyma of thyroid gland was composed of follicles. Follicles were lined by single layer of epithelial cells. As the age advanced, the size of the follicles increased with a mean diameter.

Keywords: Diameter, Epithelium, Thyroid, Follicles, *Pati* ducks.

1. Introduction

The '*Pati*' duck population constitutes a major indigenous non-descript duck variety in Assam. *Pati* ducks have been playing vital role in rural economy of Assam. The thyroid gland is a unique endocrine gland which plays an important role in maintaining general metabolic rate and controlling pre and post natal growth and differentiation of many organ systems. Epithelial lining indicates the activity of the thyroid gland. As the work on epithelial lining is lacking in *Pati* ducks of Assam, a comprehensive study was taken up to document the changes in epithelial lining height of follicles in thyroid gland at various age groups.

2. Materials and Methods

For histological and micrometrical study thyroid gland samples were collected from different age group of *Pati* ducks. The tissue samples were fixed in 10% neutral buffered formalin and standard procedures were adopted for histomorphological studies. Different micrometrical parameters were recorded on Hematoxylin and eosin stained sections by means of standard method of micrometry using Nikon E 200 camera mounted microscope and Image Pro Express Ver-2.0 Software. The data were analysed using the Statistical Analyses System version 9.3 (SAS 2012) for Microsoft Windows.

3. Results and Discussion

The paired thyroid glands in the *Pati* ducks were located on either side of the trachea close to the vascular angle formed by the subclavian artery and common carotid artery. The microscopic structure of thyroid glands of *Pati* ducks revealed primarily the capsule enclosing the follicles that contained colloid. The capsule was made up of collagen and reticular fibers with scanty elastic fibers. Parenchyma of thyroid gland was composed of follicles. The follicles were closely packed together and their shape varied from oval to

polyhedral in all the age groups. Follicles were lined by single layer of epithelial cells and type of epithelium depends upon their functional status. Therefore, based on the type of epithelium and nature of colloid, the follicles were categorized as active follicles and inactive follicles. The quantity of colloid varied according to the activity of the thyroid gland. In the inactive follicles, it was more and homogenous due to accumulation of large amount of colloid (Fig 1), whereas in active follicles it was lesser and non-homogenous. The active follicles increased upto 8 weeks of age and then a gradual decrease was seen until the end of the study. The inactive follicles increased with the advancement of age. This might be related with the activity of the thyroid gland with advancement of age. The active follicles were lined by simple cuboidal epithelium, while the inactive follicles were lined by simple squamous epithelium (Fig: 2) which was similar to the findings of Hodges (1974) in fowl, Enura *et al.* (1977), Wight and Shannon (1985) in quail). As the age advanced, the size of the follicles increased with a mean diameter of $90.715 \pm 0.003 \mu\text{m}$ in day old to $153.886 \pm 0.162 \mu\text{m}$ in 40 weeks old birds. This was similar to the findings observed by Lucy *et al.* (2009) in Kuttanad ducks. Micrometrical values of follicular diameter for all the age groups are presented in table 1.

4. Conclusion

From the present investigation it can be concluded that the Parenchyma of thyroid gland was composed of follicles. Follicles were lined by single layer of epithelial cells and type of epithelium depends upon their functional status. The quantity of colloid varied according to the activity of the thyroid gland. As the age advanced, the size of the follicles increased.

5. Acknowledgement

The author conveys heartiest thanks to Dr. Kabita Sarma, Prof. & Head, Dept. Anatomy & Histology for her support and fruitful advices during the research programme.

References

- [1] Enura S, Isogai I and Tranloom, H. (1977) Ultrastructure of quail thyroid gland. *Jap. Poult. Sci.* **14**: 121-130.
- [2] Hodges RD (1974) The Histology of the fowl. Academic press, New York . pp 440-445.
- [3] Lucy KM, Maya S, Indu VR, Joseph L and Patki HS (2009) Age related changes in the histomorphology of thyroid gland in Kuttanad ducks (*Anas platyrhynchos domesticus*).IV World Waterfowl Conference, Thrissur, India:244-249.
- [4] SAS. Statistical Analyses System, version 9.3 for Microsoft Windows. SAS Institute Inc., Cary, NC, USA, 2012.
- [5] Wight PAL and Shannon DWL (1985) The morphology of the thyroid glands of quails and fowls maintained on the diet containing rape seed. *Avian Pathol.* **14**: 383-399.

Table 1: Micrometric parameters of follicular diameter at different age groups in *Pati* ducks

| Age groups | Diameter of follicles (µm) |
|------------|------------------------------|
| Day old | 90.715 ± 0.003 ^g |
| 2 week | 94.155 ± 0.150 ^f |
| 4 weeks | 96.296 ± 0.114 ^e |
| 8 weeks | 98.921 ± 0.249 ^d |
| 20 weeks | 125.390 ± 0.149 ^c |
| 30 weeks | 142.535 ± 0.100 ^b |
| 40 weeks | 153.886 ± 0.162 ^a |

Means with different superscripts are significantly different from each other (P<0.0001).

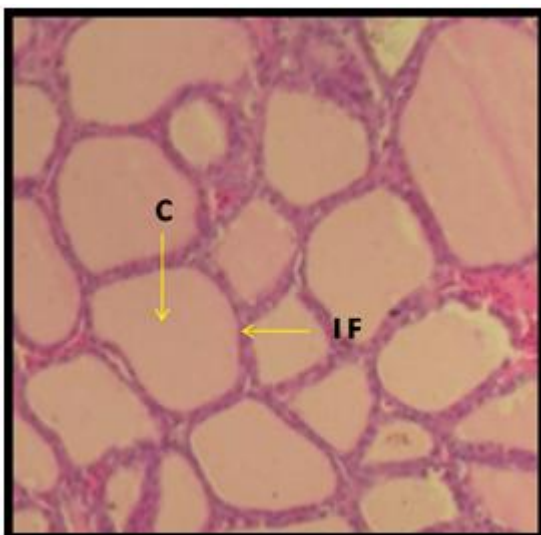


Figure 1: Photomicrograph showing inactive follicles (IF) with thick colloid (C) in 40 weeks old *Pati* duck. H&E, X40.

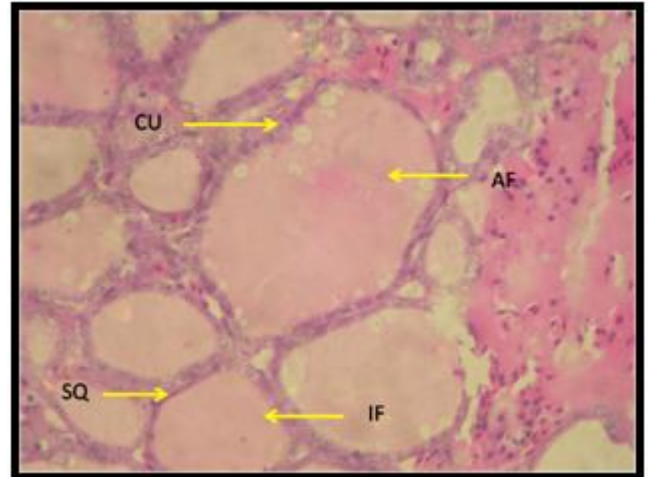


Figure 2: Photomicrograph showing active follicles (AF) lined by cuboidal epithelium and inactive follicles (IF) lined by simple squamous epithelium (SQ) in 30 weeks old *Pati* duck. H&E, X40.