

Cavernous Hemangioma of the Small Bowel Presenting with Occult Obscure Gastrointestinal Bleeding

Emad Suliman Aljahlili

Abstract: *This article is representing a 70 year-old woman with chronic iron deficiency anemia secondary to small bowel cavernous hemangioma.*

Keywords: small bowel bleeding, cavernous hemangioma, occult gastrointestinal bleeding

A 70-year-old female was referred to our institution for further evaluation of chronic iron deficiency anemia with hematocrit of 32.8 % and guaiac positive brown stools. Patient had no history of dysphagia, abdominal pain, weight loss, nausea, vomiting, or blood in the stool. She underwent upper endoscopy and colonoscopy that were unrevealing. Subsequently she underwent capsule endoscopy that showed a non-bleeding, ulcerated mass versus polyp in the jejunum. The patient then underwent CAT scan of abdomen and pelvis showing polypoid lesions in the mid-jejunum (Figure 1)

The findings led us to perform antegrade spiral enteroscopy, which showed a non-obstructing, protruding bluish and ulcerated lesions in the jejunum. The lesions were actively oozing blood (Figure 2). Given their atypical appearance, a decision was made to biopsy them and india ink was placed at the site for future recognition.

The biopsies were unrevealing showing only normal small bowel mucosa. The patient was then referred to surgery for potentially malignant small bowel tumor. In the operating room, the endoscopically injected india ink was noted approximately 5 cm distal to the ligament of Treitz. The small bowel was run from the from the ligament of Treitz to the cecum and no other lesions were noted. The surgically resected lesion was approximately 8 cm long (Figure 3). The patient had an uneventful recovery and was discharged home in 5 days.

Final pathology showed large blood-filled sinuses lined by multiple layers of endothelial cells. Findings were consistent with cavernous hemangioma of the small bowel (Figure 4).

Gastrointestinal hemangiomas are uncommon benign vascular tumors that may occur anywhere in the gastrointestinal tract as single or multiple lesions. They are also seen in Hereditary Hemorrhagic Telangiectasia, Maffucci's syndrome, Klippel-Trenaunay syndrome, and Blue Rubber Bleb Nevus syndrome. Bleeding is the most common clinical presentation and can be insidious or massive and life-threatening. Patients may also present with abdominal pain, mechanical bowel obstruction, or perforation. Small bowel is the most common site of gastrointestinal hemangiomas. Colon is the second most common site. Histologically, they are classified into capillary hemangiomas with proliferation of small capillaries composed of a thin-walled, blood filled space lined by endothelial cells and cavernous hemangiomas with large blood-filled sinuses lined by a single or multiple layers of endothelial cells.

References

- [1] Gastrointestinal Hemangiomas: Imaging findings with pathologic in pediatric and adult patients. Angela D. Levy, Robert M. Abbott, Charles, A. Rohrman, Jr. , Aletta Ann Frazier. *AJR*:177, November 2001
- [2] Dachman AH, Ros PR, Shekita KM, Buck JL, Olmsted WW, Hinton CB. Colorectal hemangioma: radiologic findings, *Radiology* 1988
- [3] Bank ER, Hernandez RJ, Byrne WJ, Gastrointestinal hemangiomas in children; demonstration with CT. *Radiology* 1987; 165:657-658

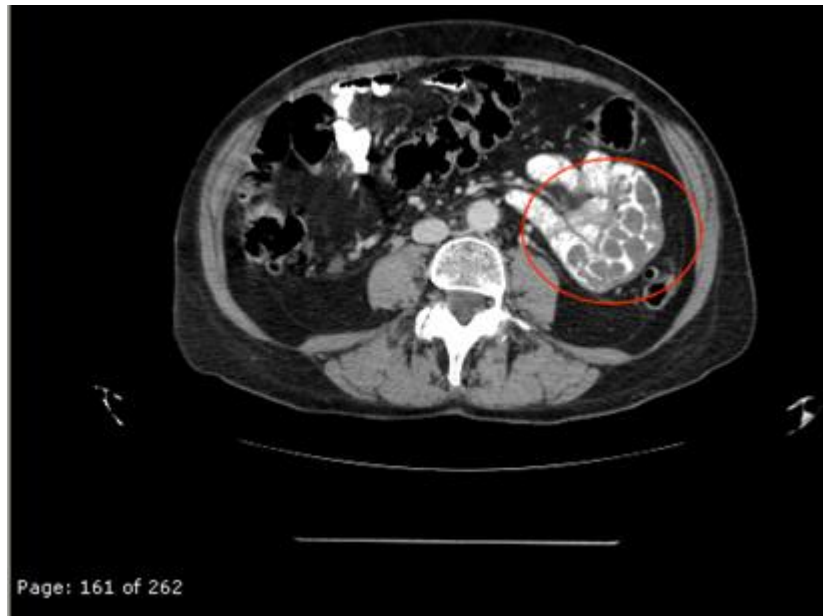

Figure 1

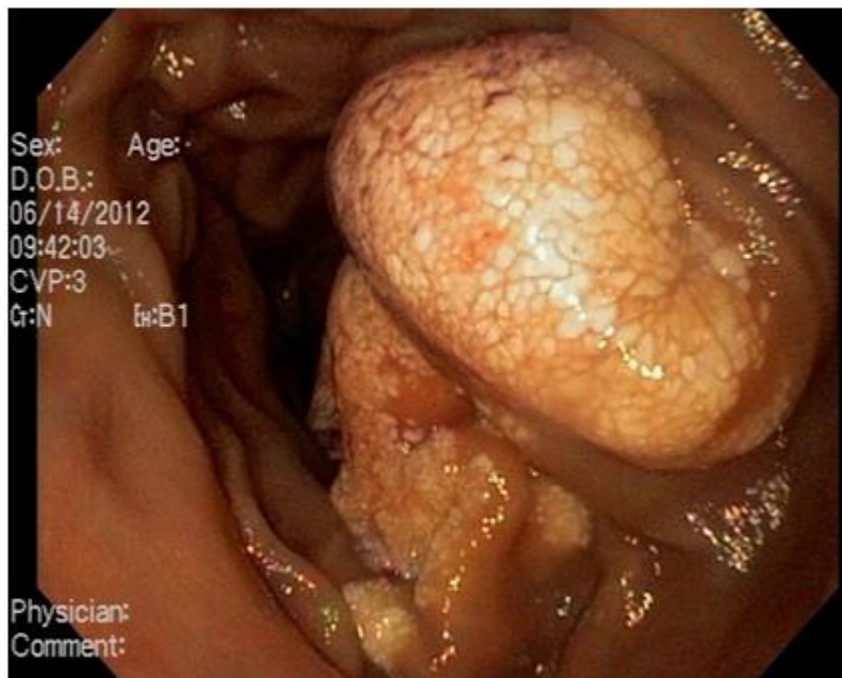


Figure 2

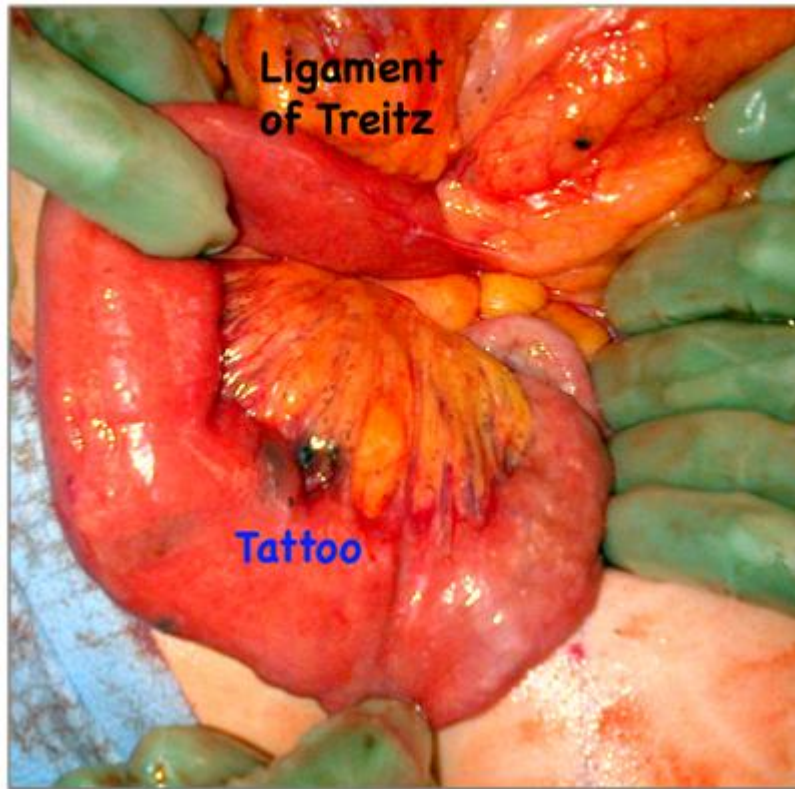


Figure 4

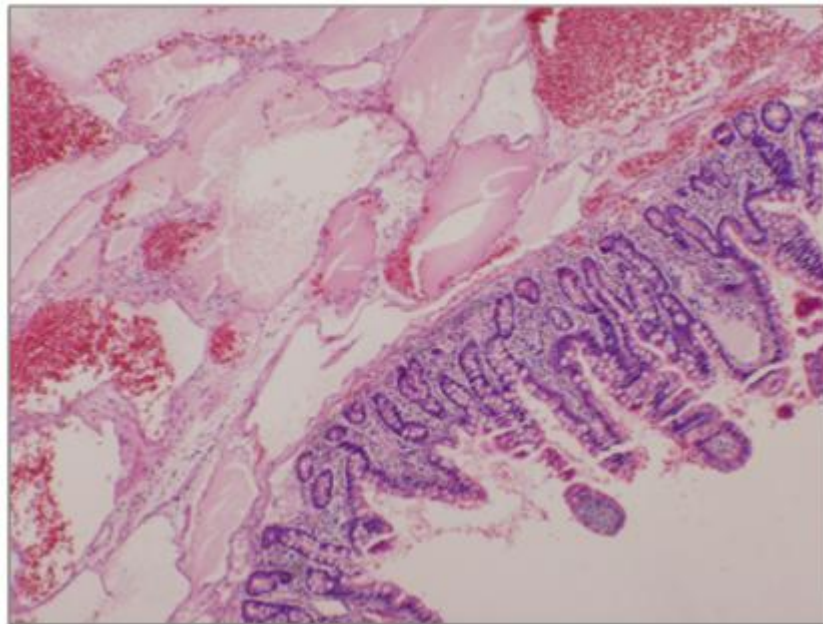


Figure 5