

Analysis of Retinal Nerve Fiber Layer Thickness in Patients with Pseudoexfoliation Syndrome Using Spectral Domain Optical Coherence Tomography

Dr. R. R. Naik¹, Dr. Vikram B Bhalke²

¹Prof and HOD, Department of ophthalmology, PDVVPF's Medical college and hospital, opp. Milk dairy, Vadgaon Gupta, Vilad ghat Ahmednagar-414111 Maharashtra, India

²JR-3, PG Student, Department of ophthalmology, PDVVPF's Medical college and hospital, opp. Milk dairy, Vadgaon Gupta, Vilad ghat Ahmednagar-414111 Maharashtra, India

Abstract: ***Aim:** To detect early glaucomatous damage in PXS with normal IOP, visual field and optic nerve head appearance by assessing the RNFL thickness using SD-OCT. **Design:** prospective observational study. **Methods:** The study was carried out on 40 eyes; 20 non-glaucomatous eyes with PXS (group A) and 20 normal control subjects (group B). After informed consent was signed and BCVA, participants underwent slit lamp biomicroscopy, Goldmann applanation tonometry, gonioscopy, ophthalmoscopy, automated refraction and Humphrey (central 24-2 threshold) visual field. **Results:** In our study we demonstrated the mean overall RNFL thickness in both groups and we found it was lower in group A than B. **Conclusion:** Pseudo-exfoliation syndrome without glaucoma may be associated with a thinner RNFL compared with those of control subjects so even small rise in IOP causes damage to the RNFL. Thus we can say that structural damage precedes functional loss and that early RNFL thickness assessment using OCT is important in the early diagnosis, intervention and follow-up of pseudo exfoliation glaucoma.*

Keywords: Retinal Nerve Fiber Layer, Pseudoexfoliation Syndrome, Spectral Domain Optical Coherence Tomography

1. Introduction

Pseudoexfoliation syndrome (PXF) is an age-related systemic disorder. In ocular tissues it gradually leads to deposition of fibrillary material from the lens and iris pigment epithelium on to the lens capsule, ciliary body, zonules, corneal endothelium and iris.

The characteristic findings during the ophthalmic examination are typical, white fibrillary material on the anterior lens capsule and pupillary margin is observed and pupillary transillumination defects and pigmentation of the trabecular meshwork is also present.

Active involvement of the trabecular meshwork in this characteristic matrix process may lead to secondary open angle glaucoma (pseudo exfoliative glaucoma (PXG) in 40-60% of the patients.¹

PXG represents a relatively severe and progressive type of glaucoma, with a generally poor prognosis due to high intraocular pressure levels, great pressure differences between the two eyes and fluctuations in the diurnal pressure curve.²

Local production of pseudo exfoliation (PEX) material by trabecular meshwork and Schlemm's canal cells is the primary cause of chronic pressure elevation in pseudoexfoliation syndrome (PXF). Additional pathogenetic factors contributing to pressure increase include pronounced melanin dispersion, increased protein concentrations of the aqueous humor, vascular factors, and connective tissue alterations of the lamina cribrosa.¹

As RNFL damage may present before any detectable visual field loss, IOP elevation and optic nerve head defects as an early clinical sign of open-angle glaucoma;

early glaucomatous changes in PXS, despite normal IOP, optic nerve appearance and visual field; it can be detected by measuring RNFL thickness using OCT.³

Aim

To detect early glaucomatous changes in Pseudoexfoliation syndrome (PXS), despite normal IOP, optic nerve appearance and visual field by assessing the RNFL thickness using OCT.

2. Materials and Methods

Our study is a prospective observational case control study involving 60 eyes; 30 were non-glaucomatous (normal IOP, fundus and visual field) eyes with PXS (group A) and another 30 were of same age but normal controls (group B). This study was conducted in the Ophthalmology Department of PDVVPF's Medical college and hospital from February to November 2015.

Inclusion Criteria

Pseudoexfoliative patients (clinically diagnosed) and normal age matched control subjects with:

- Normal optic nerve head appearance (with C/D ratio less than or equal to 0.3 and asymmetry less than or equal to 0.2 between fellow eyes) and normal retina.
- Normal intraocular pressure (IOP less than or equal to 21 mmHg with normal diurnal variation and difference less than or equal to three mmHg between fellow eyes).
- Normal visual field test.

Exclusion Criteria

- History of any ocular diseases.
 - History of any systemic diseases such as diabetes mellitus and hypertension.
 - History of previous intraocular surgery.
 - Glaucomatous patients or family history of glaucoma.
 - Previous ocular trauma.
 - Media opacity interfering with visualization and OCT images capturing such as corneal opacity or dense cataract.
 - Retinal pathology.
-
- Informed consent was taken from the patients and they underwent following examinations:
 - Visual acuity (BCVA)
 - Slit lamp biomicroscopy was done to detect signs of PXS such as pseudo exfoliative material at the pupillary border, anterior lens capsule or angle, sphincteric atrophy and lens subluxation
 - Goldmann applanation tonometry
 - Gonioscopy
 - Ophthalmoscopy
 - Automated refraction and Humphrey (central 24-2 threshold) visual field examination.

The RNFL thickness was assessed using 3D mastro oct of topcon. The RNFL thickness map was displayed along with its ratio to normative RNFL thickness.

The global and four-quadrant average RNFL thickness data (temporal, superior, nasal and inferior) was collected and compared in both groups. The results were reported as mean values plus/minus SD. Data was statistically analyzed. An unpaired *t*-test was used to calculate the *p* value between the study and the control group. Values of *p* less than 0.05 were considered statistically significant.

3. Results

Forty eyes of 60 patients were included in the study; 30 eyes with non-glaucomatous PXS (group A) and 30 age-matched free control subjects (group B).

Patient age ranged from 45-65 years in both groups with a mean of 57.67 plus/minus 4.33 SD in group A and 57.07 plus/minus 4.60 SD in group B. There were 16 (53.33%) males and 14 (46.67%) females in group A and 15 (50%) males and 15 (50%) females in group B. The difference between both groups was statistically insignificant.

Table 1: Patient demographic and inclusion data

	PXS group (A)	Control group (B)
No. of patients	30	30
Age (Mean ± SD)	57.67± 4.33	57.07± 4.60
Sex(%)	(53.33%) M (46.67%) F	(50%) M (50%) F
IOP (Mean ± SD)	15.1 ± 1.7	14.2 ± 1.07

In group A the mean IOP was (16.1 plus/minus 1.4 SD) while in group B the mean IOP was (14.2 plus/minus 1.07

SD). The difference between both groups was statistically insignificant (*p* greater than 0.05).

Table 2: RNFL thickness parameters (mm) (mean and SD) global and for each quadrant in (group A and B)

RNFL Quadrants	PXS group (A) (Mean ± SD)	Control group (B) (Mean ± SD)
Temporal	61.65 ± 7.75	71.45 ± 8.15
Superior	109.9 ± 13.05	132.1 ± 9.33
Nasal	67.25 ± 12.1	70.7 ± 8.16
Inferior	104.2 ± 11.83	112.6 ± 11.81
Global average	85.52 ± 19.7	97.21 ± 20.21

In (group A), the values of RNFL thickness measurement in all quadrants were low compared to (group B). The average overall RNFL thickness was (86.52 plus/minus 9.7) in (group A) and (99.21 plus/minus 20.21) in (group B) with no quiet statistically significant difference between both groups.

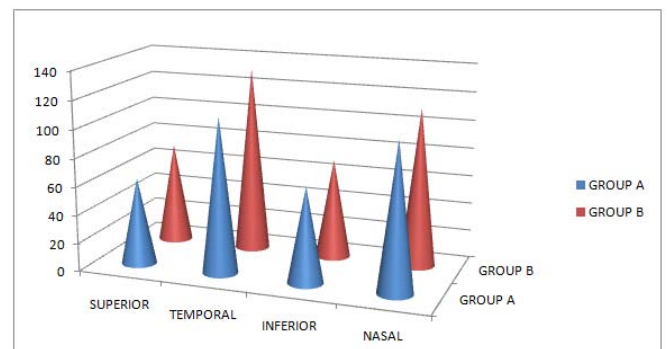


Chart 1

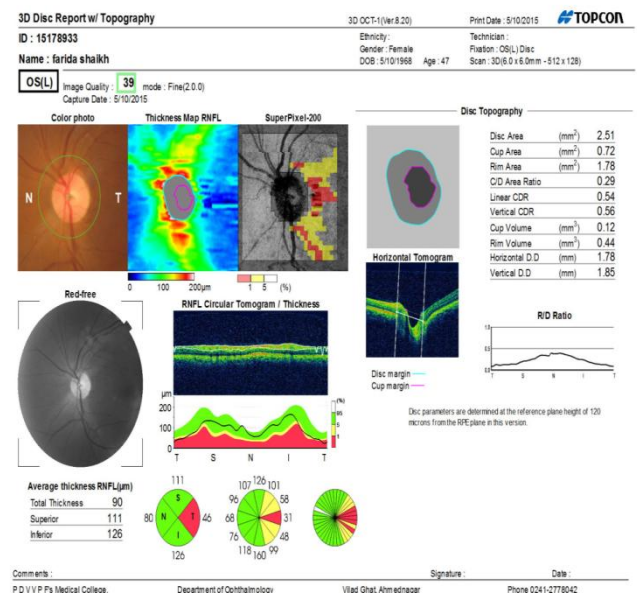


Figure 1: Group A Thinning of RNFL in temporal quadrant

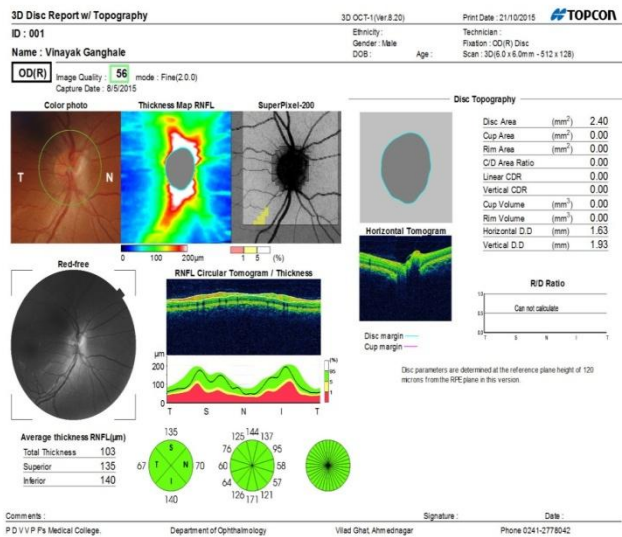


Figure 2: Group B-control group characteristic double-hump pattern (double peak curve) with RNFL thickness peaks in the superior and inferior quadrants (thickest) and troughs in the temporal and nasal

4. Discussion

Secondary chronic open-angle glaucoma associated with PXS accounts for approximately 25% of all glaucoma and represents the most common identifiable cause of glaucoma overall⁽²⁾.

The RNFL defect, which may be presented before any detectable IOP elevation or optic nerve head and visual field damage, is a main sign of early glaucomatous damage.

The high diagnostic accuracy of the Spectral OCT allows scanning of the RNFL thickness and monitors changes in thickness for the detection of early glaucoma.

The aim of this study is to detect early RNFL damage in pseudo exfoliative patients without glaucoma by measuring RNFL thickness using spectral OCT and comparing the results with age matched healthy control subjects.

The RNFL thickness in normal subjects (group B); was normally thicker in the superior and inferior, thinner in the temporal and lowest in the nasal quadrants; however in group A; there were significant differences in RNFL thickness among the four quadrants except for the nasal quadrant compared to the control group.

This could be explained by the fact that higher axonal density and higher proportion of large fibers occupies the supero and inferotemporal portions of the optic nerve head compared to the nasal portion. These fibers are in addition; most susceptible to early glaucomatous damage.

Yüksel *et al*⁽⁴⁾. assessed the RNFL thickness in patients with unilateral PXS without glaucoma and their normal fellow eyes using Stratus OCT- 3. The RNFL in patients with PXS were significantly thinner than controls in all quadrants except the nasal quadrant with regard to

quadratic and segmental analysis (p less than 0.05). This RNFL loss was apparent at 7, 10 and 11 o'clock of the PXS eyes with regard to clock hour position (p less than 0.05). In the fellow eyes, no significant difference in RNFL measurement was found except the temporal quadrant when compared with the controls. This result is comparable with our study

Sihota *et al.*⁽⁵⁾ evaluated the role of (OCT) in detecting differences in peripapillary RNFL thickness among normal and glaucomatous eyes and also among different severities of glaucoma. The average RNFL in control subjects, early glaucoma, moderate glaucoma, severe glaucoma, and blind glaucoma were 102.30 plus/minus 10.34, 77.68 plus/minus 15.7, 66.07 plus/minus 15.5, 53.65 plus/minus 14.2, and 44.93 plus/minus 4.95 micron, respectively. With a significant difference in all RNFL thickness parameters between normal and all glaucoma subgroups (p less than 0.001).

Liu *et al.*⁽³⁾ investigated image characteristics and thickness of RNFL in 83 normal eyes and 83 patients with primary open angle glaucoma with different stages using OCT. They documented a significant difference in RNFL thickness among the four quadrants and the mean overall RNFL thickness except for the nasal quadrant in the early POAG. It was seen that more severe the glaucoma, thinner the RNFL thickness.

Asaoka *et al.*⁽⁶⁾ reported also a significant decrease in RNFL thickness measurement in the superior (p less than 0.05), superotemporal and inferotemporal sectors (p less than 0.01); in early glaucomatous eyes with normal perimetric visual fields and SLO compared to the age matched control subjects

5. Conclusion

Pseudoexfoliation syndrome without glaucoma may be associated with a thinner RNFL compared with those of age-matched normal subjects so even small rise in IOP causes damage to the RNFL. This provides evidence that structural damage precedes functional loss and that early RNFL thickness assessment using OCT is important in the early diagnosis, intervention and follow-up of pseudo exfoliation glaucoma.

References

- [1] Stefan C, Tebeanu E, Nenciu A. Pseudo exfoliative glaucoma. *Ophthalmologie*. 2007; 51:50–2.
- [2] Schlötzer-Schrehardt U, Küchle M, Jünemann A, Naumann GO. Relevance of the pseudoexfoliation syndrome for the glaucomas. *Ophthalmologie*. 2002;99:638–90.
- [3] Liu X, Ling Y, Luo R, Ge J, Zheng X. Optical coherence tomography in measuring retinal nerve fiber layer thickness in normal subjects and patients with open-angle glaucoma. *Chin Med J (Engl)* 2001; 114:524–9.
- [4] Yüksel N, Altıntaş O, Celik M, Ozkan B, Çağlar Y. Analysis of retinal nerve fiber layer thickness in patients with pseudoexfoliation syndrome using

optical coherence tomography. *Ophthalmologica*. 2007; 221:299–304.

- [5] Sihota R, Sony P, Gupta V, Dada T, Singh R. Diagnostic capability of optical coherence tomography in evaluating the degree of glaucomatous retinal nerve fiber damage. *Invest Ophthalmol Vis Sci*. 2006; 47:2006–10.
- [6] Asaoka R, Ishii R, Kyu N, Hotta Y, Sato M. Early detection of thinning of retinal nerve fiber layer in glaucomatous eyes by optical coherence tomography 3000: Analysis of retinal nerve fiber layer corresponding to the preserved hemi visual field. *Ophthalmic Res*. 2006;38:29–35