

Reverse Sural Fascio Cutaneous Flap for Soft Tissue Coverage around Foot and Ankle

Dr. Bindesh¹, Dr. V.V. Narayana Rao², Dr A. Ajay³, Dr. D. Srikanth⁴

¹ Department of Orthopaedics, Government General Hospital, Guntur, India

Abstract: ***Background:** Reconstruction of lower leg and foot wounds continues to be one of the most challenging tasks, as options are limited and poor blood supply. The introduction of distally based sural fascio cutaneous flap provides reliable and effective method to cover skin defects around foot and ankle. **Study Design:** Case series. **Methodology:** Descriptive case series study was conducted at the Department of Orthopaedics, Government General Hospital, Guntur over a period of one year. We report case series of eleven patients with defects around foot and ankle secondary to trauma, infection and old crush injuries. All of them were treated surgically with reverse sural fascio cutaneous flaps. **Results:** Eleven patients aged between Thirty years to forty eight years were included in this study with mean age of 39.5. Among them Ten were male and One female. Indication of Fascio Cutaneous Flap was wound secondary to trauma (four cases), infected achilles tendon repair (two cases), old crush injury of foot (five cases). Three Patients developed superficial infection and One patient suffered partial soft tissue necrosis. we had excellent result with this procedure and the results were encouraging. **Conclusion:** Distally based sural fasciocutaneous flap surgery performed properly is reliable for coverage of soft tissue around foot and ankle. The technical advantages being easy dissection without operating microscope, preservation of more important vascular structures, complete coverage, single stage procedure. Disadvantages include learning curve and cosmetic appearance.*

Keywords: Fascio cutaneous flap, Foot and ankle, Reverse sural artery, Reverse sural flap, Sural nerve

1. Introduction

Wounds around the lower third of the leg and foot are difficult to manage because of the composite tissue defects, inadequate and tight local tissues and poor circulation. Tendons, bone or hardware are frequently exposed because of the thinness of subcutaneous tissue^{[1][2]}

An ideal flap is with good skin texture, reliable vascularity, good arc of rotation, ease of dissection and minimum donor site morbidity is the most desired option for coverage of such defects^{[3][4]} The different local flaps for hind foot defects including dorsalis pedis artery flap, abductor hallucis and abductor digiti minimi muscle flaps, have inadequate tissue and a limited arc of rotation thereby limiting their frequent use. Medial plantar artery flap is an ideal option for the weight bearing heel but its involvement in trauma frequently precludes its use^[5]

Loco regional flaps for lower leg and ankle defects such as peroneal artery flap, anterior and posterior tibial artery flaps have the disadvantage of sacrificing a major artery in an already traumatized leg^[6] Supramalleolar flap is another option but its reliability is questionable in case of vascular compromise^[7]. Free tissue transfer is ideal option in most circumstances but the need for microsurgical expertise and prolonged operating time remain its disadvantages^[8]. Among the main indications for a sural fasciocutaneous flap are soft tissue defects of the heel and the external or internal perimalleolar regions.

In 1987 Ferreira et al. presented the concept of fasciocutaneous flap of the distal pedicle based on the inframalleolar perforators. In 1992, Masquelet et al. described the use of the neurocutaneous flap for reconstruction of soft tissue defects of the distal third of the leg., which was commonly referred to as “reverse sural artery island flap” and has become an acceptable and routine

technique for lower limb reconstruction^[9]. To facilitate safe usage of this flap in difficult and special conditions, several modifications have been made to the technique, such as delaying, exteriorizing the pedicle and a wider than usual pedicle, mobilizing the peroneal perforator in the intramuscular septum, supercharging, cross-leg sural flap, leaving a skin extension over the pedicle, and harvesting a midline cuff of the gastrocnemius muscle with the flap^[26]

2. Material and Methods

We performed a descriptive case series study at Department of Orthopaedics, Government General Hospital, Guntur, which included 11 patients consisting of 9 males, 2 females. Reverse sural flap surgery was performed for treatment of soft tissue coverage secondary to trauma, Achilles tendon wound infection, and sole avulsion. All flaps were fascio cutaneous of width 7-13 centimeters and 3-4 centimeters at the base and extended upto 13 - 15 centimeters in length. The patients were evaluated on 7th day, 14th day and 45th day for the presence of necrosis, infection and sensations and patient satisfaction

Case 1

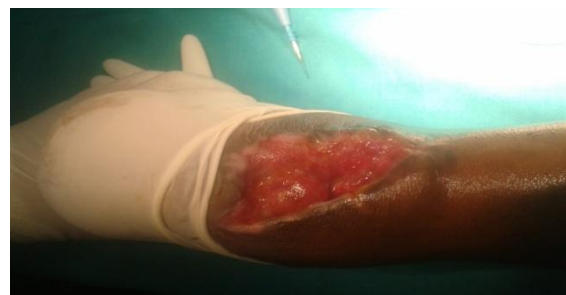

Figure 1A: Preoperative wound of infected tendoachilles repair

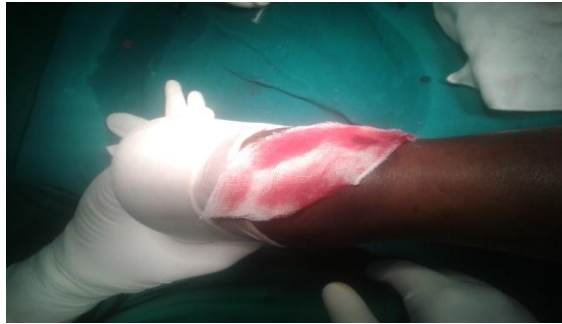

Figure 1B: Templating of the wound using sterile drape



Figure 2B: Postoperative picture on day -15

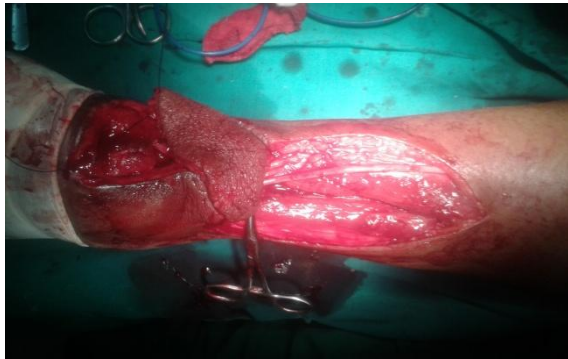


Figure 1C: Graft harvested with preserved sural nerve as seen and graft rotation was done

Case 3

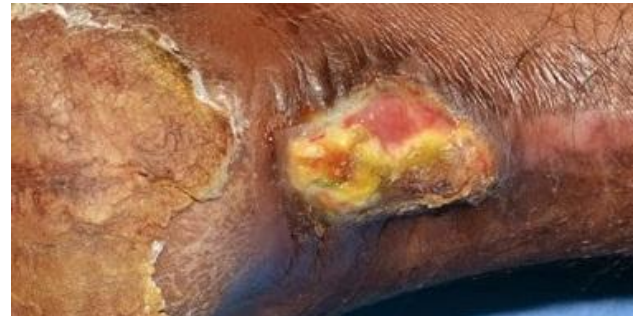

Figure 3A: Preoperative infected tendo Achilles wound

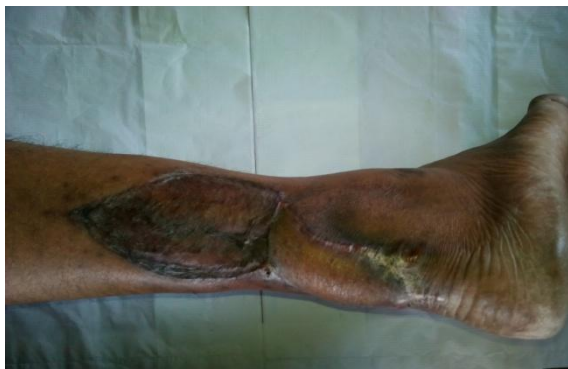

Figure 1D: Post operative picture on day-15

Case 2

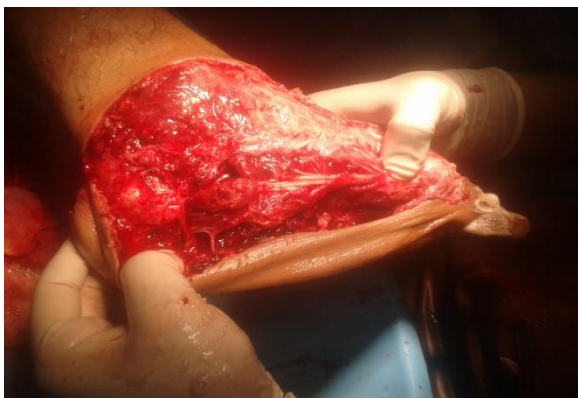

Figure 2A: Pre operative photo of sole degloving

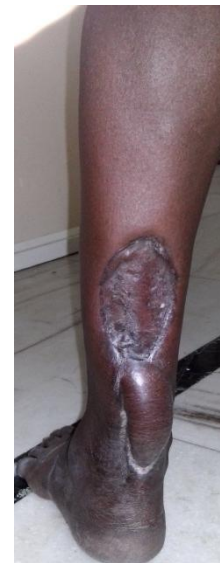

Figure 3B: Postoperative picture 45 th day

3. Methodology

Pre operative planning is done by templating the area of the wound to be covered using sterile drape and it is fashioned with the pedicle to match the original incision to be placed over the posterior aspect. The template infact acts as a guide to allow adequate rotation and correct positioning of the fascio cutaneous flap without kinking and preservation of the perforators.

Under pneumatic tourniquet, in prone position, surface marking is done. The lateral malleolus is an important land mark. Achilles tendon is marked medially and the fibula laterally. The short saphenous vein runs below and behind the malleolus and should be preserved in the pedicle as it is a principle source of venous drainage. The medial incision is

along the lateral border of Achilles tendon and the lateral incision is along the lateral malleolus. The pedicle should be as short as possible and is marked five to seven centimeters proximal to lateral malleolus, which is the location of distal most perforator of peroneal arterial supplying the flap

The marking of the flap is done with template in place after confirming adequate rotation. The skin and the superficial fascia are incised. In the proximal part of the flap sural nerve and short saphenous vein are identified and easily ligated. The dissection is carried in line with the incision till we reach the deep fascia and subfacial dissection is then carried out including the fat containing the peroneal artery and its branches. The dissection is carried out proximal to distal to a pivotal point of the pedicle four to five centimeters from the lateral malleolus tip. The width of the carrier pedicle should be three to four centimeters. We personally don't like creating subcutaneous tunnel. The flap is rotated over 180 degrees without kinking to the area of defect. The donor site can be closed using a free skin graft or interrupted sutures. The drain is placed under the rotated flap and multiple punctures are made. The wound is dressed under thick cotton padding and anterior slab

4. Results

Over a period of one year, a total of eleven fascio cutaneous flaps were performed. 9 patients were male, 2 patients were female between the age of 31 to 48 years.

The causal factor for the defect were sole avulsion in-5 cases, tendo Achilles infection-2 cases and posttrauma anterior leg defects in-4 patients. All cases presented late between earliest of 3 weeks upto one and half year post trauma.

We raised flap ranging from 7 -13 cm s in length to 3-8 cm width which we templated according to the wound. The pivot point was kept at least 5 cms above the lateral malleolus. At the base we preferred width of pedicle to be atleast 4 cms.

Out of 11 flaps, 8 flaps (73%) showed complete flap survival. Partial flap loss at the edge were found in 2 (18%) for which debridement and resuturing of defects were done and successful results were achieved, infection was found in 1 patient (9%). Numbness of lateral malleolus was reported in 1 case (9%) which eventually recovered. One person had donor site free split skin graft failure which was debrided and repeat skin grafting was placed after a period of 3 weeks.

All patients did not have any problem in weight bearing and performing their daily routine activities. 2 patients were concerned about the appearance.

5. Discussion

Lower limb defects around the foot and ankle are difficult to manage due to notoriously poor wound healing secondary to poor blood supply. With sural flap, we could achieve excellent results to cover skin around distal leg, foot and ankle. Reconstruction of the lower leg and foot continues to

be one of the most challenging tasks for the reconstructive plastic surgeon. An unreliable lower limb subdermal plexus translates to notoriously poor wound healing using cutaneous flaps^[11]. Following the developments in flap surgery, pedicled fasciocutaneous flaps and free flaps have been used. The introduction of distally based sural fasciocutaneous flap provides reliable and effective method to cover skin defects of distal leg, foot and ankle^[9,13]

According to the literature that needed repair, include those resulting from road traffic accidents, non healing skin wounds, chronic venous ulcers, chronic osteomyelitis in diabetics, contractures, gangrene, unstable scars, cancer resections, and electrical burns^[6,12]. The major cause of defects in our patients included trauma due to road traffic accidents, similar to some other studies^[2,7]. The lower leg and heel were the most frequently involved sites in our study. The sural based flap has been shown to be more reliable and a better choice than the lateral supramalleolar flap (another distally based fasciocutaneous flap used in the distal lower extremity).

The flap has been shown to be successful in diabetic and medically compromised patient^[15]. Anterior and posterior tibial vessels occlusion and varicose leg veins are not considered an absolute contraindication to the use of a distally based sural flap^[8,14]. An occluded peroneal artery is however considered a contraindication. One patient was a non insulin dependant diabetic for the last 10 years. His flap used for tendo achilles coverage also survived completely with an uneventful recovery

We noted complete flap survival in 73% of our patients, partial flap loss in 18%, infection in 9% and complete loss in non, being comparable to other studies. Successful coverage of the defect was achieved in our study in (100%) of patients: complete survival 73% and marginal necrosis 18% (the necrosed area was debrided, flap advanced and resutured to the defect). A meta-analysis of 50 articles that report the use of 720 distally based sural flaps, suggested 82% success rate of the flap. Complete flap necrosis was reported in 3.3%, and partial or marginal flap necrosis in 11%.^[16] Similarly, a detailed retrospective analysis of sural flap complication rate was recently performed on a series of 70 consecutive flaps. The complication rate reported was 59% (41 of 70 flaps), partial necrosis was noted in 17% and complete necrosis in 19% flaps.^[17] Akhtar² in his study of 84 patients observed flap survival in 78.5%, partial necrosis in 16.5% and complete necrosis in 9.5%. The flaps that showed marginal or partial necrosis showed postoperative congestion. One of these was used for anterior tibial defect while others were for heel and dorsum of foot defects. Various techniques have been adopted to increase the blood flow and hence the survival of the flap. These are: keeping the pedicle at least 4 cm wide, including a gastrocnemius muscle cuff especially when the flap is designed higher in the leg and sural flap delay procedures especially when large flaps are planned or if very distal foot defects need coverage^[18-21]. Al-Qattan has also used the muscle cuff as a plug for small lower limb defects following debridement of infected/necrotic bone^{[22][23]}

Studies have shown the usefulness of doppler in such cases^[16]. It is therefore recommended that in cases with extensive trauma, doppler identification of the perforators be done before deciding on the pivot point.

Many authors have suggested that venous congestion, and not lack of arterial supply, is the most significant reason for flap necrosis^[17]. The fundamental problem is the presence of venous valves that can prevent the retrograde flow of blood out of the flap inspite of the venous collateral vessels. The methods reported to improve venous outflow are exteriorising the pedicle^[24], intermittent drainage of short saphenous vein^[16], leaches, and the supercharging of the flap by anastomosing the proximal end of the lesser saphenous vein to a vein in the recipient defect^[25]. In our patients that experienced marginal or partial loss venous congestion was noted postoperatively. We exteriorized the pedicle in all our cases. Notable improvement in the congestion of flaps was seen in these cases

6. Conclusion

Reverse sural fascio cutaneous flap is one of the best available flaps for soft tissue defect management around foot and ankle. It can be done in single stage with minimal donor site morbidity. It has constant blood supply and wide range of rotation and a less bulkier coverage. It is technically less demanding, less time consuming. Techniques such as delaying flap surgery, multiple punchers exteriorizing the pedicle, adequate debridement of recipient site are most important factors for graft success. If properly performed reverse sural artery based flap is reliable and consistent source for complex wounds around proximal foot and ankle.

References

- [1] Fraccalvieri M, Bogetti P, Verna G, Carlucci S, Favi R, Bruschi S. Distally based fasciocutaneous sural flap for foot reconstruction: a retrospective review of 10 years experience. *Foot Ankle Int* 2008;29:191-8.
- [2] Akhtar S, Hameed A. Versatility of the sural fasciocutaneous flap in the coverage of lower third leg and hind foot defects. *J Plast Reconstr Aesthet Surg* 2006;59:839-45.
- [3] Xu G, Jin LL. The coverage of skin defects over the foot and ankle using the distally based sural neurocutaneous flaps: Experience of 21 cases. *J Plast Reconstr Aesthet Surg* 2008;61:575-7.
- [4] Ahmed SK, Fung BK, Ip WY, Fok M, Chow SP. The versatile reverse flow sural artery neurocutaneous flap: A case series and review of literature. *J Orthop Surg Res* 2008;3(1):15-20.
- [5] Chen SL, Chen TM, Wang HJ. The distally based sural fasciomusculocutaneous flap for foot reconstruction. *J Plast Reconstr Aesthet Surg* 2006;59:846-55.
- [6] Pirwani MA, Samo S, Soomro YH. Distally based sural artery flap: A workhorse to cover the soft tissue defects of lower 1/3 tibia and foot. *Pak J Med Sci* 2007;23:103-10.
- [7] Raveendran SS, Perera D, Happuharachchi T, Yoganathan V. Superficial sural artery flap-a study in 40 cases. *J Plast Reconstr Aesthet* 2004;57:266-9
- [8] Hsieh CH, Liang CC, Kueh NS, Tsai HH, Jeng SF. Distally based sural island flap for the reconstruction of a large soft tissue defect in an open tibial fracture with

occluded anterior and posterior tibial arteries-a case report. *Br J Plast Surg* 2005;58:112-5.

- [9] Masquelet AC, Romana MC, Wolf G. Skin island flaps supplied by the vascular axis of the sensitive superficial nerves: anatomic study and clinical experience in the leg. *Plast Reconstr Surg* 1992;89:1115-21.
- [10] Hasegawa M, Torji S, Katoh I, Esaki S. The distally based superficial sural artery flap. *Plast. Reconstr. Surg* 1994;93:1012-6.
- [11] Hallock GG. Lower extremity muscle perforators flap for lower extremity reconstruction. *Plast reconstr Surg* 2004;114:1123-30.
- [12] Chen SL, Chen TM, Chou TD, Chang SC, Wang HJ. Distally based sural fasciocutaneous flap for chronic osteomyelitis in diabetic patients. *Ann Plast Surg* 2005;54(1):44-8.
- [13] Mozafari N, Moosavizadeh SM, Rasti M. The distally based neurocutaneous sural flap: a good choice for reconstruction of soft tissue defects of lower leg, foot and ankle due to fourth degree burn injury. *Burns* 2008;34(3):406-11.
- [14] Cavadas PC, Bonanand E. Reverse-flow sural island flap in the varicose leg. *Plast Reconstr Surg* 1996;98:901-2.
- [15] Koladi J, Gang RK, Hamza AA *et al.* Versatility of the distally based superficial sural flap for reconstruction of lower leg and foot in children. *J Pediatr Orthop* 2003;23:194-8.
- [16] Follmar KE, Baccarani A, Steffen P, Baumeister L, Levin S, Erdmann D. The distally based sural flap. *Plast Reconstr Surg* 2007;119:138-48.
- [17] Baumeister SP, Spierer R, Erdmann D *et al.* A realistic complication analysis of 70 sural artery flaps in a multimorbid patient group. *Plast Reconstr Surg* 2003;112:129-40.
- [18] Chen SL, Chen TM, Wang HJ. The distally based sural fasciomusculocutaneous flap for foot reconstruction. *J Plast Reconstr Aesthet Surg* 2006;59:846-55.
- [19] Foran MP, Schreiber J, Christy MR, Goldberg NH, Silverman RP. The modified reverse sural artery flap for lower extremity reconstruction. *J Trauma* 2008;64:139-43.
- [20] Tosun ZO, Zkan A, Karacor Z, Savaci N. Delaying the reverse sural flap provides predictable results for complicated wounds in diabetic foot. *Ann Plast Surg* 2005;55:169-73.
- [21] Ulrich MD, Bach, Alexander D, Polykandriotis E, Juergen K, Horch RE. Delayed Flap for Staged Reconstruction of the Foot and Lower Leg. *Plast Reconstr Surg* 2005;116:1910-7.
- [22] Al-Qattan MM. The reverse sural artery fasciomusculocutaneous flap for small lower-limb defects: the use of the gastrocnemius muscle cuff as a plug for small bony defects following debridement of infected/necrotic bone. *Ann Plast Surg* 2007;59:307-10.
- [23] Al-Qattan MM. The reverse sural fasciomusculocutaneous "mega-high" flap: a study of 20 consecutive flaps for lower-limb reconstruction. *Ann Plast Surg* 2007;58:513-6.
- [24] Maffi TR, Knoetgen J, Turner NS, Moran SL. Enhancing survival using the distally based sural artery interpolation flap. *Ann Plast Surg* 2005;54:302-5.
- [25] Tan O, Atik B, Bekerecioglu M. Supercharged reverse-flow sural flap: a new modification increasing the reliability of the flap. *Microsurgery* 2005;25:36-43. d ankle.
- [26] sural nerve preservation in reverse sural artery based flap - case report Emmanuel Esezobor, Osita C Nwokike, Segun Aranmolate