

Chewing Muscles and the Pathologies Related to their Disorders

Mimoza Canga MD, PhD¹, Vito Antonio Malagnino MD, DDS²

¹University of Medicine Tirana, 9400 Albania

²Sapienza University of Rome, 00185 Italy

Abstract: *As a dentist doctor I have seen a lot of cases when patients come for check outs about headaches or other symptoms without knowing where those come from. These symptoms are very degrading for these patients especially when they have experienced those for a long time and are not sure what to do anymore. Apparently their problems come from disorders of chewing muscles and their temporal mandibular joints. In order to clarify the problems of chewing muscles and their impact on patient health, I have reviewed some articles about the causes of these types of disorders. This revision has revealed that their findings are consistent with each other. The problems of chewing muscles and their joint pathologies are not totally known form the medical doctors and most of the time the patients suffer from pain in the mouth, headache, and limited mouth opening for a long time before they come and see a dentist. Clarifying the causes of these pathologies, the overall knowledge for these diseases, their effects on the body muscles and joints from the head to toes or the other way around, treatments and recommendations are very important not only for the patient but the for the medical referring staff also.*

Keywords: Chewing muscles, headache, malocclusion, the temporal-mandible joint.

1. Introduction

Chewing muscles are an important part of the facial muscles (Masseter muscle, Temporal muscle, Pterigoideus intern muscle, Pterigoideus extern muscle)[1]. Like any other types of muscles they suffer from different pathologies which affect their function [2]. These pathologies are caused by facial trauma, tooth grinding or problems of the position of the mandible. The muscles' pathologies relate also to the joint (two temporo- mandibular joints) disorders [2]. Having both muscle and joint problems makes patients suffer more and it takes a long time and various treatments to cure them. The patient has symptoms like headaches, neck ache, limited mouth opening etc. These symptoms need many treatments starting from muscle relaxing agents during the night, physical therapy and TEENS. Two of the most known and frequent pathologies are the recurrent parotitis of the youth and the syndrome of facial pain [6], [7].

The knowledge for these diseases, their effects on the body muscles and joints from the head to toes, and the other way around, the treatments and recommendations for the patient is very important. The patient and the medical staff, especially the dentists and the nurses who work in the dentist offices, need to know these pathologies and the effects that they have on the patient. The treatment and the recommendations are very important for the patient to follow, in order to feel better[5]. Some of the recommendations are the recognition of the symptoms and going to the dentist as soon as possible, correctly following the treatments in order to avoid the complications of the muscle damage and the other joints of the body which causes other problems in the posture of the patient.

The aim of this review is to evaluate the chewing muscles' pathologies and their impact on the joints, in order to increase the knowledge of the patients about these diseases, and when to ask for proper medical help in order to avoid the unnecessary complications.

2. Anatomy

The chewing process is performed from four main muscles:

1. Masseter muscle
2. Temporal muscle
3. Pterigoideus intern muscle
4. Pterigoideus extern muscle

Chewing muscles are all innervated by Trigeminal nerve (the 5th cranial nerve), more exactly from mandibular nerve. In humans the mandible is connected to the temporal bone with the temporal- mandibular joints. These muscles originate from cranium and are fixed on the mandible. Masseter muscle has a square shape, is located on the lateral fasciae of the mandible root and is an elevator muscle. It is composed by the superficial head and the deep head located up and back. The superficial head originates from the anterior 2/3 of the inferior margin of the zygomatic arch to be fixed then in the lateral fascia of the mandible angle. The deep head originates from the posterior 2/3 of the inferior margin of the zygomatic arch and ends on the lateral margin of the root of the mandible. The masseter muscle is close to buccinator muscle and corpus adiposum of the cheek. The temporal muscle is located on the temporal fosse and has a triangular shape. It is located for the interior wall of temporal fossa, the superior 2/3 of the deep temporal fascia and from the medial fascia of the zygomatic arch. It is fixed on the coronoid process of the mandible. The temporal muscle elevates the mandible and takes it toward the back. The interne pterigoideus muscle is located in the medial side of the root of mandible. The muscle originates from the pterigoideus muscle, of the pyramid process of the palatine bone and also from the mascelartuberosity. The muscle ends in the medial fascia of the root of mandible and goes to the mandibular fossa. The interne pterigoideus muscle is also the elevator muscle of mandible.

The extern pterigoideus muscle has two heads: a superior and an inferior one. The first originates from the

infratemporal crest of the sphenomascelfascie of sphenoides, the pyramid process of the palatine bone and mascelartuberosites. The muscle is fixed on the pterigoideus fossa of the mandibular collumn, over the capsule and the temporo –mandibular articular disk. On the lateral side of the muscle there is corpus adiposus of the cheek, the coronoid process of mandible and in the interior side there is the interior pterigoideus muscle. The muscle is crossed by the mascelar artery. The exterior muscle rotates the mandible toward the inside part.

3. The diagnosing in the Posture of Temporo-Manibular Joints

The stomatologicposturology in social environment is a new diagnostic and instrumental approach to prevent head aches, hemicrania and postural disorders. [3,5].The diagnostic approach individualizes a new functional- diagnostic relation to prevent and fix the ascending muscle- skeletal alterations from the feet toward the head and descending from the head toward the feet. This approach is based in scientific data accepted from the clinicians who relate seeing and hearing with the posture. If the two dental arches do not match with each other and both the temporo-mandibular joints are not in harmony with the closing of the dental arch, all these muscles suffer from disorders which can hurt the muscle skeletalapparatus caused by a bad posture which is the body's response to oppose this disharmony.

The instrumental postural diagnoses used are based on:

1. Electromyography; it makes it possible to measure the muscle tone and the posture before and after a rehabilitation phase and makes it possible to notice the best muscular equilibrium by the mouth and body.
2. Kinesiography is a three dimensional study of the mandible movements before and after the therapy.
3. TENS acts by an electrical stimuli, it is easy and without pain accompanied with low frequency, decontracts the chewing muscles and registers the neuro-myo- postural position of mandible.
4. Stabilizing supportive elements that test the occlusion- postural system. [5]

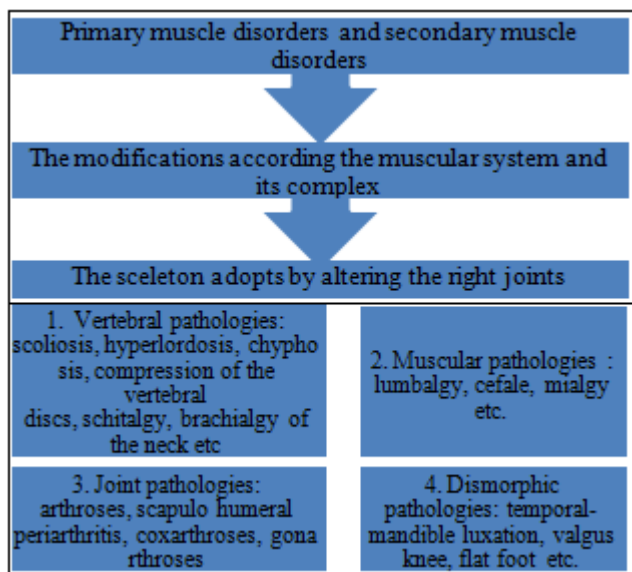


Figure 1: The scheme of the muscle disorders as a result of the muscle damage

Source: Pullinger AG (1991)

4. Muscular and Joint Disorders

The disorders of the temporal-mandible joint include the chewing muscles and temporal- mandible joint. The most frequent symptoms are: pain in these muscles, pain in the pre auricular area and in the mandible joint [2],[4]. This pain is caused by:

- 1)Face trauma (mainly when the trauma is localized in the mandible)
- 2)Inflammatory or degenerative arthritis
- 3)When the mandible moves forward during the chewing act or the deglutinization.
- 4)Muscular stress from the occlusal pre function (serament, brucism, malocclusion)
- 5)Trauma from the psycho emotive reasons

Chewing muscles contract frequently causing pain in the neck, headache and difficulty in opening the mouth. The patient complains about limited opening of the mouth or asymmetric opening.

According to the muscle disorders there are many hypotheses which need to be verified as the following: [9]

- 1) The impact of the toxic agents or infective agents in pregnancy
- 2) Endocrine factors (hypothyroidism)
- 3) Neuro muscular pathologies
- 4) Environmental or alimentary impact

Two of the most known pathologies in facial problems are recurrent parotitis of the youth and the facial pain syndrome. [7, 8,]

Parotitis is a pathology characterized from the inflammation or edema of one or both parotis glands, low saliva flow, pain and fever, pussy secretions. The crisis last from a few days to two weeks and disappear by themselves regardless of therapy. The Stenone compression from the Masseter muscle is thought to be the main reason for this pathology. This muscle contracts chronically and the reason might be a dental malocclusion, a mandilbe malposition and in the cases of a lateral deviated mandible, when it is under the upper jaw, or when it is positioned toward the back. The treatment (during the first phase) includes the decontraction of the Masseter muscle in order to correct the dental malposition and during the second phase we have to put a stable orthodontic aparatus to correct the malocclusion in the final and stable way [3] [9].

Themyo-facial pain syndrome (the spasms of the chewing muscles, intern and extern pterigoideus, masseter and temporal muscles) regardless of normal joint. [4]

This syndrom is a disease that affects the temporal mandible region more frequently in women than men. The most frequent cause is tooth grinding during the night and serament mainly during the night. The most frequent sign is pain during palpation of the chewing muscles and limited opening of the mouth cavity. Tooth grinding causes strong headache in the moment of wakening and gets better during the day. The mandible deviates from the central position in the moment that the patient opens the mouth. The

rentgenography serves only to rule out the arthritis. To keep the teeth in harmony with one another, the dentist can put an occlusive support. [9] Small amounts of benzodiazepines may be given during the night before sleep and their use has been very efficient. Analgesics, NSAID's and Advil are also helpful. Acupuncture relaxes the muscles and relaxants of the muscles lower the tension of the muscles [5]. The physical therapy intervenes by using the sprays and stretching exercise which help the mandible to stretch under tension. Putting ice in the area of pain is very useful too. TEENS favors the decontraction of the muscles. Most of the patients do well in therapy and do not need any treatment for 2 -3 years [5].

5. Recommendations

The patients should be directed to the medical doctor when they experience these types of symptoms in order to have the joint pathology diagnosed.

The patient should follow the therapy correctly in order not to have further pain and complications. The patient should be given the required knowledge about the pathology, the physical therapy and its advantages, using easy and understandable information.

References

- [1] "Anatomia del Gray"-Ed Zanichelli Bologna Vol 1, la 4 Edizione Italiana ISBN 88 -08-17710-6
- [2] Mongini, F. "ATM e muscoli craniocervicofacciali, fisiopatologia e trattamento", Sao Paolo 1998, p 274.
- [3] Planas. "P Reabilitaao neuro-occlusal" 2-ed Rio de Janeiro :medsi 1997
- [4] Friction JR, Dubner R, "Orofacial Pain and Temporomandibular Disorders" Raven Press 1994
- [5] Olekson JP "Orofacial Pain Guidelines for Assessment, diagnosis and Management " Quintessence Pab 1996.
- [6] Palla S, "Mioartropatie del Sistema Masticatorio e Dolori Orofaciali", RC Libri 2001.
- [7] Geterud A, Linvall AM, Nysten O, " Follow-up study of recurrent parotitis in children". ANN OtolRhinolLaryngol 1998; 97:341-6
- [8] Maynard JD, " Recurrent parotid enlargement". BR J Surg 1965; 52:784-9
- [9] Bernkopf E, Maraggia A, Anselmi F. "Ortodonzia e cefalee miotensive nel bambino". Medico e bambino 1990; 9 :40-4

Author Profile



Dr. Mimoza Canga is laureate at the University Sapienza, Roma- Italy. PhD University of Tirana. Currently works in the University of Vlora, Department of Public Health, Vlora -Albania.



Professor Vito Antonio Malagnino is laureate in the Faculty of the Medicine with excellent grades. Is specialized in odontostomatology University of Roma- Sapienza, Italy. He is the chief of the endodontics in Sapienza- University.