

Giant Fibroadenoma of Breast: A Diagnostic Dilemma

Sangamesh B Tondare¹, Siddaganga Mangshetty²

Bidar, Karnataka, India

Abstract: *Giant fibroadenoma is a rare disease. Fibroadenoma increase in size and may show lactational histological changes. Treatment usually ranges from simple excision to subcutaneous mastectomy with reconstruction of breast.*

Keywords: Giant Fibroadenoma, Lactation, Excision, Histopathology

1. Introduction

Fibroadenomas constitute for wide spectrum of benign breast disorders. Giant fibroadenomas, greater than 5 cm or 500 g, can be associated with significant deformity, raising suspicion for malignancy, and requiring surgical excision (1-3).

2. Case History

A 21 year old lactating mother came with history of Right breast lump since one year. Initially the lump was small in size and is progressively increasing in size to attain the present size. Patient had pain in lump since 1 week. There were no other complaints. Patient had delivered a baby one year back, when she noticed a lump in her right breast.

Local examination revealed a lump in right breast measuring 10*8*5* cms in the upper outer quadrant, in the subcutaneous plane, which was freely mobile. No axillary lymph nodes were enlarged. Provisional diagnosis of fibroadenoma was made. FNAC revealed stromal tumour of breast. USG of breast showed well defined hypo echoic, heterogenous mass in upper outer quadrant of breast probably Phylloides tumour. With the above diagnosis of fibroadenoma and Phylloides tumour, patient was taken for surgery. No other investigations were done in our Hospital. The patient underwent excision of the breast mass [Figure 1 a) Preoperative b) Intraoperative c) Postoperative].

Histopathological examination revealed a well-circumscribed and capsulated lesion composed of homogenous grey white mass [Figure 2. Showing gross specimen]. The final diagnosis of Giant Fibroadenoma breast was confirmed.

Discussion: Breast masses in young patients are usually benign in nature. The nomenclature of fibroadenoma in younger women is confusing and a plethora of names exists to designate the lesion such as age related term juvenile fibroadenoma and size related term giant or massive fibroadenoma (4). Giant fibroadenomas, have a prominent glandular epithelium and an increased stromal cellularity (5). Breast enlargement can occur in as short as a few weeks, and the mass can double in size within three to six months, growing larger than the existing normal breast tissue (6,7). Nevertheless, the fact that these tumours are unilateral and

have an apparent geographical distribution suggests that other factors, possibly genetic and environmental, could be involved. Giant fibroadenoma occurs predominantly in adolescent/ blacks and in the oriental race (8). Ultrasonography, mammography, magnetic resonance imaging or fine needle aspirations have not been helpful indefinitely differentiating fibroadenoma from phylloides tumor (9). It is essential to know that giant juvenile fibroadenoma may recur after complete excision, and the chance of recurrence becomes less after the third decade [10].

3. Conclusion

Fibroadenomas are one of the most common benign diseases of the breast with varying sizes in all quadrants of the breast. Diagnosis by FNAC is reliable, but the diagnosis and management of large breast tumors is challenging for surgeon, radiologist and pathologist. In the majority of the cases, these tumors are benign and should be treated with breast sparing surgery. Giant fibroadenoma is a uncommon condition and a difficult diagnosis clinically and surgically in a lactating mother.

References

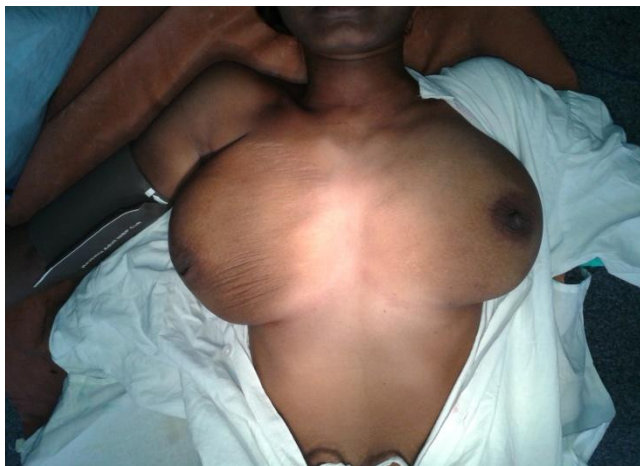
- [1] Chang DS, McGrath MH. Management of benign tumors of the adolescent breast. *Plast Reconstr Surg.* 2007; 120(1):13e-9e. [DOI] [PubMed]
- [2] Chepla KJ, Armijo BS, Ponsky TA, Soltanian HT. Benefits of immediate dermoglandular preserving reconstruction following giant fibroadenoma excision in two patients. *J Plast Reconstr Aesthet Surg.* 2011; 64(9):e244-7. [DOI] [PubMed]
- [3] Park CA, David LR, Argenta LC. Breast asymmetry: presentation of a giant fibroadenoma. *Breast J.* 2006; 12(5):451-61.
- [4] Rattan K, Kumar S, Dhull AK, Kaushal V, Kaur P. Giant Fibroadenoma Mimicking Phylloides Tumor in a Young Female: A Cytological Dilemma. *The Internet Journal of Third World Medicine* 2008; 6:2.
- [5] Baxi M, Agarwal A, Mishra A, Agarwal G, Mishra SK. Multiple bilateral giant juvenile fibroadenomas of breast. *Eur J Surg.* 2000; 166(10):828-30.
- [6] Old Girl: A Case for Breast Conservation. *Breast J.* 2000; 6(6):418-20.

- [7] Cheng PJ, Vu LT, Cass DL, Hicks MJ, Brandt ML, Kim ES. Endoscopic specimen pouch technique for removal of giant fibroadenomas of the breast. *J Pediatr Surg.*2012;47(4):803-7.
- [8] Carl D, Patel V. Surgical problems in the management of the breast. *Am J Obstet Gynaecol* 1985; 1010-5.
- [9] Heilmann T, Leuschner I, Hilpert F, Kumper C , Strauss A, Mundhenke C , et al. Diagnosis and management of an unilateral giant fibroadenoma of the breast in pregnancy. *Arch Gynecol Obstet.* 2012;285(1):235-7.
- [10] S. J. Schnitt, R. R. Millis, A. M. Hanby, and H. A. Oberman, "The breast," in *Sternberg's Diagnostic Surgical Pathology*, S. E. Mills, D. Carter, J. K. Greenson, H. A. Oberman, U. Reuter, and M. Scoler, Eds., vol. 1, pp. 371–372, Lippincott Williams Wilkins Indian, 4th edition, 2004.

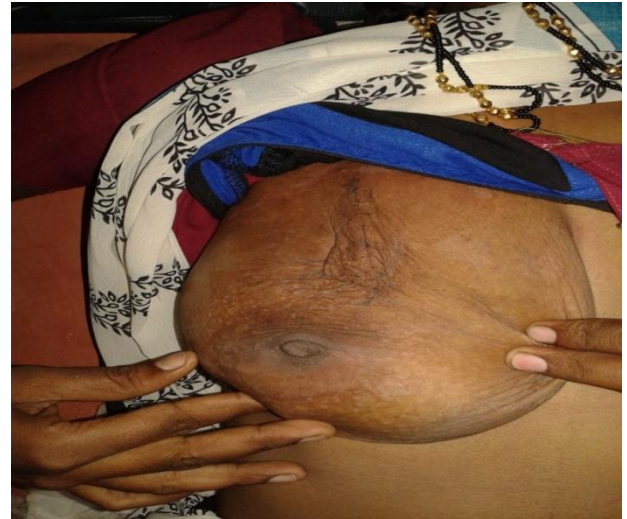

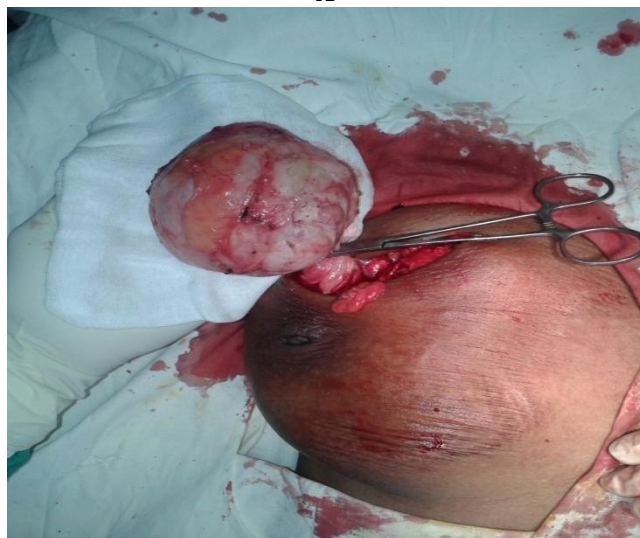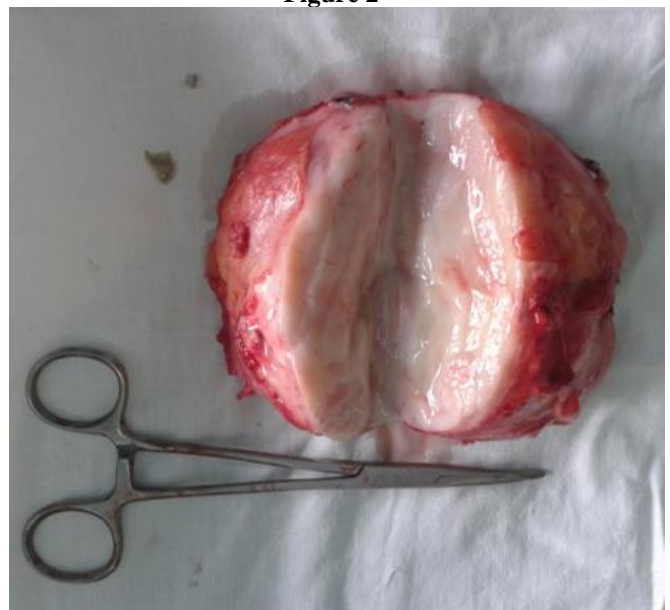
Figure 1

C



A

Figure 2



B