

A Case of Eagle Syndrome Diagnosed by CBCT

Dimitar Yovchev

Medical University – Sofia, Bulgaria, Faculty of Dental Medicine, Department of Imaging and Oral Diagnostic

Abstract: Eagle syndrome is a rare condition related to elongation of the styloid process (SP) or stylohyoid ligament calcification. In Eagle syndrome the elongated SP compresses adjacent anatomical structures – vessels, nerves etc. The clinical signs include facial and neck pain when turning the head or extending the tongue, foreign body sensation, otalgia, tinnitus, dysphagia etc. We present a case of 53 - year - old male with long term mild bilateral pain during neck movements or swallowing. Elongated styloid processes were detected incidentally by CBCT undertaken before implant placement. In cases of presence of non-typical clinical symptoms and CBCT undertaken in maxillofacial region it is recommended to measure and describe SP in order to confirm Eagle syndrome.

Keywords: Cone-Beam Computed Tomography, dental implants, Eagle syndrome, styloid process

1. Introduction

The styloid process (SP) is a needle like part from the temporal bone and it situated down and forward from the inferior surface of the temporal bone. The SP can be found bilaterally ensuring attachment for stylohyoid and stylomandibular ligaments and also for styloglossus, stylohyoideus and stylopharyngeus muscles.

The normal SP length is approximately 20–30 mm. In cases when SP length or the adjacent stylohyoid ligament ossification exceeds this values elongation can be assumed [1]. In 1986 Langlais has proposed a classification of elongated styloid processes according to the type of elongation - normal styloid process, uninterrupted (type 1), pseudoarticulation (type 2), segmented (type 3) [2].

In cases of elongated SP, Eagle syndrome can occur. This is a rare disorder where the elongated SP compresses adjacent anatomical structures – vessels, nerves etc. The symptoms include facial and neck pain upon turning the head or extending the tongue, foreign body sensations, tinnitus, otalgia, dysphagia etc. The compression to the carotid artery may occasionally cause stroke [3-5]. Degenerative or

inflammatory changes in the styloid ligament insertion or rheumatic styloiditis may also cause this syndrome [5].

Two forms of Eagle syndrome are known - the classical stylohyoid syndrome and the vascular one (stylocarotid syndrome).

The treatment of Eagle syndrome is conservative using medical drugs, followed by surgical styloid process resection, in case of persistence or increasing of the complaints [6].

2. Case Report

We present a case of 53 - year old Bulgarian Caucasian male underwent CBCT in order to evaluate his jaws before implant placement. From the medical history he pointed a long lasting mild bilateral pain during swallowing and rotating of the neck. In order to relieve the pain he provided none regular self-treatment taking nonsteroidal anti-inflammatory drugs.

On CBCT crossections and volume rendered (VR) images elongated SPs were found (fig 1). No other abnormalities were detected.

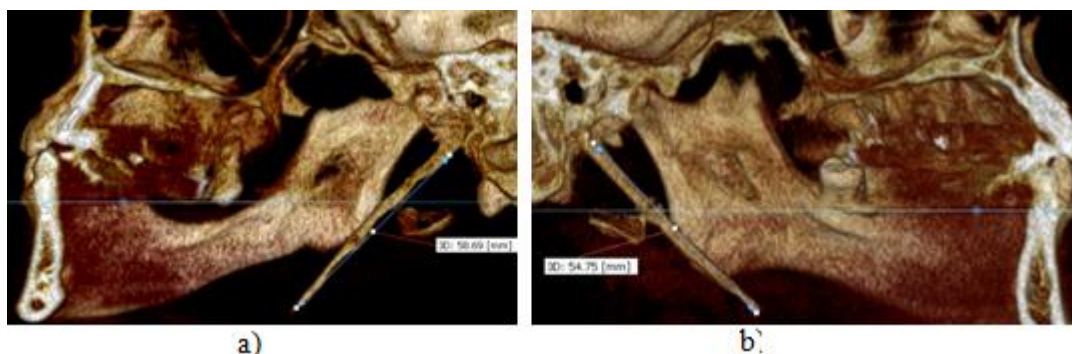


Figure 1: a) Elongated (58.69 mm) right styloid process with pseudoarticulation on VR reconstruction. b) VR image of the left side representing the other elongated (54.75 mm, also with pseudoarticulation) left styloid process.

In our case both styloid processes were with pseudoarticulation (type II) according Langlais classification of the type of elongation [2].

3. Discussion

The etiology and pathogenesis of elongated SP and Eagle syndrome are not clear. Osseous metaplasia of the Reichert cartilage residues, persistence of mesenchymal elements

producing bone tissue in adults, and ossification of the stylohyoid ligament related to endocrine disorders are suggested [7].

Not every case with elongated SP leads to complaints respectively to Eagle syndrome. Only 4 % from the patients with elongated SP have complaints [8].

The symptoms related to Eagle syndrome can be confused with those attributed to a wide variety of facial neuralgias or temporomandibular joint disorders [9].

Elongated SP in Eagle syndrome can be detected using radiographs. They have to be first imaging method according ALARA (As Low As Reasonably Achievable) principle. It is well known that for measurements the cephalometric radiographs are considered more reliable compared to panoramic radiographs, suffering less distortion and revealing approximately real image [10,11]. Panoramic radiographs don't show the orientation of SP [1].

The exact measurements of SP and its relation to adjacent structures can be achieved with CBCT and better with MDCT. CBCT is limited to differentiate soft tissue structures including blood vessels etc., so when vascular form of Eagle syndrome is suspected contrast enhanced MDCT or MRI are more suitable.

In our case the primary reason for CBCT was the implant treatment. The elongated SP was found on the CBCT images incidentally. This finding explained the reason for the mild complaints during swallowing and neck rotating.

In cases of presence of non typical clinical symptoms (facial and neck pain, tinnitus, dysphagia, otalgia and vertigo etc.) and CBCT undertaken in maxillofacial region, it is recommended to measure and describe SP in order to confirm Eagle syndrome.

References

- [1] Gokce C, Sisman Y, Sipahioglu M. Styloid process elongation or Eagle's syndrome: Is there a any role for ectopic calcification? *Eur J Dent* 2008;2:224-228.
- [2] Langlais RP, Miles DA, Van Dis ML. Elongated and mineralized stylohyoid ligament complex: A proposed classification and report of a case of Eagle's Syndrome. *Oral Surg Oral Med Oral Pathol* 1986;61:527-32.
- [3] Carter L. Soft tissue calcification and ossification. In: White SC, Pharoah MJ, eds. *Oral radiology, principles and interpretation*. Missouri: Mosby, 2004: 597-614.
- [4] Chuang WC, Short JH, McKinney AM, Anker L, Knoll B, McKinney ZJ. Reversible left hemispheric ischemia secondary to carotid compression in Eagle syndrome: surgical and CT angiographic correlation. *Am J Neuroradiol* 2007;28:143-145.
- [5] Prasad KC, Kamath MP, Reddy KJ, Raju K, Agarwal S. Elongated styloid process (Eagle's syndrome): a clinical study. *J Oral Maxillofac Surg* 2002;60:171-175.
- [6] Casale M, Rinaldi V, Quattrocchi C, Bressi F, Vincenzi B, Santini D, Tonini G, Salvinelli F. Atypical chronic head and neck pain: don't forget Eagle's syndrome. *Eur Rev Med Pharmacol Sci*. 2008;12(2):131-3.

- [7] Rechtweg JS, Wax MK. Eagle's Syndrome: A Review. *Am J Otolaryngol*. 1998;19:316-21.
- [8] Piakgou M, Anagnostopoulou S, Kouladouros K, Piakgos G. Eagle's Syndrome: A Review of the Literature. *Clinical Anatomy* 2009; 22: 545-558
- [9] Andrade KM, Rodrigues CA, Watanabe PCA, Mazetto MO. Styloid process elongation and calcification in subjects with TMD: Clinical and Radiographic Aspects. *Braz Dent J* (2012) 23(4): 443-450
- [10] Ongkozowito EM, Dieleman MMJ, Kuijpers-Jagtman AM, Mulder PGH, Van Deck JW. Linear mandibular measurements: comparison between orthopantomograms and lateral cephalograms. *Cleft Palate Craniofac J*. 2009;46:147-153.
- [11] Houston WJB. The analysis of errors in orthodontic measurements. *Am J Orthod Dentofac Orthop* 1983;83:382-390.

Author Profile

Assistant Professor **Dr Dimitar Yovchev**, PhD, Medical University-Sofia, Bulgaria, Faculty of Dental Medicine, Department of Imaging and Oral Diagnostic. He has experience more than 14 years in the field of diagnostic imaging. His main interests are in cone beam computed tomography and rapid prototyping, ultrasound and plain x ray diagnostic in maxillofacial region.