

Comparative Study of the Effectiveness of the Octyl-2-Cyanoacrylate as a Tissue Adhesive for Skin Closure & Skin Closure by Non Absorbable Sutures (Nylon)

Dr. Shahaji Chavan¹, Dr. Anuradha Dnayanmote², Dr Nilesh Sinha³

Abstract: *What is the best type of closure or the best technique for closing wounds? The answer is straightforward: the one that meets the need of the hour. Historically man has utilized his intelligence and the materials that were known to him to close and protect wounds.*

Keywords: Octyl-2-Cyanoacrylate

1. Introduction

Although sutures are considered the “gold standard” for wound closure, they sometimes produce a less favorable result than staples, tapes, and adhesives.

A tissue adhesive is defined as substance used to cause adherence of one tissue to another tissue or a biological tissue to non-tissue surfaces such as prosthesis

The first cyanoacrylates that were widely used were butyl cyanoacrylates. However because of their relatively low strength and brittle nature, their use was limited to simple short, low tension lacerations and surgical incisions.

With the development of octyl-cyanoacrylate, which is a stronger and more flexible alternative the use of TSA's greatly expanded.

They are non invasive and do not cause pain on application, the TSA may be used without any anesthesia: and sloughs of within 5-10 days.

2. Aims and Objectives

Most of the clinical trials are conducted in western countries which cannot be directly extrapolated and applied to populations living in developing countries like India due to geographical differences.

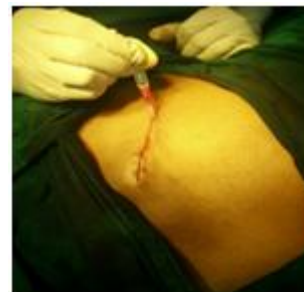This further highlighted the need to conduct trial to evaluate the product.

Comparison was done under following objectives

- 1) To compare the time required for suturing with sutures & TSA
- 2) Cosmesis
- 3) Comparisons of surgical site infections & wound dehiscence
- 4) Other Complications like allergic reactions
- 5) Cost Effectiveness

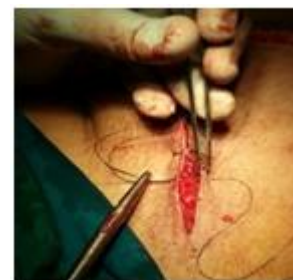3. Methodology

- Prospectively study of 100 patients was done. Patients were divided into two equal groups. All cases of elective inguinal hernia surgery were included in this study.
- Factors influencing wound healing like nutritional factors (Anaemia, Vitamin deficiency, malnutrition) were taken into consideration.
- Patients with diabetes, immunocompromised status, skin infections, known allergic reactions were excluded.
- The glue was applied over the wound
- Edges with film of glue extending 5mm on either side of the edge.



The wound was held together till it was dry to allow complete polymerization of glue as was evident by opacification of film.

Dressing was done which was removed on 3rd day and patient was allowed to take bath on 7th day.



In second group nylon sutures were used and vertical mattress sutures were taken. Wound was inspected on 3rd postoperative day and sutures were removed on 8th and 10th postoperative day.

Table 5. *The Stony Brook Scar Evaluation Scale*

Scar category		Points
Width	>2 mm	0
	≤ 2 mm	1
Height	Elevated/depressed in relation to surrounding skin	0
	Flat	1
Color	Darker than surrounding skin	0
	Same color or lighter than surrounding skin	1
Hatch marks/Suture marks	Present	0
	Absent	1
Overall appearance	Poor	0
	Good	1

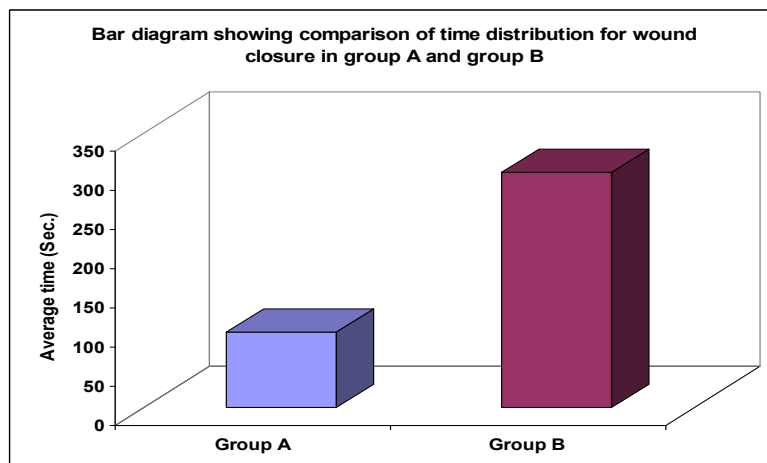
Stony Brook Scar Evaluation Scale was used for evaluation scar at 10th postoperative day

4. Results

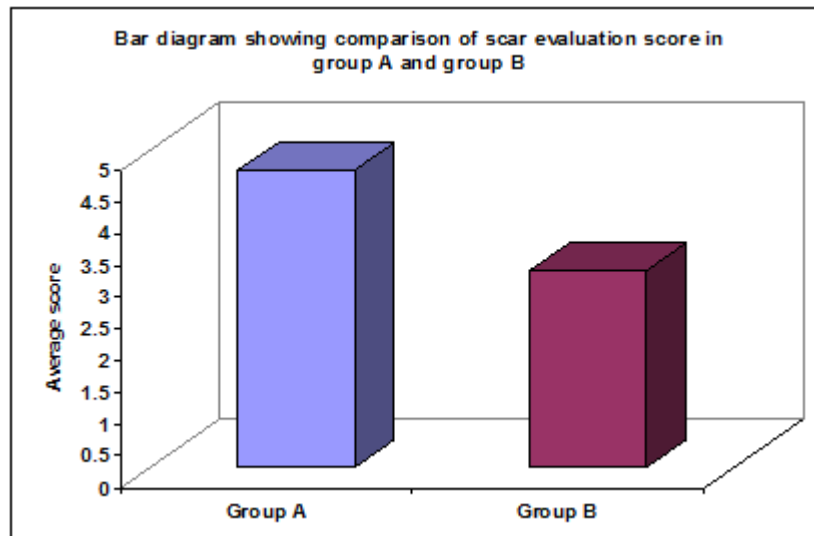
- Both the group had no statistically significant difference in the age distribution and were comparable. (p value > 0.05)

- Wound infection was present only in 1 case with TSA while it was present in 3 cases with nylon sutures.
- In most cases glue came off spontaneously while in 5 cases acetone solution was required to wipe off the glue.
- Nylon suture costs 140 Rs while TSA cost 800Rs and are not cost effective.

Wound closure	Group A		Group B		Z Value	P Value
	Mean	SD	Mean	SD		
Time (sec)	96	10.01	300.22	47.16	29.95	<0.0001



Scar evaluation	Group A		Group B		MW test Z Value	P Value
	Mean	SD	Mean	SD		
Score	4.68	0.68	3.10	0.46	8.09	<0.0001



5. Discussion

- Cyanoacrylate glue adhesives were used extensively in emergency department for closure of lacerated wounds especially pediatric wounds in western countries.
- Studies suggest that TSA take less time compared to sutures have lesser rate of infection and better cosmetic results and better acceptance by patients. These results are comparable with our study results.
- Literature shows very few studies on TSA application in clean surgical wounds.
- There are varying reports regarding antibacterial properties of cyanoacrylate glue.

6. Conclusion

Clean surgical wounds can be safely closed with use of cyanoacrylates as they take less time; provide better cosmetic results and better acceptance

References

- [1] Sipos P, Gyory H, Hagymasi K, Ondrejeka P, Blazovics A. Special wound healing methods used in ancient Egypt and in the mythological background. *World J Surg.* 2004;28(2): 211-216
- [2] Lumsden AB, Heyman ER; Closure Medical Surgical Sealant Study Group. Prospective randomized study evaluating an absorbable cyanoacrylate for use in vascular reconstructions. *J Vasc.* 2006;44(5):1002-1009
- [3] Singer AJ, Perry LC, Allen RL Jr. In-vivo study of wound bursting strength and compliance of topical skin adhesives. *Acad Emerg Med.* 2008;15(12):1290-1294
- [4] Singer AJ, Quinn JV, Clark RE, Hollander JE. Closure of lacerations and incisions with octylcyanoacrylate: a multi-center randomized clinical trial. *Surgery* 2002;131(3):270-276
- [5] Singer AJ, Arora B, Dagum A, et al. Development and validation of a novel scar evaluation scale. *Plast Reconstr Surg* 2007;120:1892-97.
- [6] Brig BM Nagpal, VSM, Maj Gaurav Kumar, Maj GS Nagi, Wg Cdr Pradeep Singh (Retd) MJAFI 2004; 60 : 131-133