

# Effects of Hyaline Cartilage Tissue Transplant on Finger Regeneration in Mouse

Sharma, R. L.<sup>1</sup>, Sharma, Navneet<sup>2</sup>

Molecular developmental Biology Laboratory, Department of Zoology, M.D.S. University, Ajmer (Rajasthan), India

**Abstract:** *Mammals, which were designated as non-regenerating models among vertebrates also can be made to regenerate the lost structures if conditions favoring regeneration are provided, near the amputated site particularly during the early post amputational periods. Such findings would definitely show the way to bio-medical scientists to search means, so that human beings suffering from amputational injuries, with permanent disabilities can be provided reparative therapy with the help of tools of tissue engineering. Finger regeneration ability in mammals is very poor. It can be induced by Allografting of Hyaline cartilage at amputated finger. Studies carried out on transplantation of cartilage tissues near the wound surface after amputation of finger through middle phalanx have shown many interesting results.*

**Keywords:** Regeneration, Amputation, hyaline cartilage, transplantation

## 1. Introduction

The regeneration is restoration of lost part of organ or body through several steps by acquisition of normal pattern of internal organization and external morphology. Restitution of the missing structure by the rest of an organ or body part of an animal is known as regeneration. (Wallace-1981).

Various animal groups of entire animal kingdom show variations in regenerative ability of the lost structure. Until 1974 mammals were thought to possess very poor or no regenerative abilities. Illingsworth in 1974, reported about regeneration of lost or crushed fingertips in young children in certain clinical cases, provided amputation level was in front of the distal most inter-phalangeal joint. In these cases restitution of fingertips was observed within 3 to 4 months provided treatment of wound was restricted to aseptic dressings only. Whenever, the wound was sutured with the skin over the wound surface, it generally resulted in failure of regeneration. There was no regeneration when the level of amputation was more proximal i.e. through the mid phalanx.

In higher animals including human beings many wear and tear processes continue from beginning of body development until death. The outer layer of skin, Blood cells, Sperm cells, uterine lining, Intestinal mucosa etc. are replenished as per requirement. Another reparative phenomenon that occurs in higher mammals is the acquisition of functions by existing tissues, when part of the organ ceases to function in certain disease conditions or is removed. Sharma, 2002 reported that traumatization of amputated finger, improved quality of regeneration by improving bone growth and formation of healthy cartilage at distal end

Extensive studies on regenerative ability of mouse finger were carried out in the laboratory of Sharma(1988) at the MDS University Ajmer (India) who reported regeneration of distal part of spatula in mouse at embryonic stages using intra amniotic surgical techniques and embryo culture techniques and found that finger amputation through distal part of the autopodium at 16<sup>th</sup> day of gestation stage of embryo show complete regeneration (Archana, 1992).

Amputation through the distal phalanx in adult mice resulted in complete restitution of lost limb elements confirming the results of Borgens (1982). It was found that those cases where hyaline cartilage of head of middle phalanx or base of distal phalanx persists normally show good regeneration.

Hyaline cartilage is the initial skeleton of the foetus. It is the precursor to bones that will develop by the process of endochondral ossification. While endochondral bone development is in progress, hyaline cartilage serves as an epiphyseal growth plate, and this cartilaginous plate remains functional as long as the bone grows in length. In the long bone of the adults hyaline cartilage is present only at the articular bone surface and is known as articular cartilage. Hyaline cartilage is also present in the adult as the skeletal unit in trachea, bronchi, larynx, and nose and at the ends of the ribs as costal cartilage.

It has been mentioned that mouse show a very limited ability to regenerate finger elements. This too is restricted to regeneration of fingertips after amputation injury at the distal most phalanx. In the recent years Molecular Biology researches in this area have indicated that regeneration can be induced in non-regenerative cases if suitable environment is provided to the cells, which help in regeneration. The environmental tissues of the stump allow the formation of cartilage and bone, and this is proposed that limb formation could be possible by supplying competent cells endogenously or exogenously.

Fernando et al., (2011) studied that amputation of the distal region of the terminal phalanx of mice causes an initial wound healing response followed by blastema formation and the regeneration of the digit tip. Thus far, most regeneration studies have focused in embryonic or neonatal models and few studies have examined adult digit regeneration.

We are faced with a limb-severing injury, any regenerative attempt would endeavour to accelerate the pace at which the tissue heals to a clinically relevant/functional state. The science of limb regeneration can be approached from three different angles, developmental biology; regenerative medicine; and tissue engineering (See et al., 2013).

Volume 5 Issue 10, October 2016

[www.ijsr.net](http://www.ijsr.net)

Licensed Under Creative Commons Attribution CC BY

A more contemporary approach to the stimulation of regeneration is the application of cellular engineering principles, which involve strategies such as the implantation of the cultured cells, with or without appropriate substrate. Among the many tissues in mammals, bone has considerable power of regeneration and is a prototype model for tissue engineering based on morphogenesis. As concluded by the studies carried out by the scientists of center for tissue regeneration and repair, University of California, Implantation of demineralized bone matrix into subcutaneous sites results in local bone induction. Hand/upper extremity transplantation is the most common form of vascularized composite allotransplantation performed to date. An Update of worldwide outcomes is reported (Shores et al., 2015).

In view of this the objective is to find means to induce regeneration in otherwise non-regenerating cases by cartilage transplantation.

## 2. Materials and Methods

Experiments related to proposed study were carried out on closely inbred *Swiss albino* mice. Studies consisted of the following main lines of research.

- 1) To study the cellular and tissue organization of the finger in the distal and middle phalanx to find the precise site for transplantation of inducing factors.
- 2) To find means to induce regeneration in otherwise non-regenerating cases because normally amputation through middle phalanx in adult mouse does not show any regeneration.
- 3) Attempt to induce regeneration, by transplantation of certain tissue with known developmental potencies. e.g. hyaline cartilage.

The amputated animals were kept separated from the breeding colony in the animal house and germ free and aseptic conditions were maintained. The 3<sup>rd</sup> finger of hind limb of 4-week-old mouse is about 5 mm long including nail. Skeleton of finger is well, ossified. Dense hair are present on the dorsal side of finger. The saggital and longitudinal section (Fig. 1 & 2) of finger shows three phalanxes namely distal phalanx, middle phalanx and proximal phalanx. Nail is present at the distal phalanx and is curved.

### Amputation procedure

Adult mice (4 week  $\pm$  1 day<sup>7</sup>) were anesthetized by placing them in a sterile chamber where diethyl ether soaked cotton was placed near the nostrils of the experimental animal. It took about ½ to 2 minutes for anesthetization. Third finger of hind limbs were amputated using a sterile surgical blade under surgical microscope below the head of the middle phalanx.

### Experimental Design

Transplantation experiments were carried out on 4-week-old Swiss albino mice. Following amputation through the shaft of the middle phalanx, animals were divided into the following groups

### Group I-- Control Group

After amputation animals of control group were left for healing under clean and sterile conditions in cages without any further treatment. Observations were made on 60<sup>th</sup> day post amputation

### Group II—Tissue Transplanted treated group

The tissue was transplanted in animals seven days after amputation of middle finger. The piece of hyaline cartilage was separated in a cavity slide from the head of the middle phallanx of the 4-week-old mouse and was transplanted

### Transplantation procedure

The transplantation was performed under aseptic conditions. First of all an incision was made on the latero-ventral side of finger just near the base of the middle phalanx. A tunnel was made through it and the tissue to be transplanted was pushed to the amputated shaft of the middle phalanx.

The care was taken that the transplant does not come out of the tunnel. The transplantations were made after 7<sup>th</sup> day of amputation. The post amputational developments after transplantation were examined in the control and transplanted groups on the 60<sup>th</sup> day for morphological developments.

### Morphological and Histological Analysis

For the analysis of control and treated post amputational development (morphology and histology) fingers (Fig. 3 & 4) amputated through the shaft of middle phalanx were fixed in Bouin's solution.

## 3. Observation and Results

### Control:

On the 5th day after amputation, healing was in progress wound epidermis arise from the cut margins towards the center and healed up the wound surface. Scab material was present at the apical end of the stump.

On the 10<sup>th</sup> day post amputation, the stump showed disappearance of scab. The wound surface was covered by the wound epidermis. On the 40<sup>th</sup> day the amputated finger stump shows simple healing of wound epidermis. The wound healing was completed by the 60<sup>th</sup> day post amputation. The stump surface was inflattened and was covered with dense hair (Fig. 5 & 6). The distal most ventral ridge was not regenerated and the thick dermal pad was also not visible as supported by histological studies (Fig. 7)

### Treated:

This group of animals had been treated with a piece of hyaline cartilage, separated from the head of middle phalanx in 4-week-old mice. On the 10<sup>th</sup> day after transplantation the finger tissue showed complete wound healing and partial regeneration of the ventral ridge. On 40<sup>th</sup> day morphological observation clearly indicated regeneration of lost fingertip. The regenerated part included a nail structure, which was still in process of development. The distal most ventral ridge had also regenerated completely.

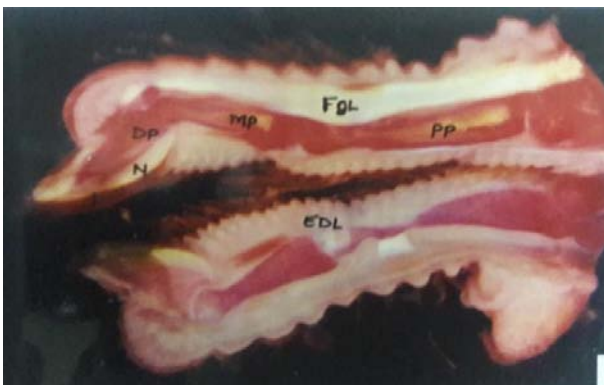
On 60<sup>th</sup> day growth of the nail was complete but the regenerated nail was curved (Fig. 8 & 9).

Histological pictures on 60<sup>th</sup> days post transplantation showed restitution of nearly all tissue removed after amputation. The head of middle phalanx was covered by a layer of hyaline cartilage (Fig 10). Similarly, hyaline layer formed the basal plate of the distal phalanx. Differentiation of nail had also advanced as indicated by well-formed nail plate made of keratinised horny tissue. The regenerated ventral ridge showed hair follicles and blood vessels in the dermal region. The nail bed, nail plate and overlying skin covering the nail root are distinct. The nail was soft due to lesser degree of keratinization. Epidermis covering the ventral region was 6-8 cell layers thick. Amputated parts of the head of the middle phalanx end distal phalanx were restituted. Both tendons showed regeneration and their insertion at their respective sites.

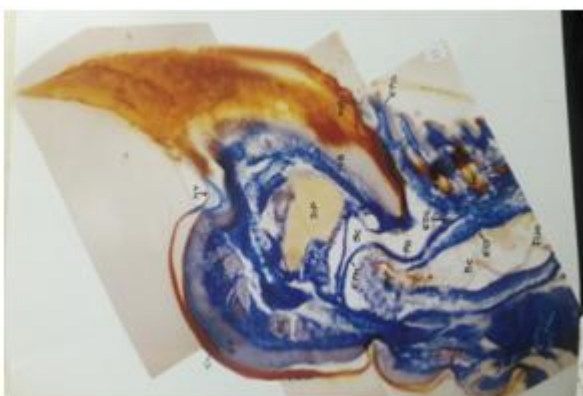
#### 4. Conclusion

Studies carried out on transplantation of different tissues near the wound surface after amputation of finger through middle phalanx have shown many interesting results. The stumps, which do not normally regenerate after amputation through middle phalanx, show restoration of normal pattern in many cases with allograft of hyaline cartilage taken from the head of the middle phalanx of adult mouse

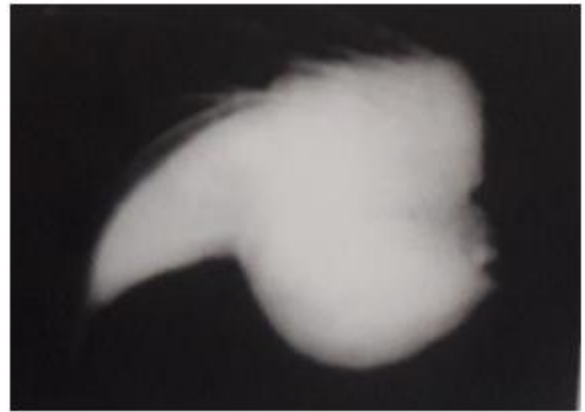
#### Morphological and histological figures of middle finger of hind limb of 4 week old mouse



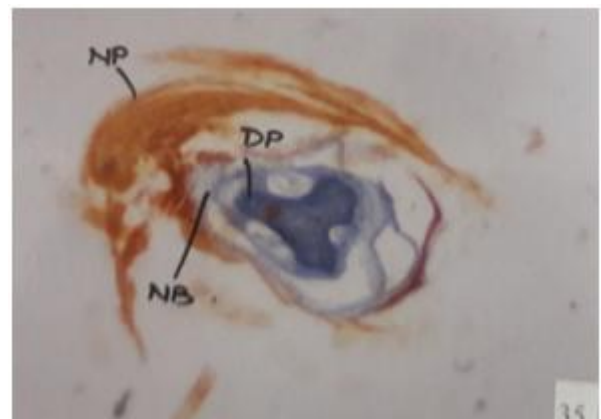
**Figure 1:** Saggital Section of middle finger (20X)



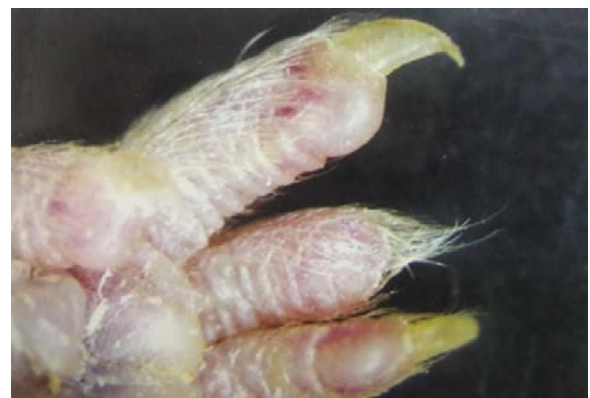**Figure 2:** Longitudinal section of middle finger (40X)



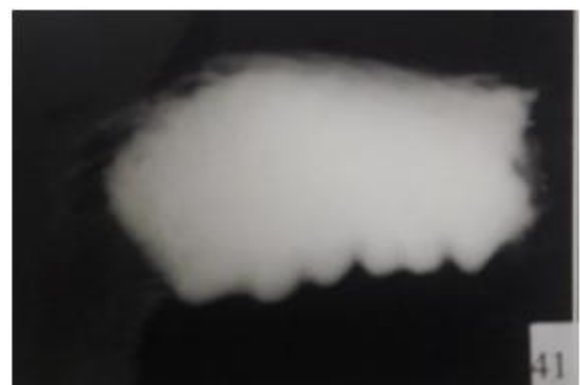**Figure 3:** Morphology of removed part of finger tip(15X)



**Figure 4:** Cross section of finger tip passing through DP (10X)



**Figure 5:** Post-amputated finger after 60 days (15X)



**Figure 6:** Post-amputated finger removed after 60 days (15X)

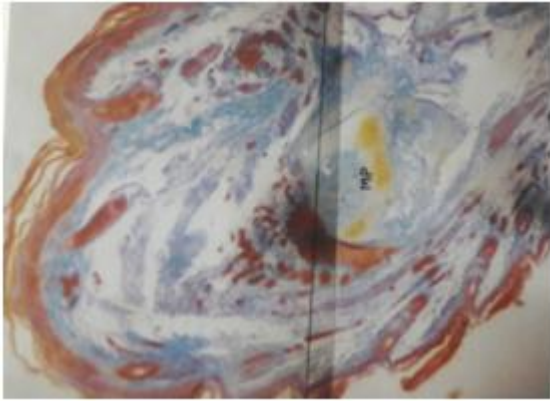


Figure 7: L.S. of post-amputated finger removed after 60 days (40X)

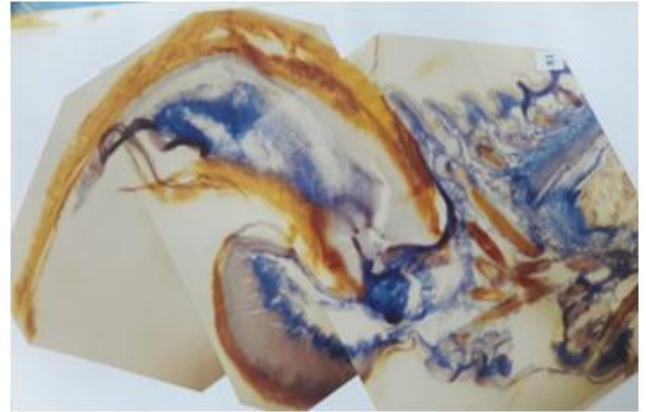


Figure 10: LS amputated finger 60 days, Post transplantation (40 X)



Figure 8: Morphology of amputated finger 60 days Post transplantation (Dorsal View 15 X)



Figure 9: Morphology of amputated finger 60 days Post transplantation (Ventral view 15X)

## 5. Acknowledgement

Authors are thankful to prof. K.K. Sharma former dean of science and Head department of zoology for his guidance and encouragement during this research.

## References

- [1] Archana, (1992) Exploration of the normal post amputational development change and of the induction of limb regeneration with retinoid in prenatal and postnatal mice. Ph.D. thesis, University of Rajasthan, Jaipur (India)
- [2] Borgens, R.B. (1982) Mice regrow the tips of their foretoes. *Science* 217:747-750
- [3] Fernando W.A., Leininger E., Simkin J., Li N., Malcom C.A., Sathyamoorthi S. et al. (2011). Wound healing and blastema formation in regenerating digit tips of adult mice. *Dev Biol*, 350, 301–310.
- [4] Illingworth, C.M. (1974) Trapped fingers and amputated fingertips in children. *J. Pediat. Surg.*, 9: 853-858.
- [5] Sharma, K.K. and Niazi, I.A. (1988) Variety of regenerative responses of different proximo-distal limb segments of young an advanced *Rana breviceps* tadpoles with vitamin A after amputation "Mmonographs in Developmental Biology". 21: 124-137
- [6] See E.Y., Kulkarni M. & Pandit A. (2013). Regeneration of the limb: opinions on the reality. *J Mater Sci Mater Med*, 24, 2627–2633.
- [7] Sharma, R.K., (2002) Studies on certain aspects of finger regeneration abilities in mice and search of means to induce regeneration in otherwise non-regenerating cases and to design artificial finger. Ph.D. Thesis, M.D.S. University, Ajmer (India)
- [8] Shores J.T., Brandacher G. & Lee W.A. (2015). Hand and upper extremity transplantation: an update of outcomes in the worldwide experience. *Plast Reconstr Surg*, 135, 351e–360e.
- [9] Wallace, H. (1981) Vertebrate limb regeneration. [Publ. Hohn. Willey and Sons.]