

# Laparoscopic Cholecystectomy: Cystic Duct Occlusion with Titanium Clip or Ligature

Deepak Sharma, Brijesh Sharma, Mahesh Solanki

Department of Surgery, Mahatma Gandhi Medical College & Hospital, Sitapura, Jaipur, India

**Abstract:** *During lap. cholecystectomy (LC), cystic duct occlusion can be done with titanium clips or laparoscopically silk ligature. However, till now, there is no randomized, controlled study reported in the literature that has compared the outcome using either of these methods. In the present study, 100 patients who were to undergo lap.cholecystectomy were randomly assigned to two groups. Group I comprised patients undergoing cystic duct occlusion with clips while group II comprised those undergoing cystic duct occlusion with silk. Our aim was to compare the postoperative outcome in both the cases.*

**Keywords:** Laparoscopic cholecystectomy cystic duct occlusion with titanium clip or ligature

## 1. Introduction

Cholecystectomy is one of the commonest elective procedures performed by general surgeons. The technique of cholecystectomy was developed by a German surgeon Carl Johann August Lagenbuch. Since this technique has remained the "gold standard" for the treatment of symptomatic gallbladder. The first series of laparoscopies in man is attributed to HC Jacobaeus in 1911. In the last tenfold, the introduction of laparoscopic techniques to perform cholecystectomy has revolutionized this procedure. The onset of laparoscopic cholecystectomy has been a vital milestone in evolution of surgical treatment through minimal access approach.

Compared with open cholecystectomy, laparoscopic cholecystectomy has improved surgical outcome in terms of reduced pain, shorter hospital stay, quicker return of normal activity and improved cosmetic outcome. However, it is associated with the problem of high infrastructure and instrumental cost, high complication rate like biliary tract injury and bile leak injury to organ, haemorrhage, spilled gallbladder calculus, retained stones, biliary strictures, slippage of ligatures or clips and others. The mortality of laparoscopic cholecystectomy is as low as open cholecystectomy and ranges from 0.1 to 0.3%.

The laparoscopic surgery requires adequate methods for securing haemostasis and closure of tubular structure such as cystic duct stump during laparoscopic cholecystectomy. During laparoscopic cholecystectomy, it is necessary to occlude cystic duct permanently in order to prevent bile flow into the peritoneal cavity. Traditionally this has been through the application of non-absorbable titanium metal clips. Currently available metal ligation clips, while satisfactory in majority of cases, suffer from certain drawbacks. These include electrical current conduction, dislodgement, interference with imaging techniques such as MRI and CT scan. These disadvantages limited the widespread use of metal clips in surgical procedures. In contrast, these complications were not encountered with open cholecystectomy using thread to ligate the duct.

It is now possible, with increasing experience in advanced laparoscopic techniques, to safely occlude the cystic duct

with ligature as an alternative to clips. Sedlack et al tested the security of several types of laparoscopic and open surgery knots using 2-0 size suture materials. These experiments showed laparoscopic knots to be as secure as open square knots. Marane et al studied about intracorporeal ligation of cystic duct and artery during laparoscopic cholecystectomy and summarized that complications associated with use of clips can be avoided by using intracorporeal ligation. The time necessary to complete ligation was measured from preparing the pedicle to dividing duct and artery in 170 cases. A 10 cm 2.0 polyglactin tie was used to ligate cystic duct and artery and it took 2-8 minutes the cost of endoclips was approximately 150 British pounds per patient whereas polyglactin ligature costs under 1.5 British pounds. Thus they concluded that ligation of cystic duct and artery is safe, cost effective and does not add to operative time.

This study was conducted in dept. of General surgery, Mahatma Gandhi medical college and Hospital, Jaipur. This was a prospective randomized double blind study of 100 patients to do the comparative evaluation of cystic duct occlusion by metallic titanium clips versus non-absorbable thread (silk). An effort was made to compare the operative time, intra operative course, postoperative recovery and morbidity and mortality associated with laparoscopic cholecystectomy using titanium clips versus non-absorbable thread (silk) for cystic duct stump ligation.

## 2. Material and Methods

This was prospective double blind randomized controlled study. A total of 100 cases taken up for laparoscopic cholecystectomy based on clinical examination and investigation which were included in the study. Thorough history and clinical examination of each patient was done. All routine investigation, liver function tests and ultrasonography were performed to confirm the diagnosis. The patients included in the study were randomly divided into two groups i.e. 1 and 2 of 50 patients each. They were divided into their respective group in a random fashion. In one group of patients undergoing laparoscopic cholecystectomy, cystic duct was occluded with clips and in other group non-absorbable suture (silk) were used to occlude cystic duct. Primary outcomes like mortality, CBD

Volume 5 Issue 11, November 2016

[www.ijsr.net](http://www.ijsr.net)

Licensed Under Creative Commons Attribution CC BY

injury, gallbladder perforation, leakage of bile requiring ERCP, collection of bile requiring re-exploration or USG guided drainage, recurrent residual CBD calculus and obstructive Jaundice were noted. Secondary outcomes like operative time and hospital stay were also noted.

### 3. Equipment

The equipment which we used for laparoscopic cholecystectomy included a insufflator, light source, camera, high-resolution video monitor, irrigation and suction device, and mono polar electro cautery unit.

#### Instruments

The instruments for which we used included ports, endoscopes, graspers, Maryland , scissors, clip applicators, irrigators and aspirators, electro cautery , and gallbladder extractor.

- 1) Clip Applicator - The reusable clip applicator (10 mm diameter) was used. Clips can be loaded into the jaws without extracting out the instrument, which saves time but is more expensive than the single clip reusable clip applicator.
- 2) Non-absorbable suture(silk) for ligation of cystic duct.

### 4. Discussion

Laparoscopic surgery is always a better option to open surgery across all disciplines. though the scope of advantages varies from open surgery to laproscopic surgery on post-operative pain, cosmetics, hospital stay and convalescence are recognised widely. Many surgeons have attempted to use alternatives to non absorbable clips such as absorbable clips, locking clips, absorbable knots or more recently ultrasonic dissectors for cystic duct occlusion. So far, many studies are available which favour use of knots over clips in terms of safety,feasibility and cost effectiveness.

All the 100 patients underwent through clinical examination, relevant laboratory investigation and ultrasonography. These patients were randomly allotted into one of the two groups-Group 1 where titanium clip were used and Group 2 where ligature were used to occlude the cystic duct and artery. The intraoperative events and post-operative finding were analysed and recorded.

**Table 1:** Comparing preoperatively two groups

Features	Clip Group (n=50)	Ligature Group (n=50)
Mean age of patients	44.26 years	47.32 years
Male: Female ratio	1:4.5	1:2.3

We took up the study with aim to compare clips and knots for cystic duct occlusion in terms of safety, cost effective and post operative morbidity. In our study, the patients were randomly allocated into two groups of 50 patients each. In one group of patients undergoing laparoscopic cholecystectomy, cystic duct was occluded with clips and in other group knots or ligatures were used to occlude cystic duct.Mean age in our study was 44.26 yrs in clip group and 47.32 yrs in ligature group.It is comparable to studies of Gordon et al and budd et al. In the Clip Group, maximum

patients were in 41-50 yrs age group and in ligature Group; patients age was 31-40 yrs. There is a female predominance in both clip (70%) and ligature groups (74%) in our study. Similar female predominance is seen in study by Lim BS [17]. The percentage of females and the mean age of participants in the trials conducted by Rohr S1 [18] were 60.7% and 58.1 years respectively. In western literature, the average age of symptomatic cholelithiasis were 47 and 45 years as reported by Gordon et al and budd et al respectively.

Regarding operating time in our study , which is time taken from initial incision to closure of wound is 46.6 minutes in clip group and 70.7 minutes in ligaturegroup. The difference in mean operative time was because intra-corporeal knotting required extra time as surgeons are not doing intra-corporeal knotting during laproscopic cholecystectomy as commonly as using clip. However, this difference was not statistically significant (p=0.493).

In our study,intraoperative bleed occurs in 1 patients(2%) of Group 1 and 2 patients(4%) of Group 2.all cases were managed by diathermy and clips/re-knotting.no case of uncontrolled bleeding was seen. In our study injury to gall bladder and bile spillage occurred in 18 cases.7 cases (14%)in Group 1 and 11 cases(22%) in Group 2. The difference between the two group was not significant. This is comparable to 16%incidence of gall bladder perforation during laproscopic cholecystectomy as reported by cuschieri et al. There is no cases of cystic duct leak and liver injury were reported during procedure. Wide cystic duct was encountered in 5 cases(10%) in Group 1 and 9 cases(18%) in Group 2. Saha SK in his study reported that wide cystic duct ligation with thred should be the gold standard in laproscopic cholecystectomy.

In our study injectable analgesic needed beyond 2 days in Group 1 (2 patients) and 42 patients(84%) in Group 2. There is 12 patients(24%) in Group 1 and 19 patients(38%) in group 2 had occurrence of nausea/vomiting in post-operative period.statistical analysis revealed that the difference between the two group was not statistically significant. Ileus occurred in one case in clip group(2%) and 21 cases(42%) in ligature group.this difference between two group was significant.peter et al reported postoperative ileus to be in 1.06% caes in their study.there is no case of biliary peritonitis due to post-operative bile leak or bleeding. In our study ,port site infection were reported in 2cases (4%) in Group 1 and 0% in Group 2. Majority of patients in Group 1,46(92%) were discharge on 5<sup>th</sup> and 7<sup>th</sup> day while in Group 2<sup>nd</sup> 31(62%) were discharge on beyond 7<sup>th</sup> day. This difference between two group was highly significant.In Group 1 30patients(60%) resumed work with in 8 days while in Group 2 ,26(52%) resumed work on 9<sup>th</sup> to 11<sup>th</sup>day.this was statistically significant.

The surgical management of gallstones have been revolutionised after the advent of laparoscopic cholecystectomy. This minimally invasive technique has virtually become the gold standard in the management of cholelithiasis. As the number of surgeons performing Laparoscopic Cholecystectomy is increasing, therefore a rigorous evaluation of safety of Laparoscopic

Cholecystectomy is warranted. In Laparoscopic Cholecystectomy cystic duct occlusion has been tried with different materials including metallic clips, absorbable clips, absorbable ligatures and more recently harmonic scalpel. It is essential to determine the extent of difference in morbidity and mortality when comparison is made between different methods of cystic duct occlusion. This study was undertaken to compare the safety, cost effectiveness, post operative morbidity and mortality of cystic duct occlusion with clips versus knot/ ligature.

**Table 3: Post Operative Findings**

	Clip Group(n=50)	Ligature Group(n=50)
Mean hospital stay	5 <sup>th</sup> and 7 <sup>th</sup> day	7 <sup>th</sup> day
Drain removed(<24hrs)	94%	56%
Nausea/vomiting	24%	38%
Ileus	2%	42%
Time to return work	8 <sup>th</sup> day(60%)	9 <sup>th</sup> day(52%)
Port site infection	4%	0%
Analgesic requirement	4%	84%

## 5. Conclusions

We share our experience of one hundred cases which were subjected to Laparoscopic Cholecystectomy out of which in fifty cases cystic duct & cystic artery was occluded by clips and in other group of fifty cases the cystic duct& cystic artery was occluded with ligature. Majority of the patients were female in both groups,72 out of 100 that indicate gall stone is more common in female. There was more cases of intra operative biliary spillage in ligature group(22%),this is due to larger operative time. The surgery in Group 1 took a mean time of 46.6 minutes whereas in Group 2 the mean time of surgery was 70.7 minutes .this need for greater time in ligature group can be attributed to the fact that tying intra-corporeal knots requires more expertise and skills. There were greater instances of postoperative pain, nausea /vomiting and ileus in patient of ligature group.No cases of bile duct injury and required ERCp for persistent bile leak were detected in either of two groups of our study.No patient in either group developed biliary peritonitis after surgery and during follow-up. Patients in whom titanium clips were used to occlude the cystic duct had a shorter hospital stay and showed an early return to work. Cost of ligatures was much cheaper than clips. Patient in whom ligature were used had no port site infection on follow up.

We can conclude that silk ligature can be safely uses as an alternative to titanium clips for occlusion of cystic duct. It needsexpertise and skill to master the art of intra-corporeal knotting and there is a longer learning curve. Clips are easy to use and less time consuming. Ligature in inexperienced hands and clips even in newer hands are equally safe. Ligature offers definitive advantages in case of wide cystic duct and is a cost effective alternative to titanium clips in laparoscopic cholecystectomy.

## References

[1] McMahon A, Fishbacher C, Frame S, MacLeod M.C; Impact of laparoscopic cholecystectomy: A

population based study. *Lancet* 2000; 356(9242): 1632- 1637.

[2] Chen A.Y, Daley J, Pappas T.N, Henderson W.G, Khuri S.F; Growing use of laparoscopic cholecystectomy in the national veterans affairs surgical risk study: Effect of volume, patient's selection and selected outcomes. *Ann Surg* 1998; 227(1): 12- 24.

[3] Urbach D and Stukel T; Rate of elective cholecystectomy and the incidence of severe gallstone disease.*CMAJ* 2005.

[4] Dell'Abate P, Del Rio P, Soliani P, Arcuri MF, Sianesi M; Laparoscopic technique in enlarged cystic duct. *G Chir* 2004; 25: 412-3.

[5] Shea JA, Healey MJ, Berlin JA, Clarke J.R, Malet P.F, Staroscik R.N et al.; Mortality and complications associated with laparoscopic cholecystectomy. *Ann Surg* 1996; 224(5): 609-620.

[6] Kennedy RJ, Clements WD, Diamond T; Cystic duct laceration by metallic clips: A cautionary note. *The British JrSurg* 1995; 82: 1543.

[7] Hamer DB; Cystic duct laceration by metallic clips: A cautionary notes *The British JrSurg* 1996; 83: 708.

[8] Hawasli A; The use of absorbable clips in laparoscopic cholecystectomy. *J Laparoendosc Surg.* 1994; 4(5):333-8.

[9] Bektas H, Schrem H, Winny M, Klempnauer J; Surgical treatment and outcome of iatrogenic bile duct lesions after cholecystectomy and the impact of different clinical classifications systems. *The British JrSurg* 2007; 94: 1119-27.

[10] Rohatgi A, Widdison AL; An audit of cystic duct closure in laparoscopic chole cyst ectomies. *SurgEndosc.* 2006; 20: 875-7.

[11] Saha SK; Ligating cystic duct in laparoscopic cholecystectomy. *Am J Surg* 2000; 179: 494-6.

[12] Seenu V, Shridar D, Bal C, Parshad R, Kumar A; Laparoscopic cholecystectomy: cystic duct occlusion with titanium clips or ligature? A prospective randomized study. *Trop Gastroenterol* 2003; 25 (4): 180-3.

[13] Tebala GD; Three port laparoscopic cholecystectomy by harmonic dissection without cystic duct and artery clipping. *Am JSurg* 2006; 191: 718-20.

[14] IbnOuif AM, Al Arabi Y; Intracorporealvicryl ligatures reduces cost in some countries. *Saudi JGastroenterol.* 2002; 8(1):14-6.

[15] Ozer M.T, Sinan H, Kilbas Z, Coskun A.K, Gunal A, Demirbas S et al.; Comparison of Different Cystic Duct Closure Methods in Laparoscopic Cholecystectomy: Silk Suture, Surgical Clip, Harmonic Scalpel and Plasma Kinetic. *Arch ClinExpSurg* 2012; 1(3): 168-171.

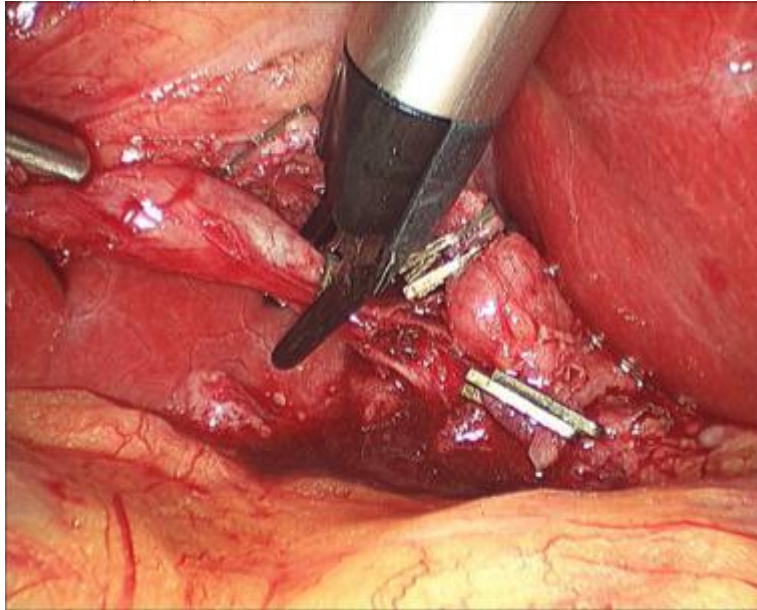
[16] TamijMarane, Campbell DF, Nassar AHM; Intracorporeal ligation of the cystic duct and artery during laparoscopic cholecystectomy: do we need the endoclips? *Minimally Invasive Therapy & Allied Technologies* Jan 2000; 9(1): 13-14.

[17] Lim BS; Intracorporeal ligation of the cystic duct during laparoscopic cholecystectomy. *SurgLaparoscEndosc.* 1996; 6(5):388-91.

[18] Rohr S, De Manzini N, Vix J, Tiberio G, Wantz C, Meyer C et al.; Value of absorbable clips in



laparoscopic cholecystectomy. A randomized prospective study. Chir 1997; 134 (4): 180-4.



**Figure 1:** Cystic duct occlusion with titanium clip

