

Diagnosing and Management of Middle Mesial Canal in Mandibular Molar Using Cone Beam Computerized Tomography - A Case Report

Ravisankar Damenedi¹, Shailendra Mashalkar², Ayesha Fathima³, Sangeetha Singh⁴

¹Professor and HOD, Al-Badar Dental College and Hospital, Gulbarga, Karnataka

²Reader, Al-Badar Dental College and Hospital, Gulbarga, Karnataka

³Post Graduate Student, Al-Badar Dental College and Hospital, Gulbarga, Karnataka

⁴Post Graduate Student, Al-Badar Dental College and Hospital, Gulbarga, Karnataka

Abstract: *The main objective of root canal treatment is the thorough mechanical and chemical cleansing of the entire pulp space followed by complete obturation with inert filling material. The root canal treatment of a mandibular molar with aberrant canal configuration can be diagnostically and technically challenging. This clinical case report describes the management of the mandibular molar with three separate mesial canals including middle mesial canal, in which the diagnosis was confirmed with the help of cone beam computerized tomography and it also highlights the management of the unusual canal morphology using CBCT.*

Keywords: Mandibular Molar, Middle Mesial Canal, Cone Beam Computed Tomography.

1. Introduction

The main objective of root canal treatment is the thorough mechanical and chemical cleansing of the entire pulp space followed by complete obturation with inert filling material^[1]. Knowledge of both normal and abnormal anatomy of the root canal system dictates the parameters for proper execution of root canal therapy and can directly affect the outcome of the endodontic therapy.^[1,2,3,4] Therefore, it is imperative that aberrant anatomy of the root canal system should be identified before and during root canal treatment to effectively clean and shape the root canal system.

Mandibular molars are the most frequent tooth type to be endodontically treated^[1]. Traditionally, mandibular molars are described as 2-rooted teeth with 2 canals in the mesial root and 1 or 2 canals in the distal root^[3,4]. However, studies have shown several variations in the anatomy of mandibular molars.

Since Vertucci and Williams^[3] first reported the presence of a middle mesial (MM) canal in a mandibular molar, there have been multiple case reports of aberrant canal morphology in the mesial root^[3,5]. Pomeranz et al^[4,6] described the anatomy of MM canals as follows: (1) fin: The file passes freely between the main mesial canal (ML or MB) and the MM canal (transverse anatomies), (2) confluent: The MM canal originates as a separate orifice but apically joins the MB or ML canal, and (3) independent: The MM canal originates as a separate orifice and terminates as a separate apical foramen.

It is of prime importance for the clinician to identify the entire topographic location of any additional canal orifices and also extremely important that clinicians use all the armamentaria at their disposal to locate and treat the entire root canal system^[7]. Radiographic examination using

conventional intraoral periapical views is important for the evaluation of the canal configuration. Well-angulated periapical films should be taken with cone-directed straight-on, mesio-oblique, and disto-oblique; this technique often reveals and clarifies the three-dimensional morphology of the tooth. However, it has its inherent limitation to assess the root canal system completely.^[8,9,10] The use of the magnifying loupes, dental operating microscope, and adjunctive diagnostic aids like cone beam CT and so forth can also be used^[11,12].

Recently, cone beam CT (CBCT) imaging has been shown to provide comparable images at reduced dose and costs to be considered as a relative new method that produces three-dimensional (3D) information of the maxillofacial skeleton, including the teeth and their surrounding tissue. Specific endodontic applications for CBCT are being identified as the use of this technology becomes more common^[13]. Cotton et al^[8,9,10] reported a number of useful applications of CBCT imaging in endodontics. Furthermore, Matherne et al^[14] suggested that CBCT imaging is useful even in identifying the root canal system.^[17,18,19]

In this case report, we present clinical detection and the management of an independent MM canal in mandibular first molar by using CBCT imaging.

2. Case Report

A 28-year-old male patient reported to department of conservative dentistry and endodontics, Al-Badar Dental College, Gulbarga, Karnataka with a chief complaint of pain in right lower posterior region of the mouth since a month. The patient's medical history was non-contributory. Clinical examination revealed the presence of deep occlusal caries with tooth 46. The tooth 46 was tender and there was no swelling / sinus opening present in the adjacent soft tissues.

No periodontal pockets were detected. The tooth did not respond to electrical pulp testing. Radiographic examination revealed the presence of radiolucency involving the pulp and PDL was enlarged with mesial and distal roots of 46 suggestive of chronic periapical periodontitis, (Fig.1) necessitating endodontic therapy for the same.

After obtaining the patient's consent, tooth was anesthetized using 2% Lignocaine with 1: 80,000 adrenaline (Lignox, Indoco Remedies Ltd, India) and isolated using rubber dam. All caries were removed and access cavity was prepared. Three root canal orifices were initially observed, including mesiobuccal (MB), mesiolingual (ML) and Distal. The working length was determined with an electronic apex locator (RootZX II; Japan)(Fig.1). The patency of the root canals were obtained using stainless steel no. 10 K-files (Mani inc., Japan) and cleaned and shaped using nickel-titanium rotary files (Heroshapers). During instrumentation the canals were intermittently flushed with 5.25% sodium hypochlorite. During the course, a tiny orifice was detected between the MB and ML with an endodontic explorer DG-16 (Dentsply Maillefer, Switzerland) which was conformed under endodontic microscope at 10X magnification .(fig.2)

The patency of the additional canal was confirmed using no. 15 K-file passing through the orifice. The existence of a middle mesial (MM) canal in a line was considered and later confirmed with the intraoral periapical radiograph (IOPA). We decided to perform cbct scans for an accurate daignosis with informed consent from the patient. The first molar was focused, and the morphology was obtained in transverse, axial, and sagittal sections using the CBCT scan. All CBCT images revealed that the mesial root had three root canals, and the canal we had originally considered as ML canal was actually an MM canal(Fig3-6)

According to Pormeranz's classification, the MM canal was classified as "confluent"- The MM canal originates as a separate orifice but apically joins the MB or ML canal⁵. All three mesial canals including the MM canal were cleaned, shaped, and obturated with gutta-percha and sealer (AH-plus, Dentsply-Maillefer). Post treatment CBCT images revealed three independent root canals in the mesial root obturated efficiently with gutta-percha to the accepted lengths in all three canals . The patient experienced no post treatment discomfort and was subsequently referred for appropriate coronal restoration.

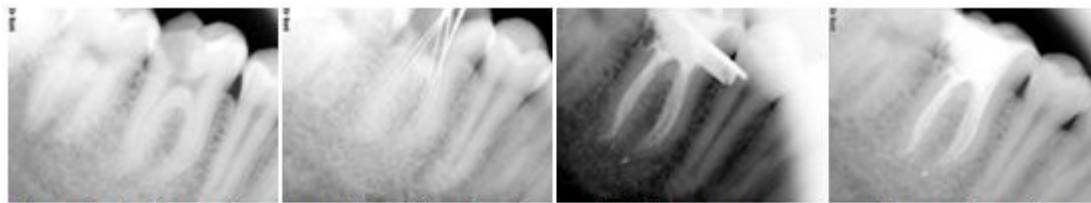


Figure 1: A diagnostic x-ray, B working length C Mastercone D post obturation

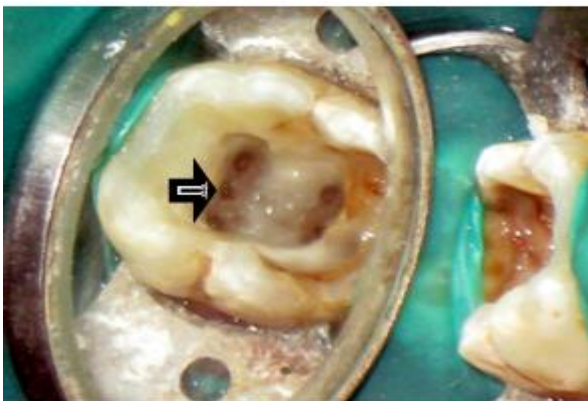

Figure 2: Occlusal view interpreting mesiobuccal, middle mesial, mesiolingual, distobuccal, distolingual canal.

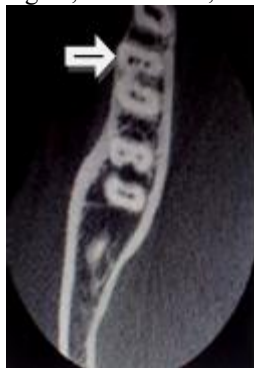

Figure 3: Axial view – PRE CBCT – detecting three mesial canals and two distal canals.

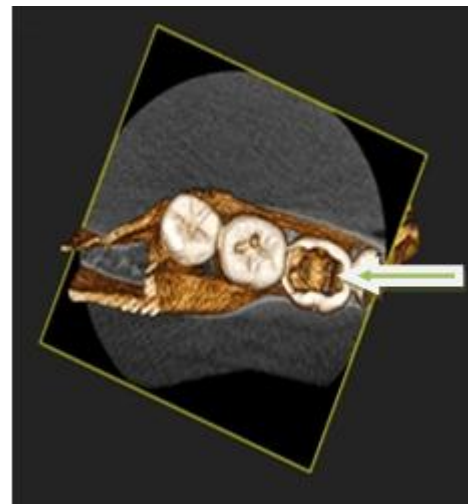


Figure 4: Three dimensional occlusal view – PRE CBCT – detecting three separate orifice at mesial side.

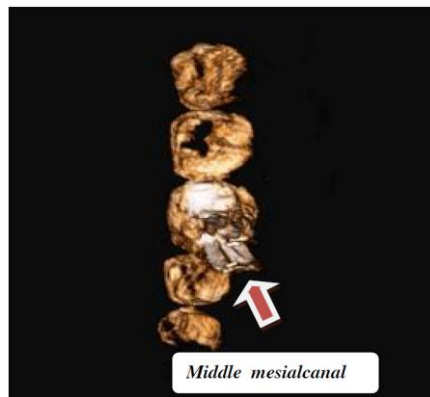


Figure 5: Three dimensional post obturation view interpreting the three different mesial canals root.

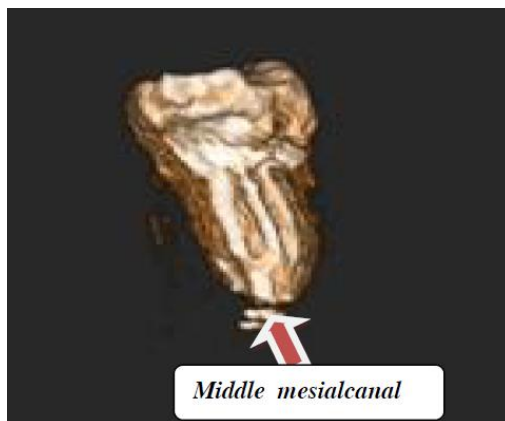


Figure 6: Three dimensional post obturation multiplanar view interpreting the three different mesial canals.

3. Discussion

Adequate knowledge of root canal system anatomy is indispensable to perform endodontic therapy.^[1] A major cause of root canal therapy failure is the inability to understand the internal anatomy of the tooth and subsequent incomplete endodontic treatment.^[2] A good pre-operative radiograph is essential for preventing missed anatomy but it does not always necessarily reveal the actual number of canals present in the root.^[3] Krasner and Rankow proposed specific laws of symmetry, law of color change, and laws of orifice location based on consistent and identifiable anatomic configurations of pulp chamber.⁴ These laws help to locate canal orifices on the pulp chamber floor in a systematic way. Visual and diagnostic aids also play an important role in detecting atypical root canal anatomy.^[6,8,20]

Numerous *in vitro* and *in vivo* studies on the morphology of mandibular first molars have provided new data relating to the presence of extra roots, additional root canals, lateral canals or transverse canal anastomoses between the two or three canals in the mesial root.^[6] There are numerous cases in the literature concerning the unusual anatomy of the mandibular first molar. A middle mesial [MM] canal sometimes is present in the developmental groove between the mesiobuccal [MB] and mesiolingual [ML] canals. The presence of a third canal in the mesial root of mandibular molars has been reported to have an incidence rate of 1 to 15%. This additional canal may be independent with a separate foramen, or the additional canal may have a

separate foramen and join apically with either the mesiobuccal or mesiolingual canal^[21,22]

Numerous techniques enable the clinician to look for the middle mesial canal. It is important to have an adequately flared access cavity to visualize the anatomy of the chamber, constricted access can lead to missed anatomy. Diagnostic measures are important aids in the location of root canal orifices. The measures include obtaining multiple pre-treatment radiographs or CBCT, examining the pulp chamber floor with sharp explorer, troughing grooves with ultrasonic tips etc., the use of surgical microscopes has vastly enhanced the quality of endodontic treatment. The use of better diagnostic aids like Cone Beam Computed Tomography and better magnification like the surgical operating microscope have increased the clinician's chances of diagnosing, locating and treating extra canals.^[9,10]

Diagnostic information directly influences clinical decisions. Accurate data facilitate better treatment-planning decisions and more predictable outcomes. CBCT is an emerging technology with the potential to revolutionize the diagnosis and management of endodontic problems. An increasing number of specific applications of CBCT in endodontics are being identified as use of the technology becomes more widespread.

The present case report describes the treatment of a first mandibular molar with three mesial root canals. A systematic review conducted by de Pablo et al.^[16] reported that the overall incidence of this anatomical morphology was 2.6%. They also showed that the confluence of the MM canal with the mesiobuccal or mesiolingual canals having a common apical termination was more frequently observed than a configuration including three distinct, separate apical foramina^[15, 20, 21].

The above case reinforces the fact that finding additional canals is not entirely dependent on the use of advanced visual and diagnostic aids. Sound knowledge coupled with commitment to unveil the internal anatomy can lead to discovery of atypical anatomy. Furthermore, a magnified view of the operating field using dental microscopic or surgical loupes increases the chance of locating hidden canals^[5, 7, 17, 18] The benefits of a CBCT investigation must outweigh any potential risks; therefore, cases of endodontic disease should be judged on an individual basis. Until further evidence is available, CBCT should only be considered in situations where conventional imaging systems do not yield sufficient information to allow the appropriate management of the endodontic problem.^[12,18]

4. Conclusion

In this case report we confirmed the presence of three mesial canals in mandibular second molar with the aid of cone beam computed tomography (CBCT) which should be used as an adjunct for confirming the presence of complicated root canal anatomy, especially in situations where conventional periapical radiographs are not very conclusive.

References

- [1] Ingle JI, Bakland LK, Beveridge EE; Modern Endodontic Therapy. Endodontics 5th Ed, B C Decker Elsevier, 2002; Canada: 1-23.
- [2] E. S. Reeh, "Seven canals in a lower first molar," *Journal of Endodontics*, vol. 24, no. 7, pp. 497-499, 1998.
- [3] F. J. Vertucci, "Root canal anatomy of the human permanent teeth," *Oral Surgery Oral Medicine and Oral Pathology*, vol. 58, no. 5, pp. 589-599, 1984.
- [4] J. F. Vertucci, E. J. Haddix, and R. L. Britto, "Footh morphology and access cavity preparation," in *Pathways of Pulp*, S. Cohen and M. K. Hargreaves, Eds., pp. 203-204, Mosby Elsevier, St. Louis, Mo, USA, 9th edition, 2006
- [5] Matherne RP, Angelopoulos C, Kulild JC, et al. Use of cone-beam computed tomography to identify root canal systems in vitro. *J Endod* 2008;34:87-9
- [6] H. H. Pomeranz, D. L. Eidelman, and M. G. Goldberg, "Treatment considerations of the middle mesial canal of mandibular first and second molars," *Journal of Endodontics*, vol. 7, no. 12, pp. 565-568, 1981.
- [7] Neaverth EJ, Kotler LM, Kaltenbach RF; Clinical investigation [in vivo] of endodontically treated maxillary first molars. *J Endod*, 1987; 13(10): 506- 512.
- [8] zachibana H, Matsumoto K. Applicability of x-ray computerized tomography in endodontics. *Endod Dent Traumatol* 1990;6:16-20.
- [9] Hassan B, Metska ME, Ozok AR, et al. Detection of vertical root fractures in endodontically treated teeth by a cone beam computed tomography scan. *J Endod* 2009;35:719-22.
- [10] Cotton TP, Geisler TM, Holden DT, et al. Endodontic application of cone-beam volumetric tomography. *J Endod* 2007;33:1121-32.
- [11] Cohen S, Hargreaves MK; Pathways of the pulp. 9th ed. St. Louis, MO: Mosby, 2006; 220.
- [12] Patel S. New dimensions in endodontic imaging: part 2. Cone beam computed tomography. *Int Endod J* 2009;42:463-75.
- [13] Ricucci D. Three independent canals in the mesial root of a mandibular first molar. *Endod Dent Traumatol* 1997;13:47-9.
- [14] Barker BCW, Parsons KC, Mills PR; Anatomy of root canals in permanent mandibular molars. *Aust Dent J*, 1974; 19(6): 408-13.
- [15] Campos FH; Unusual root anatomy of mandibular first molars. *J Endod*, 1985; 11(12): 568-572.
- [16] Campos FH; Three canals in the mesial root of mandibular first permanent molars: A clinical study. *Int Endod J*, 1989; 22(1): 39-43.
- [17] Dailey B, Mines P, Anderson A, Sweet M. The use of cone beam computer tomography in endodontics: results of a questionnaire:2010. AAE annual session abstract presentation PR10. *J Endod* 2010;36:567.
- [18] Patel S, Durack C, Abella F, Shemesh H, Roig M, Lemberg K. Cone beam computed tomography in Endodontics — a review. *Int Endod J* 2015;48:3-15.
- [19] Cohenca N, Shemesh H. Clinical applications of cone beam computed tomography in endodontics: a comprehensive review. *Quintessence Int* 2015;46:465-80.
- [20] Min KS. Clinical management of a mandibular first molar with multiple mesial canals: a case report. *J Contemp Dent Pract* 2004;3:142-9.
- [21] Goel NK, Gill KS, Taneja JR; Study of root canal configuration in mandibular first molar. *J Indian Soc Pedod Prev Dent*, 1991; 8(1): 12-14.
- [22] Beatty RG, Krell K; Mandibular molars with five canals: report of 2 cases. *J Am Dent Assoc*, 1987; 114(6): 802-4.
- [23] Baugh D, Wallace J; Middle mesial canal of mandibular first molar: A case report and literature review. *J Endod*, 2004;30(3):185-186.