

Immune Reconstitution Graves Ophthalmopathy Induced by Haart Therapy in a Hypothyroid Male Patient

Yasir Ali MD^{1,2}, Hussein Elbadawi MD¹

¹Division of Endocrinology, Wayne State University, Detroit, Michigan, USA

²Detroit Medical Center, Detroit, Michigan, USA

Abstract: *The objective is to report a rare case of a 41-year-old African American male who recently developed Graves Ophthalmopathy (GO) secondary to highly active antiretroviral therapy (HAART) induced Immune reconstitution inflammatory syndrome (IRIS). He is a known case of primary hypothyroidism treated with Levothyroxine since the age of 33 and found with AIDS at the age of 34 when HAART therapy was started. He then developed Grave's disease (GD) with worsening GO when his CD4 T-cell counts improved. We treated our patient with Methimazole and followed him at regular intervals until his thyroid levels normalized. GD is an autoimmune condition caused by Thyroid stimulating immunoglobulins (TSI) leading to hyperthyroidism. Ocular problems are one of its manifestations, ranging from simple irritation to proptosis and even complete loss of vision. Patients on HAART may develop IRIS in 10-25% of cases. Less than 1% of IRIS cases present as GD and out of them only 25% have reported GO which were of a milder version. Our case is the first case to show two coinciding points; one is development of a severe degree of GO and the other is the transition from hypothyroidism to Grave's disease in a male patient treated with HAART.*

Keywords: HIV, HAART therapy, Immune reconstitution inflammatory syndrome, Graves disease, Graves Ophthalmopathy, Hypothyroid male patient.

1. Introduction

The plasma load of HIV-1 RNA is a direct reflection of number and severity of symptoms due to HIV [1]. Treatment with highly active antiretroviral therapy (HAART) has significant impact on mortality and the quality of life. Once the diagnosis is confirmed, HAART therapy is highly recommended [2]. A drop in viral load along with a rise in CD4+ cell counts may boost immunity in immunocompromised patients when they are started on HAART. On the contrary, as the patients on HAART regain the capacity to mount an inflammatory response, a small percentage of them symptomatically present with previously dormant infectious processes, the term is known as Immune reconstitution inflammatory syndrome (IRIS) [3,4]. Autoimmune diseases have also been increasingly reported in patients on HAART therapy through the same mechanism of Immune reconstitution (IRIS). The immunocompromised state increases risk of autoimmunity that may also occur after sudden boost in immunity as by HAART therapy [5]. The temporal relationship of the beginning of HAART followed by drop in HIV-1 viral load and rise in CD4+ cell count followed by the appearance of anti TSH receptor antibodies (anti TSHR Ab) and antithyroid peroxidase antibodies (anti TPO Ab) has now been established [6].

2. Case Presentation

A 41-year-old AAM consulted by the endocrine division with complaints of worsening palpitations, tremors, severe weakness, fatigue, irritability and non-intentional weight loss of 30 lbs. over six months. He also noted diplopia with protrusion of his eyes over the past year. He has a longstanding history of Hypothyroidism and AIDS reporting compliance with both Levothyroxine 125 mcg/d and

HAART therapy. At presentation, his body temperature was 99.0 F, blood pressure 118/73 mmHg, heart rate was regular at 99 b/min, respiratory rate 20/min, BMI 22.35 (Baseline BMI 26.30). Physical examination was significant for a diffusely enlarged thyroid gland, tremors, bilateral proptosis, proximal muscle weakness; rest of the exam was within normal limits. Levothyroxine was discontinued. He was put on Methimazole 30 mg once daily and Propranolol 40 mg thrice daily with clinical improvement on follow up.

Investigations

WBC and CD4 counts were low. TSH 0.009 (0.2-4.78 uIU/ml) with his baseline previously at 0.957. FreeT4 5.0 (0.8-1.8 ng/dL) his baseline was: 0.5, T3 509 (60-180ng/dL). TSI ≥ 500% (Normal <123%), Microsomal Ab 1: 6400, Thyroglobulin Ab 1: 1280. HIV Ab via ELISA was reactive. Serological profile for Hepatitis A,B and C was nonreactive. Rest of the blood work including Creatinine levels were within normal limits. Further imaging confirmed the diagnosis of GD on a 24-hour Radioactive Iodine uptake (RAIU) which was calculated at 70%.

Outcome and Follow up

The patient was complaint to antithyroid medicine. Follow up after 5 weeks showed resolution of symptoms of hyperthyroidism except for persistent proptosis and occasional diplopia. His weight increased by 8 lbs. Definitive therapy was decided to be total thyroidectomy which was successful.

3. Discussion

Dysregulated immune functions leads to a wide variety of autoimmune processes in HIV patients. HAART therapy, on

Volume 5 Issue 9, September 2016

www.ijsr.net

Licensed Under Creative Commons Attribution CC BY

the contrary, by boosting immunity may sometimes unmask underlying infectious and autoimmune diseases, the condition labeled as Immune reconstitution inflammatory syndrome (IRIS) [3,4]. Symptoms of GD may present late in the course of HAART therapy and exhibits organ specific immunity [18, 24]. Jubault et al. followed a group of patients on HAART therapy. After being followed for 20 months (range= 14-22) five of them developed symptoms of hyperthyroidism, tested positive on thyroid scans and anti TSHR/ anti TPO Abs, all suggestive of GD [6].

Gilquin et al. presented 3 cases, Jubault et al. presented 5 cases, Crum et al. presented 5 cases of HAART induced Graves IRIS but they either reported none or only milder symptoms of Ophthalmopathy. Additionally, none of the reported patients were male, nor were they reported to have prior thyroid dysfunction. Our case is of unique interest as we found a male patient with preexisting hypothyroidism for last 8 years and now showing the transition from hypothyroidism to full blown IRIS induced GD and severe GO (Fig 1).

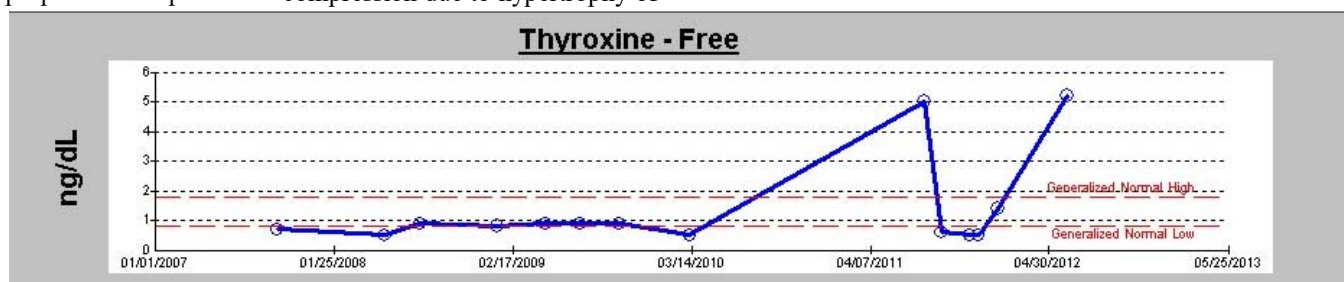
The term Grave's disease consists of a constellation of features -solely or combined- that may include goiter, hyperthyroidism, pretibial dermatopathy, orbitopathy . It is primarily due to increase expression of Autoantibodies against a G protein coupled receptor i-e Thyroid stimulating hormone receptors (TSHR) that then undergoes complex post translational processing [7,8]. Both clinical features and laboratory results may help in assessment of disease severity although there is no correlation established between them [9]. Patient with overt hyperthyroidism present with anxiety, emotional lability, weakness, tremor, palpitations, heat intolerance, increased perspiration, and weight loss despite a normal or increased appetite. 20 to 25 percent of patients present with obvious features of Ophthalmopathy at the time of diagnosis of hyperthyroidism. The estimated female to male incidence of Graves' ophthalmopathy in general population is 16:3 per 100,000 per year [10]. The major symptoms include irritation in the eyes, excessive tearing made worse by exposure to cold air or bright lights; eye or retro orbital discomfort, blurring of vision, diplopia and occasionally loss of vision. The enhanced expression of TSHR on orbital fibroblasts, adipocytes and extra ocular muscles provokes the concept of shared antigen with thyroid tissues that act as a target for cellular immunity and autoantibodies against these antigens (TSHR) [11-13]. Features include diffuse enlargement of extraocular muscles, proptosis and optic nerve compression due to hypertrophy of

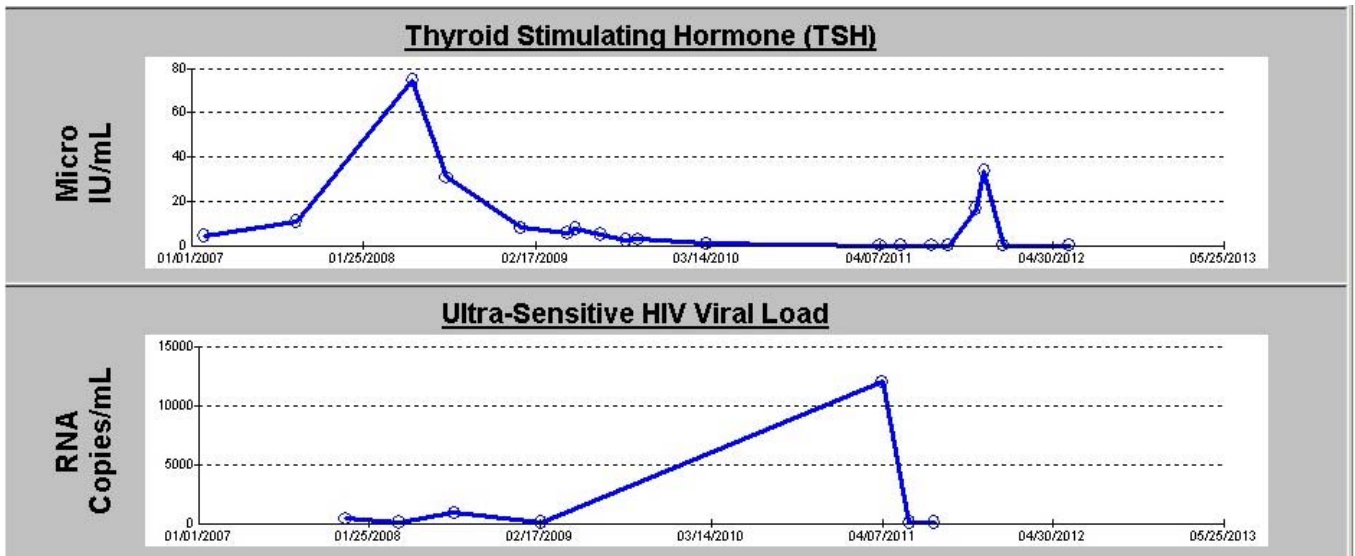
adjacent fibroblasts and extraocular muscles. Traditional treatment for GO includes steroids, retro orbital irradiation and/ or decompression surgery. More recently, Rituximab, a monoclonal antibody against CD20 B cells acquiring great attention by depleting anti TSHR antibodies producing B cells not only in periphery but also within the orbit [14-16].

The term "immune reconstitution inflammatory syndrome" (IRIS) describes the paradoxical worsening of preexisting infectious (mostly) or noninfectious/autoimmune (rarely) conditions following the initiation of highly active antiretroviral therapy (HAART) in HIV-infected individuals [3,4,17,18,24]. Following HAART, the patient regains the capacity to mount an inflammatory response due to recovery of CD4+ cells and decline in HIV load. Approximately 10-25 percent patients treated with HAART manifests clinical features of IRIS at some point in life [19]. The CD4+ cells rise following HAART is typically biphasic [20,24]. The first rapid phase mounts within 3-6 months of HAART and it is due to combination of decrease apoptosis and increase redistribution of Memory T cells from peripheral lymphoid tissues to circulation. Later on, the slower second phase is due to Thymopoiesis of Naïve CD4+ cells [21,24]. This thymopoiesis may possibly be the participating factor in IRIS development. The Diagnosis of IRIS is clinical and includes criteria;

- 1) Low pretreatment CD4+ cell count s [19,21,22]. Patients who are more immunocompromised when treated with HAART have more chances to develop IRIS.
- 2) Response to HAART is positive with rise in CD4+ cells and drop in viral load [23].
- 3) Clinical features suggestive of inflammatory condition.
- 4) Features of inflammation typically starts after HAART treatment i-e temporal association.
- 5) No evidence of drug-resistant infection, bacterial superinfection, drug allergy, adverse drug reactions, patient noncompliance, and reduced drug levels due to drug-drug interactions or malabsorption.

The relation of TSH, free T4 and HIV viral load late in the course of HAART therapy is shown in Graph 1. Management of IRIS is often to treat the underlying cause. HAART should be continued unless the IRIS manifestation is life threatening or may endanger to cause permanent sequelae [22].





Graph 1: Graphical representation of TSH, free T4 and HIV viral load, late in the course of HAART

4. Conclusion

This case underscores the significance of autoimmune diseases following HAART therapy. Physician prescribing the HAART therapy should be aware with the concept of Immune reconstitution inflammatory syndrome and its early infectious and late autoimmune disease manifestations. IRIS Graves may range from simple symptoms of hyperthyroidism to full blown ophthalmopathy.

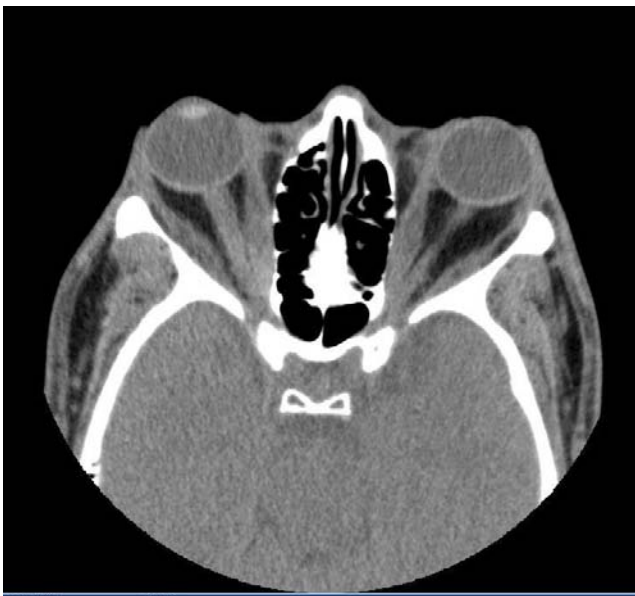

Figure 1: Diffuse symmetric enlargement of the extraocular muscles consistent with Grave's orbitopathy

References

- [1] Kelley CF, Barbour JD, Hecht FM. The relation between symptoms, viral load, and viral load set point in primary HIV infection. *J Acquir Immune Defic Syndr* 2007; 45:445.
- [2] Günthard HF, Aberg JA, Eron JJ, et al. Antiretroviral treatment of adult HIV infection: 2014 recommendations of the International Antiviral Society-USA Panel. *JAMA* 2014; 312:410.
- [3] DeSimone JA, Pomerantz RJ, Babinchak TJ. Inflammatory reactions in HIV-1-infected persons after initiation of highly active antiretroviral therapy. *Ann Intern Med* 2000; 133:447.
- [4] French MA, Lenzo N, John M, et al. Immune restoration disease after the treatment of immunodeficient HIV-infected patients with highly active antiretroviral therapy. *HIV Med* 2000; 1:107.
- [5] F. Vos, G. Pieters, M. Keuter, and A. van der Ven, "Graves' disease during immune reconstitution in HIV-infected patients treated with HAART," *Scandinavian Journal of Infectious Diseases*, vol. 38, no. 2, pp. 124–126, 2006.
- [6] Jubault V, Penfornis A, Schillo F, et al. Sequential occurrence of thyroid autoantibodies and Graves' disease after immune restoration in severely immunocompromised human immunodeficiency virus-1-infected patients. *J Clin Endocrinol Metab* 2000; 85:4254.
- [7] Davies TF, Ando T, Lin RY, et al. Thyrotropin receptor-associated diseases: from adenomata to Graves disease. *J Clin Invest* 2005; 115:1972.
- [8] Latif R, Morshed SA, Zaidi M, Davies TF. The thyroid-stimulating hormone receptor: impact of thyroid-stimulating hormone and thyroid-stimulating hormone receptor antibodies on multimerization, cleavage, and signaling. *Endocrinol Metab Clin North Am* 2009; 38:319.
- [9] Trzepacz PT, Klein I, Roberts M, et al. Graves' disease: an analysis of thyroid hormone levels and hyperthyroid signs and symptoms. *Am J Med* 1989; 87:558.
- [10] Bartley GB, Fatourechi V, Kadrmas EF, et al. The incidence of Graves' ophthalmopathy in Olmsted County, Minnesota. *Am J Ophthalmol* 1995; 120:511.
- [11] Stadlmayr W, Spitzweg C, Bichlmair AM, Heufelder AE. TSH receptor transcripts and TSH receptor-like immunoreactivity in orbital and pretibial fibroblasts of patients with Graves' ophthalmopathy and pretibial myxedema. *Thyroid* 1997; 7:3.
- [12] Spitzweg C, Joba W, Hunt N, Heufelder AE. Analysis of human thyrotropin receptor gene expression and immunoreactivity in human orbital tissue. *Eur J Endocrinol* 1997; 136:599.

- [13] Bahn RS. Graves' ophthalmopathy. *N Engl J Med* 2010; 362:726.
- [14] Salvi M, Vannucchi G, Campi I, et al. Efficacy of rituximab treatment for thyroid-associated ophthalmopathy as a result of intraorbital B-cell depletion in one patient unresponsive to steroid immunosuppression. *Eur J Endocrinol* 2006; 154:511.
- [15] El Fassi D, Nielsen CH, Hasselbalch HC, Hegedüs L. The rationale for B lymphocyte depletion in Graves' disease. Monoclonal anti-CD20 antibody therapy as a novel treatment option. *Eur J Endocrinol* 2006; 154:623.
- [16] Hegedüs L, Smith TJ, Douglas RS, Nielsen CH. Targeted biological therapies for Graves' disease and thyroid-associated ophthalmopathy. Focus on B-cell depletion with Rituximab. *Clin Endocrinol (Oxf)* 2011; 74:1.
- [17] Gomez V, Smith PR, Burack J, et al. Sarcoidosis after antiretroviral therapy in a patient with acquired immunodeficiency syndrome. *Clin Infect Dis* 2000; 31:1278.
- [18] Gilquin J, Viard JP, Jubault V, et al. Delayed occurrence of Graves' disease after immune restoration with HAART. Highly active antiretroviral therapy. *Lancet* 1998; 352:1907.
- [19] Ratnam I, Chiu C, Kandala NB, Easterbrook PJ. Incidence and risk factors for immune reconstitution inflammatory syndrome in an ethnically diverse HIV type 1-infected cohort. *Clin Infect Dis* 2006; 42:418.
- [20] Pakker NG, Notermans DW, de Boer RJ, et al. Biphasic kinetics of peripheral blood T cells after triple combination therapy in HIV-1 infection: a composite of redistribution and proliferation. *Nat Med* 1998; 4:208.
- [21] Manabe YC, Campbell JD, Sydnor E, Moore RD. Immune reconstitution inflammatory syndrome: risk factors and treatment implications. *J Acquir Immune Defic Syndr* 2007; 46:456.
- [22] Murdoch DM, Venter WD, Feldman C, Van Rie A. Incidence and risk factors for the immune reconstitution inflammatory syndrome in HIV patients in South Africa: a prospective study. *AIDS* 2008; 22:601.
- [23] Breton G, Duval X, Estellat C, et al. Determinants of immune reconstitution inflammatory syndrome in HIV type 1-infected patients with tuberculosis after initiation of antiretroviral therapy. *Clin Infect Dis* 2004; 39:1709.
- [24] Matthew R. Edmunds, et al. Clinical Challenges of Thyroid Eye Disease in HIV-Positive Patients on Highly Active Antiretroviral Therapy *J Clin Endocrinol Metab*, March 2015, 100(3):779 –787