

A Mandibular Second Premolar with Three Separate Canals - Radiographic and CBCT Observation-A Case Report

Gusiyska A.

Department of Conservative dentistry, Faculty of Dental Medicine, Medical University-Sofia, Bulgaria

Correspondence: Angela Gusiyska, Department of Conservative Dentistry, Faculty of Dental Medicine, Medical University – Sofia, Bulgaria; e-mail: gusiyska@yahoo.com

Abstract: *The knowledge of complex root canal morphology gives the opportunity to treat the cases with rare anatomy configurations. Incomplete cleaning and shaping of these complicated areas may leave tissue, bacteria, or necrotic debris in the canal. The importance of adequate preparation and three-dimensional obturation is of a great importance for periapical tissue health. This case report describe a radiographic and cone beam computed tomography (CBCT) observation of a second mandibular premolar with one root and three separate canals, with three separate apical foramina (VIII type according the Vertucci's classification).*

Keywords: complex root canal system, mandibular second premolar, root canal morphology, three separate canals

1. Introduction

The knowledge of the anatomy and morphology of the complex root canal system is necessary for successful treatment of endodontic diseases. Vertucci reported that the second premolars had only one root canal at the apex in 97.5% of the teeth and two canals were only found in 2.5% of cases. The incidence of three root canals was extremely rare [1,7,4]. The lower second premolars are described as teeth with single roots and single root canals [5,8,14]. The premolars can be the most challenging to treat the complex variations in their root canal system. The anatomy of the pulp chamber floor in premolars with three canals usually resembles the pulp floor in maxillary molars - one lingual and two buccal orifices at the same level [].

2. Case Report

A 52-year-old patient was referred to dental practice for treatment of a lower second premolar. His medical history was found to be non-contributory. The patient's chief complaint was pain in relation to his lower right teeth region. The tooth #45 was tender to vertical and horizontal percussion. Clinical evaluations revealed a deep carious lesion in the mandibular second premolar under the crown. Examination for swelling and sinus tract was negative. After removal of the crown the vitality test showed

no response to cold, heat and Electric pulp test (EPT). Preoperative radiograph evaluation revealed normal periradicular tissues and signs of complex root canal system (Fig.1A). The preoperative cone beam computed tomography (CBCT) was very helpful in root canal treatment procedure (Fig.2). Based on the clinical and radiographic evidences, it was diagnosed as irreversible pulpitis and a two-session endodontic treatment was planned. Isolation was achieved by rubber dam after local anesthesia with 2% Septanest (1:100 000 epinephrine). The preparation of the root canals was done under a surgical microscope (OPMI Pico Dental Microscope, Zeiss, Germany) at a magnification of x10. The three separate mesiobuccal, distobuccal and lingual orifices and canals with three separate apical foramina was mechano-chemically prepared. The three root canals were thoroughly instrumented to F1 (ProTaper Universal, Dentsply Maillefer, Switzerland) and treated consistent with 5.25 % NaOCl, 17% EDTA and 0.9% NaCl during root canal cleansing. The canals was obturated with single-cone technique and epoxy sealer (AH Plus, Dentsply, Germany). A control radiograph was then taken to confirm the accuracy of root canals obturation. It was clearly presented three separate apical foramina (portals of exit) (Fig.1B). This type of root canal system was classified as a type VIII by Vertucci's classification [18,19].

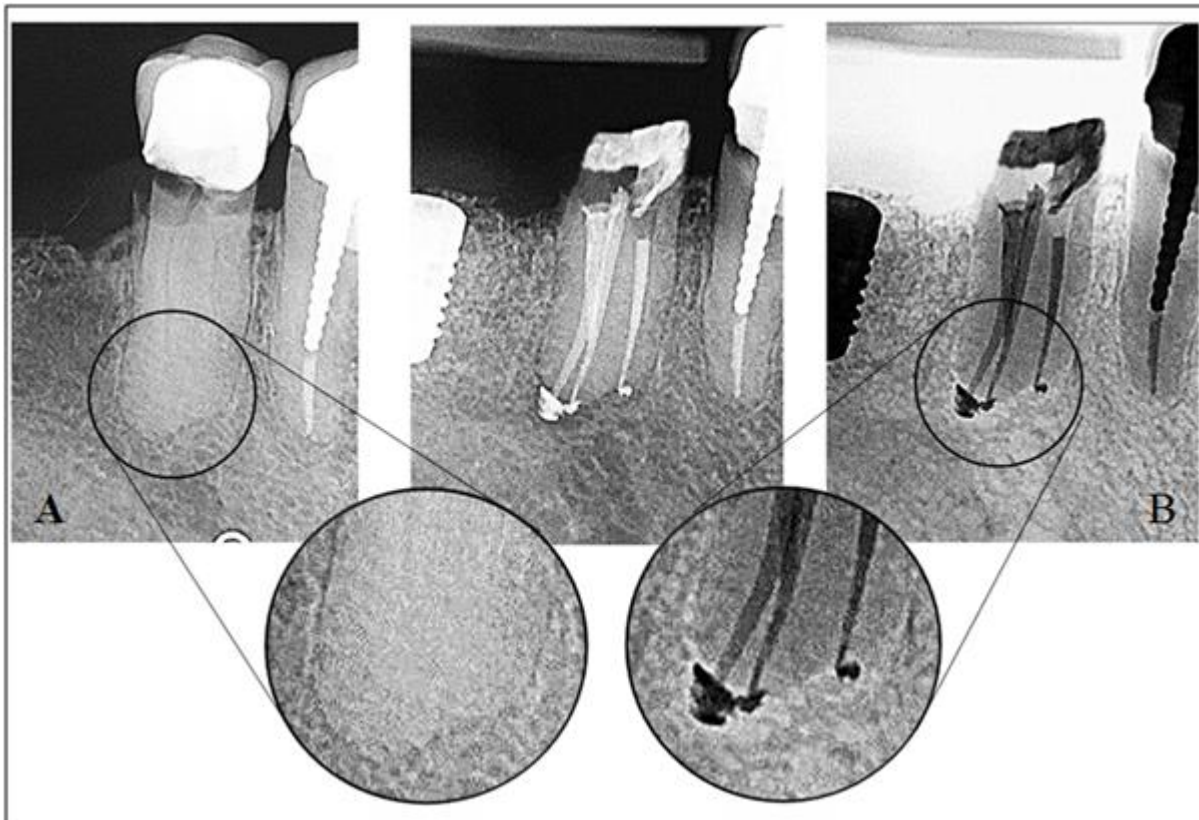


Figure 1. A/ Preoperative radiograph on tooth #45; B/ Control radiograph after definitive obturation with single-cone technique and AH Plus sealer. The three separate apical foramens (apical portals of exit) are clear visibly at zoom image

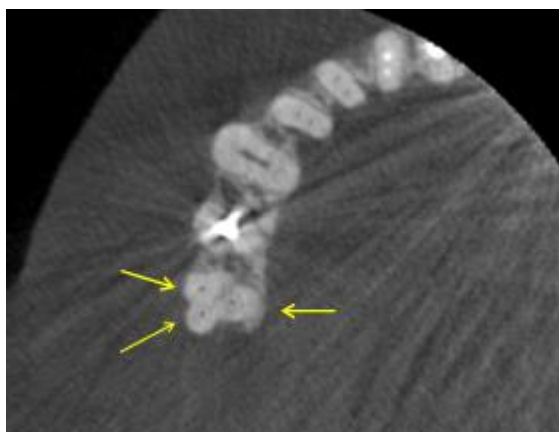


Figure 2: The CBCT image of mandibular right area; it is visualizing three canals in root of the second premolar (yellow arrow).

3. Discussion

The complex nature of root and root canal morphology of mandibular premolars has been studied for years, The root canal complexity is the unknown endodontic failures in many clinical cases[9,12,13]. Use of magnification with the help of a loupe or a microscope and visual enhancement with the use of fiber optics, use of sodium hypochlorite bubble technique and staining might be helpful in location of additional canals [2,16,17].The most of the previous studies have shown the presence of one orifice on the lingual aspect and two orifices on the buccal aspect[3, 10, 15]. But there are rare cases with atypical location of the canals - one orifice was on the lingual aspect, one canal orifice was on the buccal aspect, and the third orifice was

located mesial to the two other orifices[11].Incomplete cleaning andshaping of these complicated areas may leave tissue,bacteria, or necrotic debris in the canal.Failure to negotiate and properly treat these complicated cases may result finally in the loss of the tooth. In the present clinical case all the three canals could be found, negotiated and totally obturated[6]. The bifurcation of roots among lower premolars is usually positioned buccolingually, as in this case. Knowledge of variations in root canal system and accurate diagnosis with contemporary diagnostic tools like CBCT assist in thorough debridement and definitive three-dimensional obturation of the root canal system. This will increase the success rate of nonsurgical endodontic treatment, even in complex clinical cases.

4. Conclusion

This complex type of root canal system is difficult to negotiate because of a curvature and narrowing. The most of the canals in a tooth with three root canals can be located and instrumented using contemporary endodontic techniques.The accurate diagnosis and orientation with the root canal anatomy is mandatory for successful treatment.

References

- [1] Asgary S. Endodontic therapy in a three canal mandibular second premolar. Iran Endod J. 2006;1(1):43-4.
- [2] Carr G. Microscopes in endodontics. J Calif Dent Assoc 1992;20:55-61.

- [3] Chan K, Yew S, Chao S. Mandibular premolar with three root canals--two case reports. *Int Endod J.* 1992;25(5):261-4.
- [4] Cohen S, Burns R. *Pathways of the pulp.* 4. Mosby; 1998.
- [5] De Moor R, Calberson F. Root canal treatment in a mandibular second premolar with three root canals. *J Endod.* 2005;31(4):310-3.
- [6] Gulabivala K, Aung T, Alavi A, Ng Y. Root and canal morphology of Burmese mandibular molars. *Int Endod J.* 2001;34(5):359-70.
- [7] Honsy K, Abiad R. Mandibular second premolar with three root canals: a case report. *JLDA.* 2013;48(1)
- [8] Ingle J, Balkland L. *Endodontics.* New York: Elsevier; 2002.
- [9] Jafarzadeh H, Azarpazhooh A, Mayhall J. Taurodontism: a review of the condition and endodontic treatment challenges. *Int Endod J.* 2008;41(5):375-88.
- [10] Kamchan, Siu Chun. Mandibular premolars with three root canals – two case reports, *Int. Endod.* 1992; 25:261–264.
- [11] Lotfi M, Vosoughhosseini S, Zand V, Fatemi A, Shyezadeh V, Ranjkesh B. A mandibular second premolar with three canals and atypical orifices. *J Oral Sci.* 2008;50(3):363-6.
- [12] Martinez-Lozano M, Forner-Navarro L, Sanchez-Cortes JL. Analysis of radiologic factors in determining premolar root canal systems. *Oral Surg Oral Med Oral Pathol Oral Radiol Endod.* 1999;88(6):719-22.
- [13] Paul B, Dube K. Endodontic treatment of a mandibular second premolar with three roots and three canals. *Case Rep Dent.* 2014;2014:973410.
- [14] Peters O. Current challenges and concepts in the preparation of root canal systems: a review. *J Endod.* 2004;30(8):559-67.
- [15] Rodig T, Hulsmann M. Diagnosis and root canal treatment of a mandibular second premolar with three root canals. *Int Endod J.* 2003;36(12):912-9.
- [16] Saberi E, Rasooli H, Movassagh Z. Retreatment of a mandibular second premolar with three roots: a case report. *Iran Endod J.* 2014;9(2):158-60.
- [17] Shokouhinejad N. Root canal re-treatment of a mandibular second premolar with three root canals: a case report. *Aust Endod J.* 2009;35(3):180-2. 7. Ingle JI. *Ingle's endodontics* 6. USA: PMPH; 2008.
- [18] Vertucci F, Haddix J, Britto L. Tooth morphology and access cavity preparation. *Pathways Pulp.* 2006;9:148-232.
- [19] Vertucci F. Root canal morphology and its relationship to endodontic procedures. *Endodontic Topics.* 2005;10(1):3-29.
- [20] Zillich R, Dowson J. Root canal morphology of mandibular first and second premolars. *Oral Surg* 1973; 36:738.