

Histological Alterations in the Spleen of Gamma-Irradiated Mice Induced by *Adhatoda vasica* Leaf Extract

Sushma Sharma¹, Mahender Singh²

^{1,2}Department of Biosciences, H.P. University, Summer Hill, Shimla-171005; India

Abstract: Extract of *Adhatoda vasica* leaves has been used for treatment of various diseases and disorders in Ayurvedic and Unani medicine. Effect of ethanolic extract of *A.vasica* against gamma radiation induced changes in terms of histological alterations in spleen in Swiss albino mice was studied at post-irradiation intervals between 1 and 30 days. Mice exposed to 6 Gy gamma radiation showed radiation induced sickness including marked changes in histology of spleen. When ethanolic leaf extract of *A.vasica* was given orally at a dose of 900 mg/kg body weight prior to irradiation showed a significant protection. Mice were divided into four groups i.e. (i) control group (ii) mice given 900 mg/kg body wt. of *A.vasica* extract orally (iii) mice exposed to gamma radiation (6Gy) and (iv) *A.vasica* extract treated plus irradiated group. There was significantly lesser degree of damage to extract treated plus irradiated spleen. But there was higher degree of alterations in irradiated spleen architecture.

Keywords: *Adhatoda vasica*, gamma radiation, spleen and oral administration

1. Introduction

It is well known fact that the demand for herbal drug treatment of various ailments is increasing and plant drugs from the ayurvedic system are being explored more, not only in india but also globally. As a result, many research studies are being undertaken and there is need for an update and to put them together. Many more medicinally useful plants are present in Himalayas. Among them is *Adhatoda vasica* that belongs to family Acanthaceae. The leaves of plant are the main source of drug preparation. It has also been accredited to afford protection against allergen induced bronchial obstruction in guinea pigs [1]. The drug is employed in different forms such as fresh juice, infusion and powder. The Plants and their products are well known to have an advantage over the synthetic compounds in term of their potential low/no toxicity at the effective dose with minimum or no side effects [2]-[6].

The protection of biological systems from ionizing radiation is of paramount importance in planned as well as unplanned accidental exposures to radiation [7], [8] and development of novel and effective agents to combat radiation damages using nontoxic radioprotectors is of considerable interest in defence, nuclear industry and health care, particularly in radiodiagnostics and therapy. Many synthetic and as well as natural compounds have been investigated in recent past for their efficacy to protect the biological systems against the deleterious effects of radiations. They include plant extracts, antioxidants and other agents [9], [10]. Extracts of various plants have been reported to beneficial for free radical mediated conditions in humans, as they contain compounds having antioxidant activity which can prevent damage induced by reactive oxygen species(ROS) and reactive nitrogen species [11]. The spleen is a dark red to blue-black organ located in the left cranial abdomen. The functions of the spleen are centered on the systematic circulation. It is composed of two functionally and morphologically distinct compartments, the red pulp and the white pulp. The red pulp is a blood filter that remove foreign materials and damaged

erythrocytes. It is also a storage site for iron, erythrocytes and platelets. Spleen is also the largest secondary lymphoid organ containing about one-fourth of body's lymphocytes and initiates immune responses to blood borne antigens [12]-[14].

2. Materials and Methods

Swiss albino mice of Balb-C strain weighing 22-25g were procured from Central Research Institute (CRI) Kasauli, Himachal Pradesh, India. These were maintained in the animal house of Department of Biosciences of Himachal Pradesh University, Shimla under proper hygienic conditions (24±2 C temp. and light). Mice were provided Hindustan lever feed and water *ad libitum*. The entire animal care and experimental procedures were approved by the Institutional animal ethics committee of Himachal Pradesh University, Shimla (IAEC/Bio/12-2009).

Plant material

Leaves of *Adhatoda vasica* were collected from herbal garden Joginder Nagar, Himachal Pradesh, India.

Extraction of plant materials

Dried leaves powder was extracted five times with 80% ethanol solution. Extraction was done after every twenty four hours. Collected suspension was concentrated under reduced pressure.

Source of Irradiation

About 6-8 weeks old mice were irradiated in "Gamma chamber-900" (BARC) with automatic timer having cobalt-60 as the source of gamma rays.

Experimental design

Normal healthy animals showing no sign of morbidity were divided into following groups:

- Mice in first group serve as control.
- Mice of second group were administered *Adhatoda vasica* extract (900 mg/kg body wt.) for 15 days.

Volume 5 Issue 9, September 2016

www.ijsr.net

Licensed Under Creative Commons Attribution CC BY

- Mice of third group were exposed to gamma radiation (6Gy).
- Mice of fourth group were administered *Adhatoda vasica* extract (900 mg/kg body wt.) and then exposed to gamma radiation (6Gy).

Extract and Radiation Administration

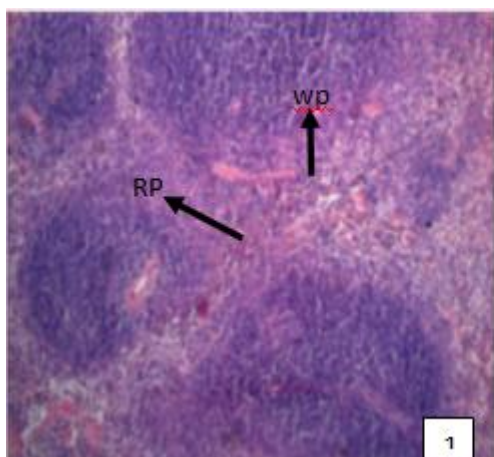
The mice were given *Adhatoda vasica* extract orally (900 mg/kg body wt.) for 15 days and after 30 min. of last dose; they were exposed to 6 Gy dose of gamma radiation. Following various treatments mice were autopsied by cervical dislocation on day 1,5, 15 and 30. The spleen of normal, treated and irradiated mice were excised and used for histological studies using Haematoxylin-eosin staining technique. The histological studies were intended to understand histopathological alternations induced by gamma irradiation and *Adhatoda vasica* extract. At least 8 animals were sacrificed at each stage. Sections of 4-6 μ thickness were used and slides mounted in DPX were stored permanently.

3. Results and Discussion

The results obtained for histopathological studies on spleen of mice were presented in figures 1-10 and discussed as follows:

Normal Spleen

The spleen is enclosed by a dense connective tissue capsule from which trabeculae extend deep into the interior of spleen. The transverse sections of normal spleen exhibited numerous round, long or irregular aggregation called white pulp floating in the red pulp with clear and prominent marginal area in between them (Fig. 1).



Adhatoda vasica extract treated spleen

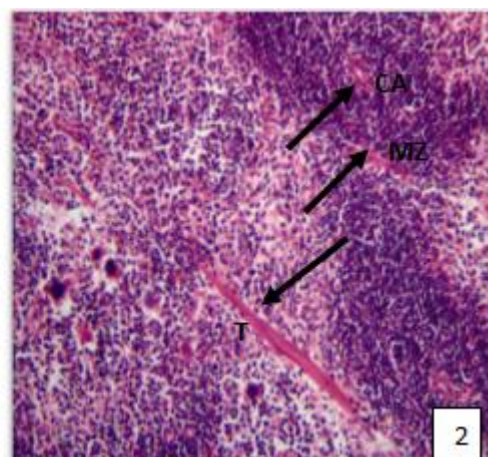
A significant protection in the spleen architecture was noticed after oral administration of *Adhatoda vasica* leaf extract. The lymphocytes extensively intermingled with RBC's at the periphery of white pulp [15]. *Adhatoda vasica* extract treated spleen showing central artery, trabeculae, blood vessel and lymphocytes (Fig. 2-4).

Irradiated spleen

The irradiated spleen show many visual changes in general anatomical architecture of spleen. The irradiated mice spleen exhibited reduction in cellularity of white pulp due to depletion of white pulp affecting mainly the B-cell region. This is in conformity with the findings of Seifert and Mark [16]. The decrease in hematological constituents may be due to a direct damage by radiation [17]. The irradiated spleen exhibiting disorganized splenic architecture, degenerative connective tissues and reduction in cellularity of white pulp (Fig. 5-7).

Adhatoda vasica extract plus irradiated spleen

Histological examination of *Adhatoda vasica* extract pretreated plus irradiated spleen exhibited recovery in spleen architecture. The effects of gamma rays are suppressed when *Adhatoda vasica* extract administered orally before irradiation. The degenerative lesions, reduction in lymphocytes number and irregular periarteriolar lymphatic sheath created by irradiation are recovered by *Adhatoda vasica* extract pretreatment. These findings are in conformity with the works of Bloom and Fawcett [18]. At 15 days stage *Adhatoda vasica* and irradiated spleen showed regain in distorted splenic architecture (Fig. 10).



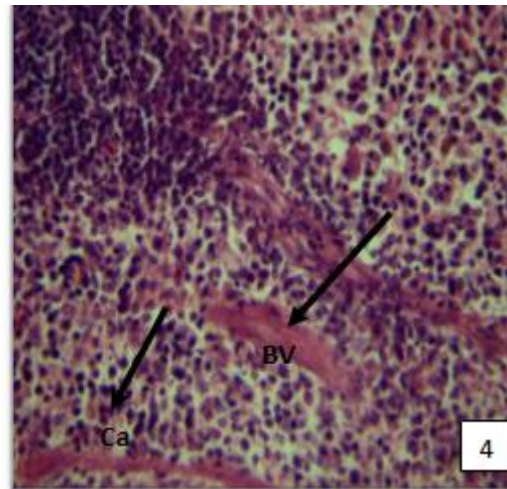
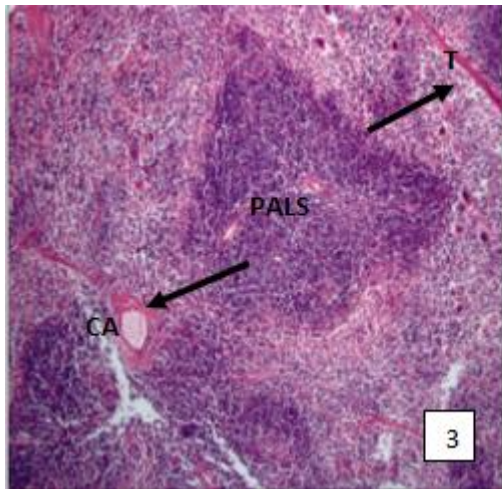


Figure 1: T.S. of normal mice spleen showing numerous irregular or rounded aggregation called white pulp (WP) floating in the red pulp (RP). Majority of lymphocytes are organized forming a well defined anatomical architecture termed as PALS.

Figure 3: T.S. of *Adhatoda vasica* extract treated mice spleen at 5 days stage showing trabeculae (T), trabecular artery (TA) and PALS.

Figure 2: T.S. of *Adhatoda vasica* extract treated mice spleen at 1 day stage exhibiting central artery (CA) and marginal zone (MZ).

Figure 4: T.S. of *Adhatoda vasica* extract treated mice spleen at 15 days stage exhibiting blood vessel (BV), capsule (Ca) and lymphocytes(L).

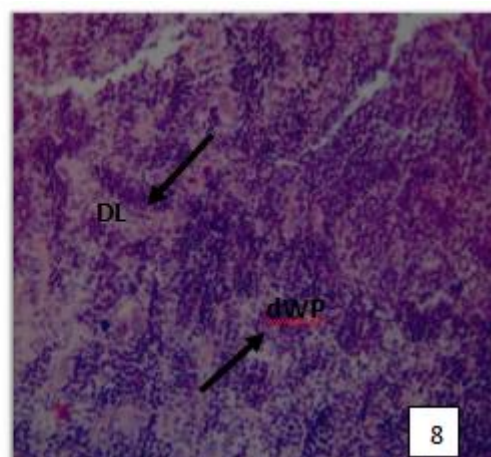
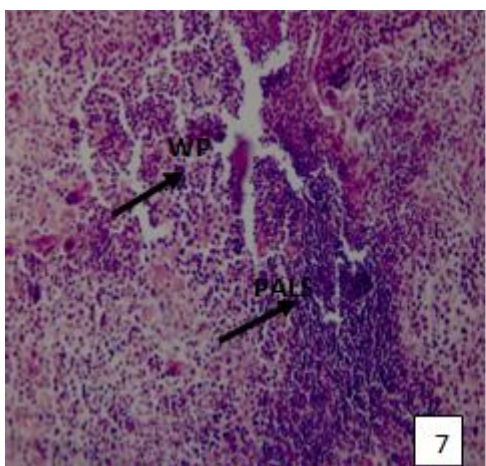
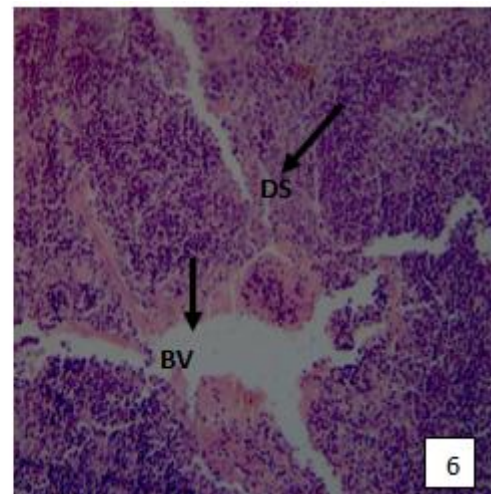
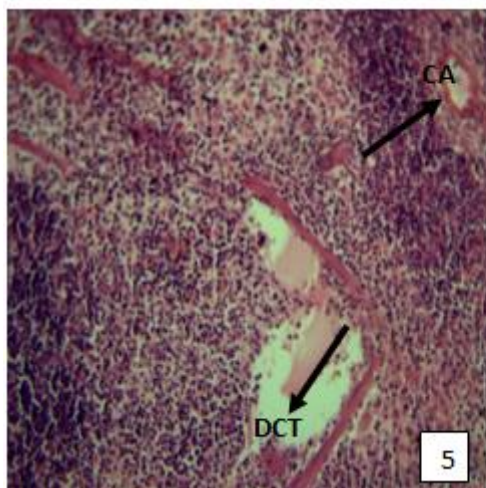


Figure 5: T.S. of irradiated mice spleen at 1 day stage demonstrating swollen central artery (CA) and degenerating connective tissues (DCT).

Figure 6: T.S. of irradiated mice spleen at 5 days stage showing breaking of blood vessel (BV) and disorganized splenic (DS) architecture.

Figure 7: T.S. of irradiated mice spleen at 15 days stage exhibiting breaking of periarterial lymphatic sheath (PALS) and reduction in cellularity of white pulp (WP).

Figure 8: T.S. of *Adhatoda vasica* extract plus irradiated mice spleen at 1 day stage demonstrating degenerative lesions (DL) and distorted white pulp (dWP).

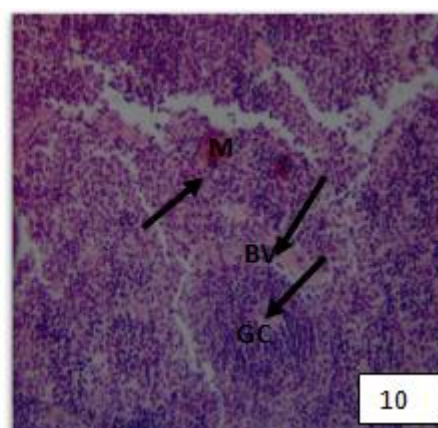
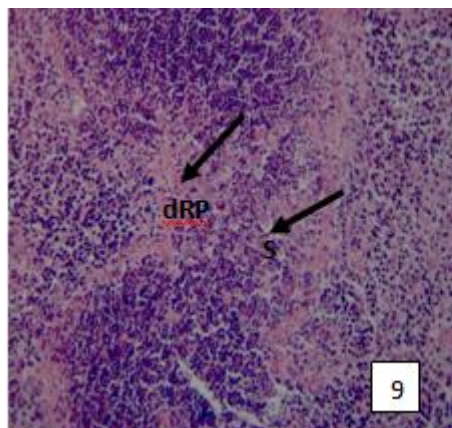


Figure 9: T.S. of *Adhatoda vasica* extract plus irradiated mice spleen at 5 days stage exhibiting disorganized red pulp (dRP) and sinuses (S).

Figure 10: T.S. of *Adhatoda vasica* extract plus irradiated mice spleen at 15 days stage showing germinal centre (GC) and blood vessel (BV).

References

- [1] Dorsch, W. and Wagner, H., (1991). New antiasthmatic drugs from traditional medicine? *Int. Arch. Allergy Appl. Immunol.* 94: 262-265.
- [2] Ammon, H.P. and Wahl, M.A. (1991). Pharmacology of *Curcuma longa*. *Planta Medica* 57: 1-7.
- [3] Scarterzzimi, P. and Speroni, E. (2000). Review of some plants of Indian traditional medicine with antioxidant activity. *J. Ethnopharmacol.* 71: 23-43.
- [4] Weiss, J.F. and Landauer, M.R. (2003). Protection against ionizing radiation by antioxidant nutrients and phyto-chemicals. *Toxicol.* 189: 1-20.
- [5] Coleman, C.N., Stone, H.B. Moulder, J.E. and Pellmar, T.C. (2004). Modulation of radiation injury. *Science* 304: 693-694.
- [6] Sarkar, F.H. and Li, Y. (2004). The role of isoflavones in cancer chemo-prevention. *Front. Biosci.* 9: 2714-2724.
- [7] Arora, R., Gupta, D., Chawla, R., Sagar, R., Sharma, A., Kumar, R., Prasad, J., Singh, S., Samanta, N. and Sharma, R.K. (2005). Radioprotection by plant products: Present status and future prospects. *Phytother. Res.* 19: 1-22
- [8] Jagetia, G.C. (2007). Radioprotection by plant products: Present status and future prospects. *J. Clin. Biochem. Nutr.* 40: 78-81.
- [9] Maisin, J.R. (1998). Radioprotection by plant products: past, present and future prospects. *Int. J. Radiat. Biol.* 73: 443-450.
- [10] Nair, C.K., Parida, D.K., Nomura, T. (2001). Radioprotectors in radiotherapy. *J. Radiat. Res.* 42: 21-37.
- [11] Arora, R., Chawla, R., Singh, S. (2006). Bioprospection for radioprotective molecules. *Phytother. Res.* 16: 179-219.
- [12] Kuper, D.F., de Heer, E., Van Loveren, H. and VOS, J.G. (2002). In: *Handbook of Toxicologic Pathology, Immune System* (Eds. W.M. Haschek, C.G. Rousseaux and M.A. Walling) Academic Press, San Diego, 2: 585-646.
- [13] Notle, M.A., Hamann, A., Kraal, G. and Mebnis, R.E. (2002). The strict regulation of lymphocyte migration to splenic white pulp does not involve common homing receptors. *Immunol.* 106: 299-307.
- [14] Balogh, P., Horvath, G. and Szakal, A.K. (2004). Immunoarchitecture of distinct reticular fibroblastic domains in the white pulp of mouse spleen. *J. Histochem. Cytochem.* 52: 1287-98.
- [15] Suttie, A.W. (2006). Histopathology of the spleen. *Toxicol. Pathol.* 34: 466-503.
- [16] Seifert, M.F. and Marks, S.C. (1985). The regulation of hemopoiesis in the spleen. *Experientia* 41: 192-199.
- [17] Samarth, R.M., Goyal, P.K. and Kumar, A., 2001. Radioprotective effects of mentha piperita. *J. Med. Aromat. Plant Sci.* 22/23: 91-97.
- [18] Bloom, W. and Fawcett, D.W. (1968). A test book of histology. WB Saunder and Co., Philadelphia.